

**MICHAEL PHILLIPS, MD\***

Department of Diagnostic Radiology  
Cleveland Clinic  
Cleveland, OH

## Brain imaging in cardiovascular disease: State of the art

**N**euroimaging can be used to directly monitor the heart-brain interaction. Disruptions of the normal heart-brain interaction are common. Abnormalities can originate with cardiac or cardiovascular processes that have neurologic effects, such as embolic stroke and low perfusion states, or with neurologic processes that have direct cardiac effects, such as focal brain lesions caused by stroke or multiple sclerosis (MS).

Brain imaging techniques have advanced to the point where regions involved in changes in autonomic arousal during behavior can be located with precision. These regions can be localized by identifying lost function from specific lesions or by using functional brain imaging, such as positron emission tomography (PET) or magnetic resonance imaging (MRI). This article describes imaging of heart-brain interactions, focusing on functional imaging techniques that have enhanced our understanding of these interactions.

### ■ CARDIOVASCULAR DISEASE PRODUCING NEUROLOGIC DISEASE

#### Acute embolic stroke

At most institutions, computed tomography (CT) with perfusion is the imaging modality of choice in patients with acute embolic stroke because it is fast and readily available. CT techniques are limited by a lack of whole brain coverage. It could be argued that acute embolic stroke is best evaluated using MRI, which provides brain coverage and combines diffusion/perfusion imaging for a better assessment of brain at risk for infarction. Disadvantages of MRI, however, are its unfriendly (enclosed) environment for patients and the length of time required to obtain images. Several excellent reviews of the relative merits of CT and MRI for evaluation of acute stroke are available in the literature.<sup>1-3</sup>

Detecting diffusion/perfusion mismatch early is

critical for institution of rapid therapy, as 1.9 million neurons are lost per minute during a middle cerebral artery stroke.<sup>4</sup>

### ■ NEUROLOGIC PROCESSES WITH CARDIAC EFFECTS

Neurologic processes have cardiac effects; this phenomenon has been reported extensively in the literature.<sup>1-3, 5-8</sup> Injury to the autonomic nervous system can occur with infarcts or MS lesions in specific regions of the brain. The brainstem, insular cortex, and anterior cingulate are the primary regions that have been described in this phenomenon.<sup>9</sup> Injury to the insular cortex, in particular, is associated with an increased incidence of heart rate variability and alterations in cardiac rhythm, placing patients at higher risk of sudden death.<sup>10-12</sup> Focal lesions produced by neurologic disease processes can be used to map autonomic function within the brain.

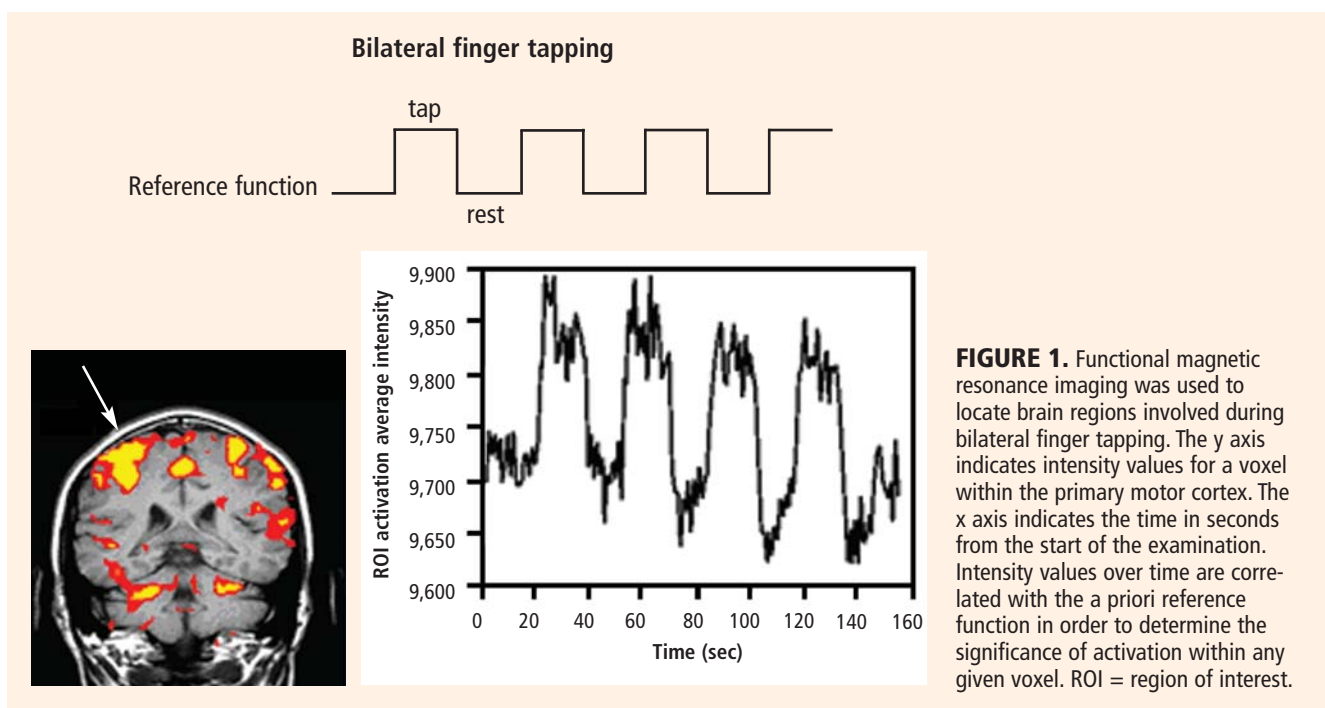
#### 'Dysfunctional' imaging

Focal brain lesions result in specific functional loss. "Dysfunctional" imaging is the process of matching anatomic locations to specific functional loss. The advantages of dysfunctional imaging are that it requires little or no specialized imaging equipment and produces relatively good localization of functions.

Dysfunctional imaging has several important disadvantages. There is no control over the location of lesions in the brain, making a systematic evaluation of function difficult. Often, lesions will overlap several brain regions or multiple lesions will be present, making it difficult to map a single lesion to a single brain region. Most important, this technique does not allow for the study of normal subjects, either for understanding the normal heart-brain interaction or for developing potential screening tests for abnormal autonomic function.

Despite these shortcomings, dysfunctional imaging has provided a tremendous amount of data on autonomic brain function, and it specifically has provided a better understanding of cardiac abnormalities resulting from stroke and MS.

\* Dr. Phillips reported that he has no financial relationships that pose a potential conflict of interest with this article.



**FIGURE 1.** Functional magnetic resonance imaging was used to locate brain regions involved during bilateral finger tapping. The y axis indicates intensity values for a voxel within the primary motor cortex. The x axis indicates the time in seconds from the start of the examination. Intensity values over time are correlated with the a priori reference function in order to determine the significance of activation within any given voxel. ROI = region of interest.

**Stroke.** For instance, we have learned from dysfunctional imaging that right-sided middle cerebral artery/right insular strokes are associated with an increased incidence of arrhythmias, cardiac death, and catecholamine production.<sup>10-12</sup> Left insular strokes have been implicated in these processes as well.<sup>13</sup> Brainstem (medullary) strokes can also produce significant autonomic dysfunction.<sup>14-16</sup>

**MS.** Autonomic dysfunction has also been reported in as many as 45% to 50% of patients with MS.<sup>5-8</sup> Orthostatic intolerance is also reported commonly.<sup>8</sup> In MS, cardiac autonomic dysfunction may be linked to lesions in the brainstem and medulla. The variability and quantity of brain lesions in patients with MS, however, underscore the difficulties involved in using dysfunctional imaging to identify specific culprit lesions.

### Functional brain imaging

Functional brain imaging can directly visualize brain control of autonomic function and can thus overcome the limitations of dysfunctional imaging.<sup>17</sup> Functional brain imaging can be accomplished with either PET or functional MRI. The latter has superior spatial and temporal resolutions compared with PET, allowing visualization of small objects over a smaller timeframe. The disadvantage to functional MRI is that it is not a quantitative but a qualitative methodology.

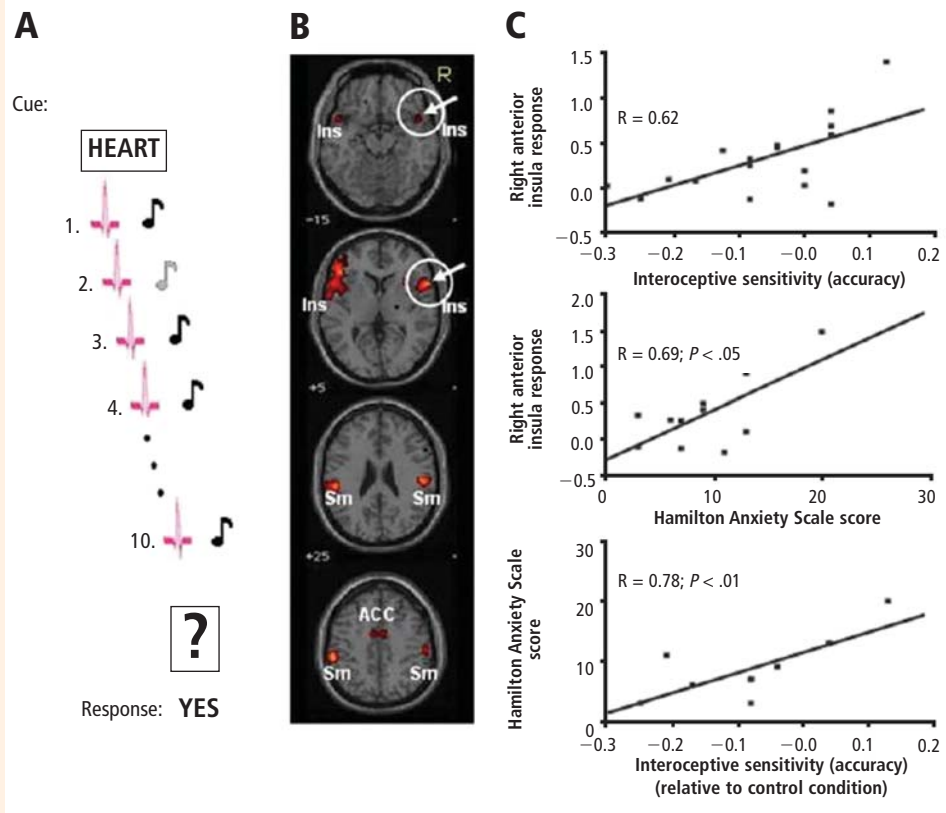
**Functional MRI brain activation.** Increased neuronal activity increases local cerebral blood flow, which decreases the amount of deoxyhemoglobin and magnetic susceptibility, resulting in a net enhancement of the MRI signal.<sup>18-20</sup> For this enhancement to

occur, blood flow must be adequate, neuronal activity must be coupled with blood flow, and oxygen extraction must be relatively stable.

Functional MRI can be used to locate brain regions involved in simple tasks. Bilateral finger tapping with periods of rest in between has been used to locate brain pixels that demonstrate a similar pattern of activity, permitting mapping of the brain regions involved (Figure 1).

**Challenges in autonomic functional MRI.** One challenge posed by autonomic functional MRI is that untrained individuals have little or no volitional control over autonomic functions. Therefore, the tasks chosen must elicit autonomic responses. In the case of sympathetic arousal, example stimuli would include maximal handgrip, pain, fear, anticipation, and anxiety. An example of a parasympathetic stimulus would be a Valsalva maneuver. The response to stimuli must then be monitored to compare the data obtained from functional MRI. This presents a problem, as the MRI scanner is a relatively unfriendly environment for most of the standard monitoring equipment used to evaluate autonomic responses. Until recently this required special modification of existing equipment. Fortunately, MRI-compatible equipment for measuring heart rate, blood pressure, galvanic skin response, and pupillary response is now becoming available.

**Obtaining the desired signal.** The most difficult task in functional imaging of the autonomic system is to carefully design stimuli and tasks to isolate autonomic effects. A good example from the literature is a paper by Cheng et al that assessed activity in the amygdala with anticipation of pain (Pavlovian fear condition-



**FIGURE 2.** Interoceptive awareness was assessed in healthy subjects who performed a heartbeat detection task. Subjects were first exposed to a series of tones either synchronized to their heartbeat or delayed by 500 msec (A). While attending to heartbeat timing, activity was enhanced in the bilateral insula, bilateral somatomotor cortex, and anterior cingulate (B). Conscious awareness of the timing of the heartbeats (interoceptive awareness) was associated with activity in the right insular cortex, and scores indicative of anxiety on the Hamilton Anxiety Scale correlated with interoceptive sensitivity (C). Reprinted, with permission, from reference 17.

ing).<sup>21</sup> The researchers exposed 20 healthy subjects to an unconditional stimulus in the form of an electric shock. Subjects were also exposed to a visual stimulus (conditional stimulus) in the form of a flashing light. When the functional MRI time series data were analyzed using the visual stimulus as a reference function, the primary activated areas were in the occipital cortex. However, a very different pattern of activation was identified using a reference function that is sensitive to autonomic changes. The reference function from the galvanic skin response during experiments demonstrated the desired activation within the amygdala that was indicative of an autonomic response.

**Anterior cingulate.** Functional neuroimaging with PET and MRI has also been used to study autonomic activation of the anterior cingulate during a variety of tasks. Critchley and colleagues have used a variety of methods to measure autonomic function, including blood pressure, cardiac sympathetic response, heart rate, and change in pupil diameter.<sup>17</sup> Across the multiple tasks designed to elicit an autonomic response, consistent activation in the anterior cingulate was observed. Further, this relatively consistent response was seen using a variety of methods to determine autonomic response. The findings suggest a central role for the anterior cingulate in autonomic functioning. Critchley also points out that the anterior cingu-

late is involved in almost all concentration tasks, which may be partially related to autonomic function or to the anterior cingulate being a central processing area for volitional behaviors.<sup>17</sup>

**Right insular cortex.** Another functional imaging study designed to map autonomic control centers involves correlating changes in galvanic skin response to performance of a gambling task.<sup>17</sup> Skin conductance was measured as subjects attempted to choose a “winning” playing card among two cards presented. Unbeknownst to the subjects, the winning card in this task was chosen randomly, provoking anxiety as subjects attempted without success to develop a decision-making strategy to win. Comparing the functional MRI time series data with the galvanic skin response as a reference function produced a consistent pattern of activation in the right insular cortex. Activation was also observed in medial frontal regions and some parietal regions of the brain as well.

In a study designed to test autonomic interoceptive awareness, Critchley et al tested the ability of subjects to detect their own heart rate (**Figure 2**).<sup>17,22</sup> In the study, subjects underwent functional MRI scans while they were asked to judge the timing of their own heartbeats to auditory tones that were either synchronized with their heartbeat or delayed by 500 msec. At the

end of 10 heartbeats, the subjects were asked whether the tone matched or did not match their heartbeats. Areas of activation during the task were observed in the right insular cortex, the anterior cingulate, the parietal lobes, and the operculum. However, when activation was compared with subjects' accuracy in detecting their own heart rate, only the right insular cortex showed a significant correlation with conscious perception of heartbeats. Interestingly, the degree of activation in the insular cortex correlated with subjects' perceived anxiety in daily life as assessed by scores on the Hamilton Anxiety Scale. Subjects who reported more anxiety were also more accurate at detecting their own heart rate (interoceptive sensitivity). These findings suggest that interoceptive sensitivity is mediated by the right insular cortex and that sensitivity to autonomic states may play a role in anxiety.

*Imaging autonomic brainstem nuclei.* Many of the brain regions responsible for autonomic responses lie within the brainstem and are relatively small. Recently, investigators have demonstrated that functional MRI can detect brainstem nuclei as small as 2 mm.<sup>23</sup> Although the studies have been performed largely in normal subjects, they hold the promise that the entire autonomic nervous system can be evaluated, including small brainstem nuclei.<sup>23</sup>

**■ IMAGING IN DISEASE STATES**

Few functional brain imaging studies have been performed in patients with disease. In a study comparing activation of brain regions in patients with heart failure and controls upon performance of a cold pressor task, activation in the medulla, the hypothalamus, and portions of the insular cortex was observed in the patients with heart failure but not in the controls.<sup>24</sup>

Functional MRI is an excellent tool for *in vivo* evaluation of normal subjects. It is also potentially useful for disease states, with several caveats. It is difficult to perform on sick patients because of the unfriendly MRI environment and because extensive physiologic monitoring is required. In addition, the autonomic response may be blunted, making physiologic comparisons and monitoring more difficult. Finally, blood flow and neurovascular coupling may be impaired in disease states.

**■ CONCLUSION**

Excellent methods are available for assessing brain injury from cardiac causes. Anatomic imaging can be used to relate neurologic injury to cardiac effects. The potential of functional brain imaging for *in vivo* testing of autonomic function is strong, and may provide a better understanding of disease states.

**■ REFERENCES**

1. Rowley HA. Extending the time window for thrombolysis: evidence from acute stroke trials. *Neuroimaging Clin N Am* 2005; 15:575–587.
2. Latchaw RE. Cerebral perfusion imaging in acute stroke. *J Vasc Interv Radiol* 2004; 15:S29–S46.
3. Sunshine JL. CT, MR imaging, and MR angiography in the evaluation of patients with acute stroke. *J Vasc Interv Radiol* 2004; 15:S47–S55.
4. Saver JL. Time is brain—quantified. *Stroke* 2006; 37:263–266.
5. Haensch CA, Jorg J. Autonomic dysfunction in multiple sclerosis. *J Neurol* 2006; 253(Suppl 1):I3–I9.
6. Merkelbach S, Haensch C-A, Hemmer B, Koehler J, König NH, Ziemssen T. Multiple sclerosis and the autonomic nervous system. *J Neurol* 2006; 253(Suppl 1):I21–I25.
7. Kodounis A, Stamboulis E, Constantinidis TS, Liolios A. Measurement of autonomic dysregulation in multiple sclerosis. *Acta Neurol Scand* 2005; 112:403–408.
8. Flachenecker P, Wolf A, Krauser M, Hartung HP, Reiners K. Cardiovascular autonomic dysfunction in multiple sclerosis: correlation with orthostatic intolerance. *J Neurol* 1999; 246:578–586.
9. Lassman AB, Mayer SA. Paroxysmal apnea and vasomotor instability following medullary infarction. *Arch Neurol* 2005; 62:1286–1288.
10. Abboud H, Berroir S, Labreuche J, Orjuele K, Amarenco O. Insular involvement in brain infarction increases risk for cardiac arrhythmia and death. *Ann Neurol* 2006; 59:691–699.
11. Tokgozoglul SL, Batur MK, Topcuoglu MA, Saribas O, Kes S, Oto A. Effects of stroke localization on cardiac autonomic balance and sudden death. *Stroke* 1999; 30:1301–1311.
12. Strittmatter M, Meyer S, Fischer C, Georg T, Schmitz B. Location-dependent patterns in cardio-autonomic dysfunction in ischaemic stroke. *Eur Neurol* 2003; 50:30–38.
13. Laowattana S, Zegler SL, Lima JA, Goodman SN, Wittstein IS, Oppenheimer SM. Left insular stroke is associated with adverse cardiac outcome. *Neurology* 2006; 66:477–483.
14. Kihara M, Nishikawa S, Nakasaka Y, Tanaka H, Takahashi M. Autonomic consequences of brainstem infarction. *Auton Neurosci* 2001; 86:202–207.
15. Korpelainen JT, Huikuri HV, Sotaniemi KA, Myllyla VV. Abnormal heart rate variability reflecting autonomic dysfunction in brainstem infarction. *Acta Neurol Scand* 1996; 94:337–342.
16. Monge Argiles JA, Palacios Ortega F, Vila Sobrino JA, et al. Brainstem lesions decrease heart rate variability. *Neurologia* 2000; 15:158–163.
17. Critchley HD. Neural mechanisms of autonomic, affective, and cognitive integration. *J Comp Neurol* 2005; 493:154–166.
18. Bandettini PA, Wong EC, Hinks RS, Tikofsky RS, Hyde JS. Time course EPI of human brain function during task activation. *Magn Reson Med* 1992; 25:390–397.
19. Kwong KK, Belliveau JW, Chesler DA, et al. Dynamic magnetic resonance imaging of human brain activity during primary sensory stimulation. *Proc Natl Acad Sci U S A* 1992; 89:5675–5679.
20. Ogawa S, Tank DW, Menon R, et al. Intrinsic signal changes accompanying sensory stimulation: functional brain mapping with magnetic resonance imaging. *Proc Natl Acad Sci U S A* 1992; 89:5951–5955.
21. Cheng DT, Knight DC, Smith CN, et al. Functional MRI of human amygdala activity during Pavlovian fear conditioning: stimulus processing versus response expression. *Behav Neurosci* 2003; 117:3–10.
22. Critchley HD. The human cortex responds to an interoceptive challenge. *Proc Natl Acad Sci USA* 2004; 101:6333–6334.
23. Topolovec JC, Gati JS, Menon RS, Shoemaker JK, Cechetto DF. Human cardiovascular and gustatory brainstem sites observed by functional magnetic resonance imaging. *J Comp Neurol* 2004; 471:446–461.
24. Woo MA, Macey PM, Keens PJ, et al. Functional abnormalities in brain areas that mediate autonomic nervous system control in advanced heart failure. *J Card Fail* 2005; 11:437–446.

**Address:** Michael Phillips, MD, Department of Diagnostic Radiology, Cleveland Clinic, 9500 Euclid Avenue, U15, Cleveland, OH 44195; phillim@ccf.org.