

RISAL DJOHAN, MD
Department of Plastic Surgery,
Cleveland Clinic, Cleveland, OH

EARL GAGE, MD
Department of Plastic Surgery,
Cleveland Clinic, Cleveland, OH

STEVEN BERNARD, MD
Department of Plastic Surgery,
Cleveland Clinic, Cleveland, OH

Breast reconstruction options following mastectomy

■ ABSTRACT

Breast reconstruction can help to address the disfigurement and sense of loss that often follow mastectomy. The decision whether to pursue reconstruction and the choice of reconstructive strategy are individualized decisions that must take into account the patient's body characteristics, overall health, breast cancer treatment plan, and personal preferences. Options for reconstruction broadly include placement of breast implants or use of the patient's own tissue (autologous reconstruction). Both saline-filled and silicone gel-filled implants are safe and effective options for implant-based reconstruction. Autologous reconstruction usually involves transfer of tissue from the abdomen, with recent advances allowing preservation of the abdominal muscles. Both implant-based and autologous procedures have advantages and drawbacks, and both types of reconstruction may be compromised by subsequent radiation therapy. For this and other reasons, consultation with a plastic surgeon early in treatment planning is important for women considering postmastectomy reconstruction.

Patients recently diagnosed with breast cancer are distraught with concerns not only about surviving their disease but also about how its treatment will affect their body image and self-image. Although the risk of breast cancer increases with age, it is not a disease limited to the elderly. With advances in screening and awareness, breast cancers are now detected at earlier stages and in younger women. Approximately 5% of breast cancer patients are age 40 years or younger, which explains the recommendation that women be told about the benefits (and limits) of regular breast self-examinations beginning in their 20s.¹ Additionally, breast cancer is the most com-

mon cancer in pregnant and postpartum women, occurring in about 1 in 3,000 pregnant women.² Although breast conservation therapy is an attractive option, for many patients mastectomy is still the recommended surgical treatment. When mastectomy is required, it is understandable that many women are very concerned about losing their breast.

■ REASONS FOR RECONSTRUCTION

Mastectomies are commonly performed for women with ductal carcinoma in situ or with early or locally advanced invasive breast cancer (infiltrating ductal carcinoma) and sometimes for recurrent disease or for prophylaxis in high-risk women such as those with *BRCA* gene mutations or lobular carcinoma in situ. As reviewed in the preceding article in this supplement, mastectomy can be performed in various ways, using modified radical, skin-sparing, or nipple-sparing mastectomy techniques.

An emotional 'double hit'

Following mastectomy, women are often left with what may be regarded as an emotional "double hit." First, of course, is the anxiety from having a cancer diagnosis. Second, and perhaps equally devastating for some, is the emotional impact of losing a breast and the accompanying perception of disfigurement or loss of femininity and sexuality. These latter feelings often lead women who have undergone or will undergo mastectomy to explore the possibility of breast reconstruction.³⁻⁵

Both a medical and an emotional decision

While the reasons that women may seek breast reconstruction are many and varied (eg, to restore their self-esteem and social functioning, to help put their cancer experience behind them), it is important for primary care providers and other referring physicians to recognize that this decision is both a medical and an emotional one. Most women healthy enough to undergo extirpative surgical procedures are, in fact, healthy enough to undergo breast reconstruction if

Dr. Djohan reported that he has received a consulting/advisory fee from Allergan, Inc. Drs. Gage and Bernard reported that they have no commercial affiliations or financial interests that pose a potential conflict of interest with this article.

desired. Since choosing a reconstructive strategy is a complex process that takes into account many therapeutic and individual patient factors, plastic surgery consultation plays a major role in the comprehensive treatment of breast cancer.

■ TIMING AND TYPE OF RECONSTRUCTION

The timing of breast reconstruction can vary. In cases where the patient knows she will want reconstruction and the cancer surgery is performed at a site where a reconstructive surgery team is available, reconstruction can be performed immediately following mastectomy during a single trip to the operating room. When a reconstructive surgeon is not available locally or when systemic or local cancer therapies need to be completed first, reconstruction may need to be delayed.

Immediate reconstruction has the advantage of improved aesthetics while mitigating the sense of loss that can accompany mastectomy. Delayed reconstruction will give the patient more time for her decisions. An additional option, called “delayed-immediate” reconstruction, involves placing a tissue expander at the time of mastectomy (to preserve the breast skin envelope) and awaiting pathology results to determine whether radiation therapy is needed. If radiation is not needed, the patient undergoes reconstruction right away; if radiation is needed, the patient undergoes delayed reconstruction after radiation therapy is completed, with the breast skin envelope preserved for better aesthetic results. (The timing of reconstruction and these various timing options are discussed in detail in the final article in this supplement.) Selecting the correct timing and method of reconstruction requires good communication and coordination between the patient, her oncologist, and her multidisciplinary surgical team comprising both breast and plastic surgery specialists.

The patient and her surgeon will also discuss which reconstructive technique is best for her. Choosing a reconstructive strategy is a highly individualized process that takes into account the patient’s body characteristics, overall health, breast cancer treatment plan, and personal preferences. Consequently, a strategy offered to one patient is not necessarily valid for another. In general, options for reconstruction include use of the patient’s own tissue (autologous tissue), use of implant material (nonautologous), or a combination of an implant and autologous tissue.

■ IMPLANT-BASED RECONSTRUCTION

What the procedure involves

Nonautologous breast reconstruction usually involves a two-step procedure: placement of a tissue expander

followed by later placement of a permanent implant.

At the time of mastectomy, a tissue expander type of implant is placed under the pectoralis major muscle, the main muscle under the breast. The tissue expander is then inflated at weekly intervals by percutaneous injection of saline solution, allowing expansion of the tissues over the expander, including the muscle and breast skin. These injections are administered in an outpatient clinic beginning about 2 to 3 weeks after expander placement. Once the expander is filled to the desired volume and the tissue has been expanded sufficiently, which typically takes 3 to 6 months, a second procedure is performed to remove the expander and place a permanent implant. This latter procedure is done through the previous scars and usually is much less involved than the first operation. **Figure 1** illustrates the various stages of expander placement and inflation.

Choice of permanent implant

Permanent implants vary by shape, texture of the implant shell, and filler material. They are typically filled with either silicone gel or saline.

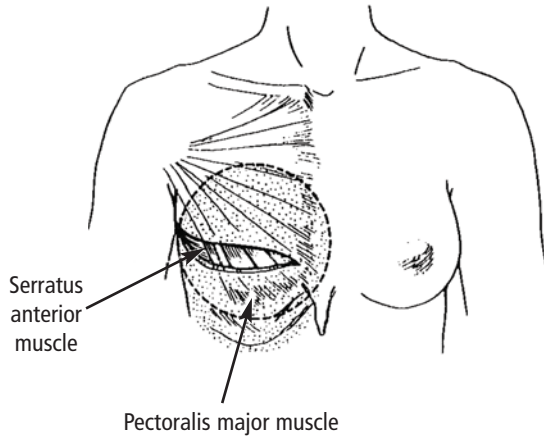
Breast implants have been available for many years for use in both reconstructive breast surgery and cosmetic augmentation. A great deal of bad press and misinformation had surrounded the use of silicone gel-filled implants, with the result that they ceased to be marketed in the United States beginning in the early 1990s while the US Food and Drug Administration (FDA) reviewed additional safety information on their use. During this period when the use of silicone implants was limited, saline-filled implants became the preferred choice until the FDA approved the reintroduction of silicone implants to the market in November 2006, after what the agency described as years of rigorous scientific review of multiple clinical studies and other data.⁶ The FDA concluded that silicone implants are safe and effective for general use in breast reconstruction, correction of congenital breast anomalies, and breast augmentation.⁶ There is no evidence that silicone implants pose a significant systemic risk to women undergoing breast reconstruction.

The silicone implant offers a softer, more natural feel to the reconstructed breast than the saline implant. As a result, increasing numbers of women are opting for silicone implants (**Figures 2, 3**). However, saline implants remain a sound, proven alternative for women who are not comfortable with receiving a silicone implant.

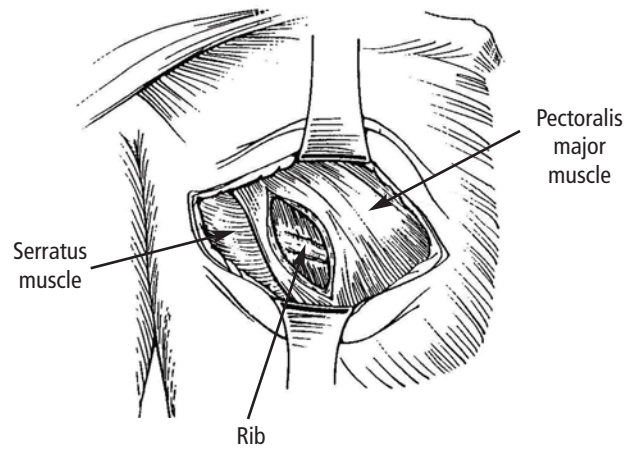
Potential complications

Implant extrusion. One of the potential complications of implant-based reconstruction is extrusion of the tissue expander or implant through the skin. If

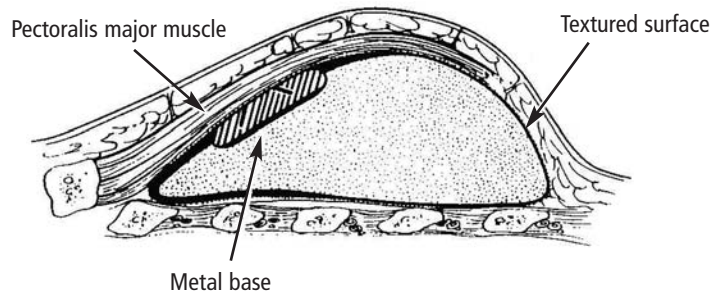
Preparation for expander placement



Pocket preparation for expander placement



Anatomic position of expander



Expansion of tissue with inflations over a period of 3 to 6 months

Differential expansion

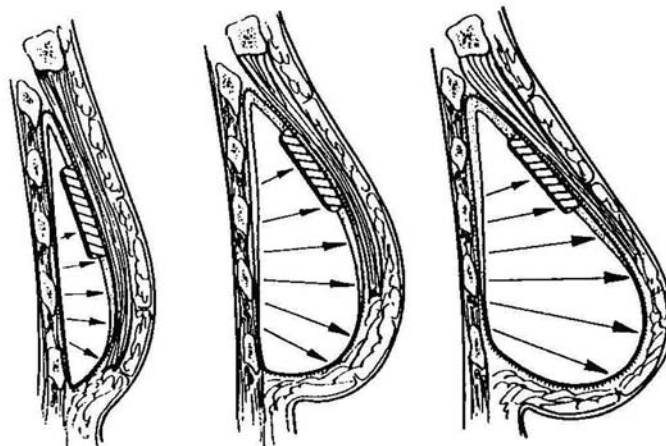


FIGURE 1. The process of expander placement and inflation in preparation for implant-based reconstruction.

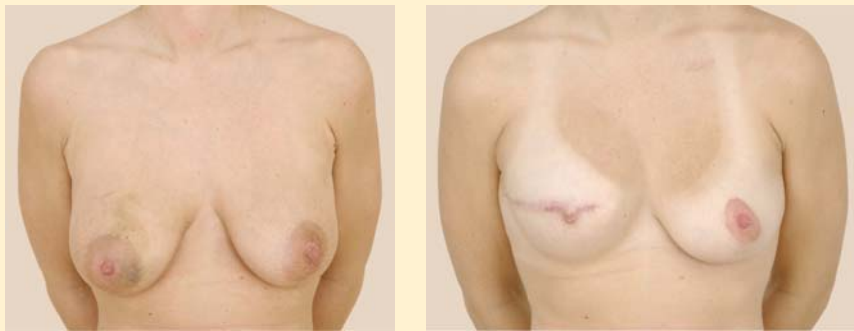

FIGURE 2. Preoperative (left) and postoperative (right) photos of a patient who underwent mastectomy of the right breast followed by silicone implant placement and nipple reconstruction. She had matching vertical mastopexy of the left breast. The postoperative photo was taken 20 months after reconstruction.

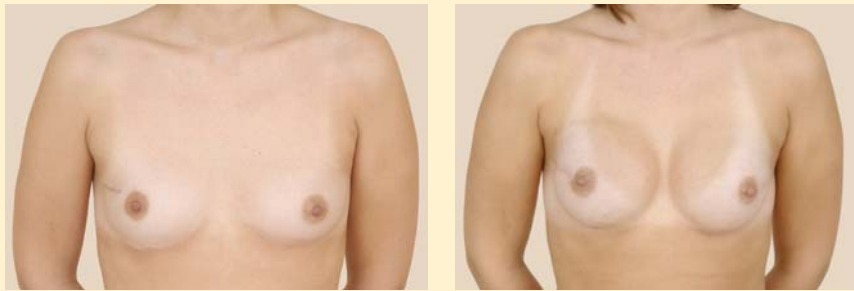

FIGURE 3. Preoperative (left) and postoperative (right) photos of a patient who underwent reconstruction with silicone implants after bilateral nipple-sparing mastectomy. The postoperative photo was taken at 9-month follow-up.

the implant becomes exposed, it will likely need to be removed. The risk of implant extrusion is, in part, why the implant is placed under the chest wall muscle, since the muscle provides protective cover. Because the breast skin often is very thin after mastectomy, placement of the implant directly under the skin alone does not provide adequate protective coverage and is therefore no longer an acceptable reconstructive technique.

Capsular contracture is another potential and more frequent complication of implant-based reconstruction. In all cases, the body forms a protective coverage, or fibrous capsule, around the implant. This process is called encapsulation. Most of the time, the capsule is relatively thin and pliable. Infrequently, however, the capsule can become thickened, hardened, and contracted, which constitutes capsular contracture. Although rare, severe contractures cause deformation of the reconstructed breast as well as pain. Severe contractures often require an operation to replace or remove the implant and treat the excessively thickened capsule. This can be done by exchanging the implant and either opening the capsule (capsulotomy) or removing the capsule (capsulectomy). If the contracture is significant enough or if the contracture recurs, then reconstruction using autologous tissue might be needed.

Advantages of implant reconstruction

Although nonautologous implant-based reconstruction can have some limitations, this procedure attracts many patients as a result of its advantages and good aesthetic results. The mastectomy procedure is prolonged by only about 1 hour, and most patients require only an overnight stay after the procedure. The recovery period is approximately 2 to 3 weeks, at which point tissue expansion is started.

What if radiation therapy is needed?

When treatment of the breast cancer is expected to involve radiation therapy right from the beginning, implant-based reconstruction is not an optimal choice. Radiation can affect the reconstruction in several negative ways. By design, radiation treats cancer by destroying dividing cells. Dividing cells are also required for wound healing and tissue remodeling. Without this remodeling ability, surgical scars are more susceptible to breakdown, which leads to tissue loss. In addition, because the effects of radiation are long-term, over time the thin tissue over the implant might respond poorly to the excessive stress of the implant, raising the possibility that tissue thinning could eventually lead to implant loss.⁷

Certainly there are instances when radiation therapy is not anticipated prior to the extirpative operation but

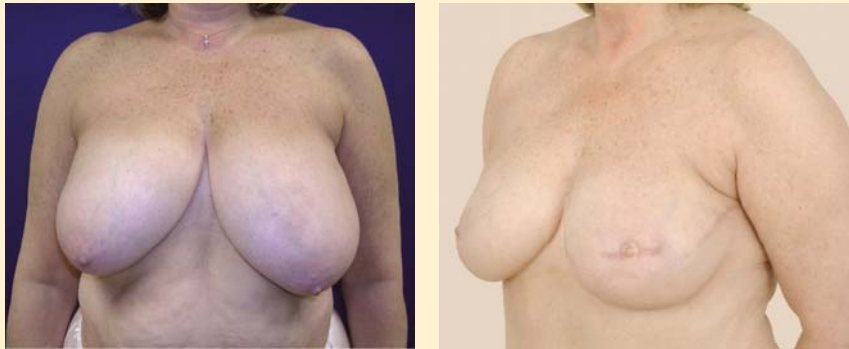

FIGURE 4. Preoperative (left) and postoperative (right) photos of a patient with left breast cancer who underwent mastectomy and immediate autologous reconstruction with the DIEP free flap technique. In a separate procedure, she had matching reduction mammoplasty of the right breast and nipple reconstruction on the reconstructed left breast. The postoperative photo was taken 17 months after initial reconstruction of the left breast.

then becomes necessary to complete the cancer treatment, based on final pathology results. Some patients in these circumstances may have had implants placed prior to the decision to give radiation. This does not doom the implant reconstruction to failure, however. Depending on the effect of the radiation and the patient's body, there might be only a limited impact on the implant and the overall reconstruction result. We recommend close follow-up in these patients to monitor for any long-term complications such as skin discoloration, implant extrusion, or capsular contracture, which can be addressed as they arise.

■ AUTOLOGOUS RECONSTRUCTION

Techniques using abdominal tissue

As noted above, autologous breast reconstruction uses the patient's own tissue. If the patient has adequate abdominal fat, the skin and fatty tissue of the lower abdomen may be used to reconstruct the missing breast. Historically, this type of reconstruction has included a portion of the abdominal muscles.

TRAM flap technique. The transverse rectus abdominis muscle (TRAM) flap technique takes advantage of the blood supply within the rectus abdominis muscle and its overlying skin and soft tissue. The muscle serves as the conduit for the blood supply of the skin and fatty tissue used in this method of reconstruction. The distal insertion of the muscle close to the pubic symphysis is cut, and the tissue receives its blood via the superior epigastric artery, which passes through the rectus muscle. This skin and soft tissue is then brought into the defect on the chest beneath the skin by tunneling it through the undermined skin flap between the abdomen and chest.

While the reconstructive results with the TRAM flap are good, this technique has been associated with increased risk of hernias or bulges in the abdominal wall. In sacrificing the rectus abdominis muscle, one

of the major contributors to posture and the dynamic abdominal contour of the ventral abdomen is lost and the abdominal wall is weakened. This risk becomes even more significant when both rectus abdominis muscles are used to reconstruct both breasts.

DIEP free flap technique. Recent advances in breast reconstruction involve a variation of the TRAM flap operation that allows preservation of the rectus abdominis muscle. This procedure—called the deep inferior epigastric perforator (DIEP) free flap technique—involves meticulous dissection of the vessels within the rectus abdominis muscle from their distal perforation through the rectus fascia all the way down to their proximal pedicle off of the external iliac artery and vein. Once these vessels are identified and isolated, they are transected and reanastomosed to the internal mammary or thoracodorsal vessels of the chest. This anastomosis requires a microsurgical operation to reestablish blood perfusion to the flap. To complete the reconstruction, the flap is then secured and tailored to form a new reconstructed breast (**Figure 4**). The main advantage of the DIEP technique is being able to use the patient's own tissue while minimizing morbidity to the patient.

Limitations of techniques using abdominal tissue. Although autologous reconstruction is most commonly performed using tissue from the lower abdomen, flaps from the lower abdomen can be used only when there is sufficient fatty tissue to provide bulk for reconstructing the breast. In thin patients, using flaps from the abdomen may not be a good option. Contraindications to autologous reconstruction using the abdomen include previous abdominal surgery such as abdominoplasty, liposuction, open cholecystectomy, or other major abdominal operations that would compromise circulation to the skin and tissue over the flap. Other relative contraindications to autologous tissue reconstruction using the

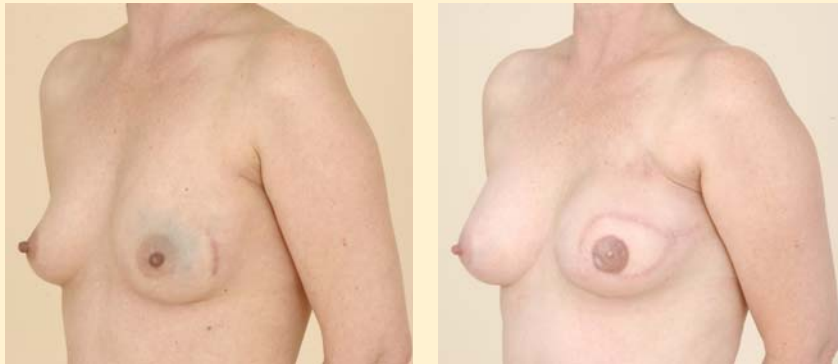

FIGURE 5. Preoperative (left) and postoperative (right) photos of a patient with left breast cancer who underwent mastectomy with immediate autologous reconstruction using the DIEP free flap procedure. This patient underwent radiation of the left breast following completion of her reconstruction. The postoperative photo was taken 20 months after surgery.

abdomen are obesity, smoking, a history of blood clots, and other major systemic medical conditions.

Options when abdominal tissue cannot be used

For patients who have insufficient tissue on the abdomen or have had previous abdominal surgery that compromises perfusion to the abdominal tissue, other options for autologous breast reconstruction are available. The gluteal tissue can be used, based on its superior or inferior blood supply, known as the superior gluteal artery perforator (SGAP) flap or the inferior gluteal artery perforator (IGAP) flap. Like the DIEP free flap technique, reconstruction using these flaps also requires a microsurgical procedure.

Another common option involves using skin and muscle from the back, or the latissimus dorsi myocutaneous flap. This flap does not require microsurgery; however, often the amount of tissue available to reconstruct the breast is inadequate to create a breast mound, requiring that the reconstruction be supplemented with an implant beneath the flap.⁸

Pros and cons of autologous reconstruction

Unlike implant-based reconstruction, autologous reconstruction obviously eliminates the need for implant replacement in the future. It also generally results in a more natural-feeling and natural-looking breast. Another advantage is that the breast reconstructed with autologous tissue will grow and decrease in size with weight fluctuations, just as a nonreconstructed breast would. Finally, in many cases the patient also essentially undergoes an abdominoplasty, or “tummy tuck” procedure, by virtue of how the tissue is harvested for reconstruction, which is likely to be welcomed by many patients.

At the same time, this need for an additional incision at the harvest site can constitute a drawback for other patients, given the additional scarring and a potential increased risk of complications. Additionally,

radiation therapy also can affect wound healing and tissue remodeling in the autologously reconstructed breast, although its impact on the healing process and cosmetic outcome is usually less detrimental than is the case with implant-based reconstruction. Most of the time, the reconstructed breast will maintain its shape and volume (Figure 5). However, some radiation changes can affect the final outcome of the reconstruction, and results vary by individual case.

■ COMPLETING THE RECONSTRUCTION

Nipple reconstruction

Reconstruction of the nipple and areola is important in that many patients feel that the nipple is what makes a breast. With the increased use of nipple-sparing mastectomy and improved reconstructive techniques, the aesthetic outcomes of reconstruction are often regarded as superior to many breast conservation procedures. A recent study by Cocquyt et al suggests that skin-sparing mastectomy with immediate DIEP flap reconstruction or TRAM flap reconstruction appears to yield a better cosmetic outcome than breast conservation therapy.⁹

Reconstruction of the nipple and areola restores the shape of the nipple, the shape of the areola, and the color of both with tattoos. Closing the autologous flap in a circular manner creates the shape of the areola, and the nipple is formed by local bilobed or trilobed skin flaps wrapped around each other to create a cone. Although nipple reconstruction can be performed at the time of immediate reconstruction, it is usually performed at a later time in the outpatient setting when the shape of the reconstructed breast is more definite after healing has occurred.

Revisional procedures

In many cases reconstructive breast surgery is not able to provide a breast that is shaped or sized exactly as

desired or that perfectly matches the contralateral breast. Revisional procedures are sometimes performed to improve breast appearance and symmetry. Most revisional breast surgeries are performed on an outpatient basis and at times can be completed at the time of nipple reconstruction.

Modifying the contralateral breast

Modification of the contralateral breast is often necessary, and either a mastopexy (breast lift), reduction, or augmentation of the contralateral side may be needed for symmetry.

Mastopexy and reduction mammoplasty. Mastopexy, a skin-tightening and nipple-repositioning procedure, is performed to correct soft tissue descent without removing much breast tissue (see **Figure 2**), while reduction mammoplasty involves removing 400 to 2,000 grams of breast tissue (see **Figure 4**). A patient who has had a unilateral mastectomy without reconstruction may be a candidate for reduction mammoplasty of the contralateral breast. A unilateral large breast can cause marked neck and back pain due to the asymmetry of the weight on the chest.

Augmentation. Patients with smaller breasts often will undergo a matching augmentation procedure on the contralateral breast following completion of mastectomy and reconstruction on the other side.

Prophylactic mastectomy. For some women with a very high lifetime risk of breast cancer, such as those with *BRCA1* or *BRCA2* gene mutations, prophylactic mastectomy of the contralateral breast or even bilateral prophylactic mastectomy may be recommended by the oncologic surgeon. In some of these selected patients with sufficient abdominal tissue, bilateral DIEP flaps may be suitable; otherwise, the reconstruction can be completed with tissue expanders and implants.

WHAT ABOUT INSURANCE COVERAGE?

As the result of a federal law enacted 10 years ago, insurance coverage should not be a concern for women who are considering breast reconstruction following mastectomy. The Women's Health and Cancer Rights Act of 1998 requires all medical insurers that provide coverage for mastectomy to also cover all stages of reconstruction of the affected breast as well as surgery and reconstruction of the contralateral breast to produce a symmetrical appearance.¹⁰

CONCLUSION

Although breast cancer remains a significant health risk to women and can result in significant disfigurement, breast reconstruction strategies continue to

improve. These strategies offer women who have undergone mastectomy some excellent options for creating a near-normal-appearing breast. Women interested in pursuing reconstruction should meet with a plastic surgeon early in the course of their breast cancer treatment planning in order to better understand the options available and make an informed and individualized choice.

REFERENCES

1. Smith RA, Saslow D, Sawyer KA, et al. American Cancer Society guidelines for breast cancer screening: update 2003. *CA Cancer J Clin* 2003; 53:141–169.
2. Breast cancer treatment and pregnancy. National Cancer Institute Web site. <http://www.cancer.gov/cancertopics/pdq/treatment/breast-cancer-and-pregnancy/HealthProfessional>. Updated February 8, 2008. Accessed February 11, 2008.
3. Reaby LL. Reasons why women who have mastectomy decide to have or not to have breast reconstruction. *Plast Reconstr Surg* 1998; 101:1810–1818.
4. Nold RJ, Beamer RL, Helmer SD, McBoyle MF. Factors influencing a woman's choice to undergo breast-conserving surgery versus modified radical mastectomy. *Am J Surg* 2000; 180:413–418.
5. Pusic A, Thompson TA, Kerrigan CL, et al. Surgical options for the early-stage breast cancer: factors associated with patient choice and postoperative quality of life. *Plast Reconstr Surg* 1999; 104:1325–1333.
6. FDA approves silicone gel-filled breast implants after in-depth evaluation [news release]. Rockville, MD: U.S. Food and Drug Administration; November 17, 2006. <http://www.fda.gov/bbs/topics/NEWS/2006/NEW01512.html>. Accessed February 7, 2008.
7. Kronowitz SJ, Robb GL. Breast reconstruction with postmastectomy radiation therapy: current issues. *Plast Reconstr Surg* 2004; 114:950–960.
8. Bostwick J III. Abdominal flap reconstruction. In: *Plastic and Reconstructive Breast Surgery*. 2nd ed. St. Louis, MO: Quality Medical Publishing; 2000:982–1015.
9. Cocquyt VF, Blondeel PN, Depypere HT, et al. Better cosmetic results and comparable quality of life after skin-sparing mastectomy and immediate autologous breast reconstruction compared to breast conservative treatment. *Br J Plast Surg* 2003; 56:462–470.
10. Your rights after a mastectomy...Women's Health & Cancer Rights Act of 1998. U.S. Department of Labor Web site. <http://www.dol.gov/ebsa/publications/whcra.html>. Accessed February 11, 2008.

ADDITIONAL READING

- Hoover SJ, Kenkel JM. Breast cancer, cancer prevention, and breast reconstruction. *Selected Readings in Plastic Surgery* 2002; 9:1–40.
- Hartrampf CR, Schefflan M, Black PW. Breast reconstruction with a transverse abdominal island flap. *Plast Reconstr Surg* 1982; 69:216–225.
- Hartrampf CR Jr, Bennett GK. Autogenous tissue reconstruction in the mastectomy patient: a critical review of 300 patients. *Ann Surg* 1987; 205:508–519.
- Elliott LF, Eskenazi L, Beegle PH Jr, Podres PE, Drazan L. Immediate TRAM flap breast reconstruction: 128 consecutive cases. *Plast Reconstr Surg* 1993; 92:217–227.
- Schusterman MA, Kroll SS, Weldon ME. Immediate breast reconstruction: why the free TRAM over the conventional TRAM flap? *Plast Reconstr Surg* 1992; 90:255–262.

Correspondence: Risal Djohan, MD, Department of Plastic Surgery, Cleveland Clinic, 9500 Euclid Avenue, A60, Cleveland, OH 44195; djohanr@ccf.org.