

CASE REPORT

> THE PATIENT

63-year-old woman

- ## > SIGNS & SYMPTOMS
- Swollen right hand and forearm
 - Minor trauma to hand
 - Previous diagnosis of cellulitis

Ahmad Rahal, MD;
Mahmoud Farhoud, MD;
Melissa Gaines, MD
University of Kansas
School of Medicine—
Wichita (Drs. Rahal and
Gaines); University of
Central Florida, College
of Medicine, Orlando
(Dr. Farhoud)

The authors acknowledge
K. James Kallail, PhD
(University of Kansas
School of Medicine—
Wichita) for his assistance
in the writing of this
manuscript.

a_rahal@hotmail.com

*The authors reported no
potential conflict of interest
relevant to this article.*

> THE CASE

A 63-year-old woman with a history of hyperlipidemia presented to our hospital with a swollen right hand. The patient noted that she had closed her hand in a car door one week earlier, causing minor trauma to the right third metacarpophalangeal joint. Shortly after injuring her hand, she'd sought care at an outpatient facility, where she was given a diagnosis of cellulitis and a prescription for an oral antibiotic. The swelling, however, worsened, prompting her visit to our hospital. She was admitted for further work-up and started on intravenous (IV) antibiotics.

Her family history included a sister with deep vein thrombosis (DVT) and a maternal aunt with breast cancer. The patient denied oral contraceptive use or a personal history of malignancy. On physical examination, her right hand and forearm were swollen, tender, and erythematous.

THE DIAGNOSIS

Laboratory data showed a normal complete blood count and complete metabolic panel. The patient's sedimentation rate and C-reactive protein level were elevated at 65 mm/hr and 110 mg/L, respectively. The patient was not improving on IV antibiotics, so we performed a right upper extremity venous duplex ultrasound. The ultrasound showed an occlusive thrombus in the right ulnar and radial veins (**FIGURES 1 AND 2**), and we diagnosed the patient with upper extremity deep vein thrombosis (UEDVT). (The timing of the diagnosis, relative to the injury to the patient's hand, appeared to have been coincidental.)

Further work-up revealed normal complement C3 and C4 tests, as well as negative antinuclear, anti-double stranded DNA, anti-Smith, and anticardiolipin antibody tests. Similarly, a factor II DNA analysis was negative. However, the patient was positive for the factor V Leiden heterozygous mutation.

DISCUSSION

More than 350,000 people are diagnosed with DVT or pulmonary embolism (PE) in the United States each year.¹ Up to 4% of all DVTs involve the upper extremities.² Secondary UEDVT, which occurs in patients with central venous catheters, malignancies, and thrombophilia, accounts for the majority of UEDVT cases; primary UEDVT is less common.³

Large epidemiologic studies have demonstrated that hypercoagulability is a risk factor for lower extremity DVT, but few data exist on the role of coagulation abnormalities in patients with primary UEDVT. The prevalence of clotting abnormalities in patients with primary UEDVT ranges from 8% to 43%.^{4,5} Factor V Leiden is the most common cause of inherited thrombophilia. Patients with heterozygous factor V Leiden mutation have a 7-fold increased risk of venous thrombosis.⁶

Héron and colleagues⁷ reported that 16 of 51 patients with at least one clotting abnormality had primary UEDVT. Factor V Leiden was found in 5 of those patients (20%).

Interestingly, 3 of the 5 carriers of the factor V Leiden mutation were older than 45 years. Our patient was 63, which was consistent with these findings.

Malignancy is also an important risk factor for UEDVT.^{8,9} In patients with a DVT in an unusual location, age- and sex-appropriate cancer screenings are strongly recommended. (Our patient had undergone a colonoscopy 8 years earlier, which was normal. She'd also had a recent mammogram and Pap smear, which were normal, as well.)

It's often difficult to distinguish between cellulitis and UEDVT

The differential diagnosis for UEDVT includes effort thrombosis (also known as Paget-Schroetter syndrome) and cellulitis.

■ **Effort thrombosis** usually occurs in young, otherwise healthy individuals and almost exclusively in the axillary and subclavian veins. Our patient's age and a venous duplex ultrasound ruled out any thrombosis in these locations.

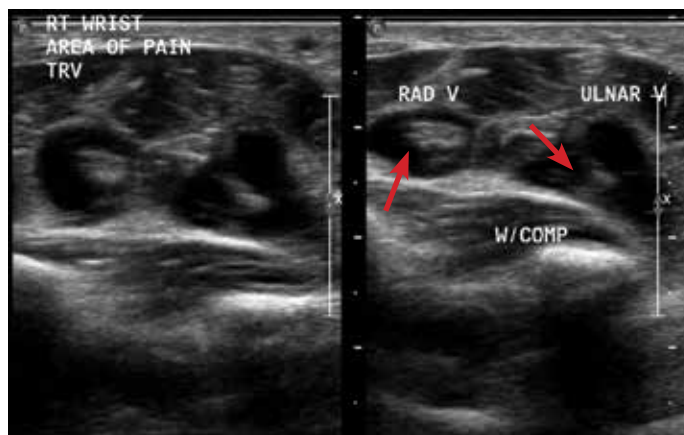
■ **Distinguishing cellulitis** from UEDVT based on clinical features can be difficult. In both conditions, the limb is swollen and painful and the skin is warm and erythematous. As a result, each condition is often misdiagnosed as the other.

But there are features that distinguish the 2. In patients with UEDVT, you're likely to see limb pain and a palpable cord (a hard, thickened palpable vein along the line of the deep veins). On the other hand, patients with cellulitis tend to have more systemic symptoms, such as fever, chills, and swollen lymph nodes, as well as skin breakdown, ulcers, and pus.

The American College of Chest Physicians (ACCP) recommends that the initial evaluation for patients with suspected UEDVT be a combined modality ultrasound (compression with either Doppler or color Doppler) rather than D-dimer or venography.¹⁰ Quickly arriving at a proper diagnosis is critical, given that up to one-third of patients with UEDVT will develop a PE.⁷ Other complications include superior vena cava syndrome, septic thrombophlebitis, thoracic duct obstruction, and brachial plexopathy.¹¹

FIGURE 1

Occlusive thrombus in the radial and ulnar veins

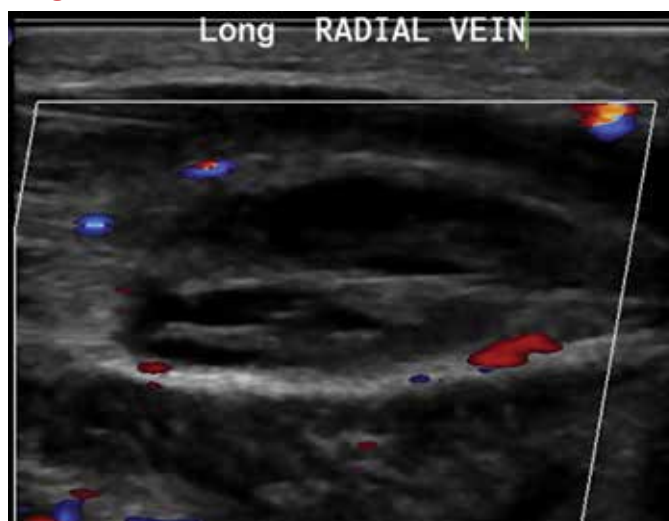


IMAGES COURTESY OF: AHMAD RAHAL, MD

A venous duplex ultrasound revealed an occlusive thrombus in the right radial and ulnar veins (arrows). These vessels showed abnormal compressibility.

FIGURE 2

Abnormal color flow with Doppler augmentation in the radial vein



Treat with anticoagulants for no longer than 3 months

The ACCP also recommends that patients who have UEDVT that isn't associated with a central venous catheter or with cancer be treated with anticoagulation for no longer than 3 months.¹⁰

■ **Our patient** was started on enoxaparin and warfarin. After 5 days at our hospital, she

CONTINUED ON PAGE 573

CONTINUED FROM PAGE 555

was taken off the enoxaparin and discharged home on warfarin 5 mg/d. The swelling completely resolved one week later.

THE TAKEAWAY

Ulnar and radial DVT in a patient with factor V Leiden mutation is a rare condition. UEDVT should be included in the differential diagnosis for cellulitis whenever the diagnosis is uncertain or the patient doesn't respond to antibiotics. Factor V Leiden mutation appears to be a risk factor in UEDVT and testing for it should be considered.

JFP

References

- Office of the Surgeon General (US); National Heart, Lung, and Blood Institute (US). The Surgeon General's Call to Action to Prevent Deep Vein Thrombosis and Pulmonary Embolism. Available at: <http://www.ncbi.nlm.nih.gov/books/NBK44178/>. Rockville, MD: Office of the Surgeon General (US); 2008.
- Sawyer GA, Hayda R. Upper-extremity deep venous thrombosis following humeral shaft fracture. *Orthopedics*. 2011;34:141.
- Leebeek FW, Stadhouders NA, van Stein D, et al. Hypercoagulability states in upper-extremity deep venous thrombosis. *Am J Hematol*. 2001;67:15-19.
- Prandoni P, Polistena P, Bernardi E, et al. Upper-extremity deep vein thrombosis. Risk factors, diagnosis, and complications. *Arch Intern Med*. 1997;157:57-62.
- Ruggeri M, Castaman G, Tosetto A, et al. Low prevalence of thrombophilic coagulation defects in patients with deep vein thrombosis of the upper limbs. *Blood Coagul Fibrinolysis*. 1997;8:191-194.
- Ornstein DL, Cushman M. Cardiology patient page. Factor V Leiden. *Circulation*. 2003;107:e94-e97.
- Héron E, Lozinguez O, Alhenc-Gelas M, et al. Hypercoagulable states in primary upper-extremity deep vein thrombosis. *Arch Intern Med*. 2000;160:382-386.
- Linnemann B, Meister F, Schwonberg J, et al; MAISTHRO registry. Hereditary and acquired thrombophilia in patients with upper extremity deep-vein thrombosis. Results from the MAISTHRO registry. *Thromb Haemost*. 2008;100:440-446.
- Monreal M, Lafoz E, Ruiz J, et al. Upper-extremity deep venous thrombosis and pulmonary embolism. A prospective study. *Chest*. 1991;99:280-283.
- Holbrook A, Schulman S, Witt DM, et al; American College of Chest Physicians. Evidence-based management of anticoagulant therapy: Antithrombotic Therapy and Prevention of Thrombosis, 9th ed: American College of Chest Physicians Evidence-Based Clinical Practice Guidelines. *Chest*. 2012;141:e152S-e184S.
- Becker DM, Philbrick JT, Walker FB 4th. Axillary and subclavian venous thrombosis. Prognosis and treatment. *Arch Intern Med*. 1991;151:1934-1943.

PRACTICE OPPORTUNITIES



Santa Barbara/Urgent Care Medical Director for Sansum Clinic

Sansum Clinic is the largest and oldest multi-specialty group between San Francisco and Los Angeles with over 180 physicians and surgeons and a staff of healthcare professionals in over 30 specialized areas of medicine. We offer a competitive salary, full benefits package, and an excellent living and practice environment.

We are looking for an Urgent Care Physician Medical Director who will see UC patients part-time and manage our 2 outpatient Urgent Care facilities located in Sunny Santa Barbara and Lompoc California.

Required Skills: Successful candidates will be well-trained and board-certified in Family Medicine, Urgent Care, or Emergency Medicine with prior experience working in an ER or UC setting as well as leadership/administrative experience. We are looking for team players who are enthusiastic, motivated, and committed individuals who work well in a group environment. Come learn more about why physicians want to work at Sansum Clinic and enjoy a work-life balance as well as opportunity to work with a team of well-trained, trusted, and dedicated professionals who value each and every team member within the group.

Benefits our physicians enjoy: Competitive compensation and benefits, malpractice with health insurance coverage, CME allowance, shareholder opportunities after 2 years.

Please email your CV to: mdjobs@sansumclinic.org
For more information: visit www.sansumclinic.org