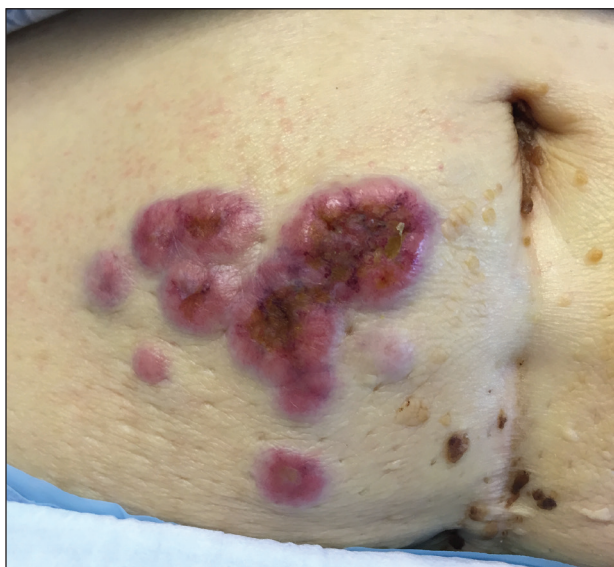
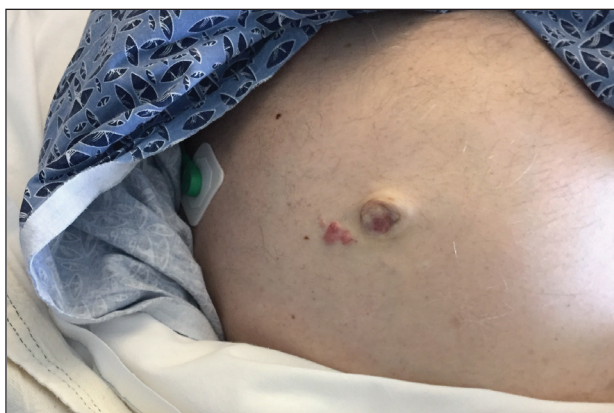


Erythematous Periumbilical Papules and Plaques

Ryan Karmouta, MD, MBA; Anar Mikailov, MD



A 75-year-old woman (patient 1) with a history of localized invasive ductal breast cancer treated definitively with lumpectomy and radiation therapy more than a decade ago presented to the emergency department with jaundice, abdominal pain, weakness, and multiple periumbilical pink-red papules (top) of 2 weeks' duration. Prior to presentation, the skin lesions did not improve with 10 days of acyclovir treatment prescribed by her primary care physician for presumed herpes zoster.



An 86-year-old man (patient 2) with chronic lymphocytic leukemia treated with ibrutinib presented to the emergency department with jaundice, abdominal pain, weakness, and multiple pink periumbilical papules (bottom) of 6 weeks' duration. Prior to presentation, the skin lesions did not improve with 21 days of valacyclovir treatment prescribed by his oncologist for presumed herpes zoster.

WHAT'S THE DIAGNOSIS?

- acyclovir-resistant herpes zoster
- arthropod assault
- cutaneous Crohn disease
- metastatic cancer
- sarcoidosis

PLEASE TURN TO **PAGE E27** FOR THE DIAGNOSIS

Dr. Karmouta is from Harvard Medical School, Boston, Massachusetts. Dr. Mikailov is from the Department of Dermatology, Beth Israel Deaconess Medical Center, Boston.

The authors report no conflict of interest.

Correspondence: Ryan Karmouta, MD, MBA, Harvard Medical School, 25 Shattuck St, Boston, MA 02215 (ryankarmouta@gmail.com).

THE DIAGNOSIS: Metastatic Cancer

Further workup of patient 1 revealed an alkaline phosphatase level of 743 U/L (reference range, 30–120 U/L), total bilirubin level of 8.5 mg/dL (reference range, 0.3–1.2 mg/dL), and a white blood cell count of 14,000/ μ L (reference range, 4500–11,000/ μ L). Computed tomography of the abdomen and pelvis demonstrated cancer of unknown primary site that had metastasized to the colon, liver, and lungs. There was suspicion for potential colon cancer as the primary disease; however, based on the cutaneous findings, a skin biopsy was performed to confirm the diagnosis. Histology and immunohistochemistry revealed adenocarcinoma tumor cells positive for *CDX2* (caudal type homeobox 2) and cytokeratin (CK) 7 with a subset positive for CK-20. The cells were negative for estrogen receptor, progesterone receptor, mammaglobin, gross cystic disease fluid protein, and *GATA3* (GATA binding protein 3). Immunohistochemistry was most consistent with pancreatic cancer. During palliative percutaneous transhepatic biliary drainage placement, a liver biopsy confirmed the skin biopsy results.

Further workup of patient 2 revealed a white blood cell count of 13,000/ μ L (reference range, 4500–11,000/ μ L). Computed tomography of the chest, abdomen, and pelvis revealed metastatic disease to the lungs with a suspicion for colon cancer as the primary site. Biopsy of the skin lesion revealed a mucin-producing adenocarcinoma, and immunohistochemistry was positive for keratin (AE1/AE3), CK-20, and *CDX2*, consistent with metastatic colon carcinoma. Immunohistochemistry of the biopsied skin lesion was nonreactive for CK-7. The patient had a colonoscopy that revealed a fungating, partially obstructing, circumferential large mass in the ascending colon.

Metastasis to the skin from visceral malignancies is not uncommon and may represent the first evidence of widespread disease, particularly in breast cancer or mucosal cancers of the head and neck.¹ Cutaneous metastasis of colon cancer is uncommon and cutaneous metastasis of pancreatic cancer is rare. Furthermore, nonumbilical sites are much more common than umbilical sites for cutaneous metastatic disease.² Pancreatic cancer is estimated to be the origin of a cutaneous umbilical metastasis, frequently termed *Sister Mary Joseph nodule*, in 7% to 9% of cases; colon cancer is estimated to account for 13% to 15% of cases.³ *Sister Mary Joseph nodule* or sign refers to a nodule often bulging into the umbilicus, signifying metastasis from a malignant cancer.

In a study of cutaneous metastases, 10% (42/420) of patients with metastatic disease had cutaneous metastasis; 0.48% (2/420) were due to pancreatic cancer and 4.3% (18/420) were due to colon cancer.⁴

In another review, 63 cases of cutaneous metastasis of pancreatic cancer were found, 43 of which were nonumbilical.²

On immunohistochemistry, CK-7 positivity is highly specific for pancreatic cancer.² Cytokeratin 7 often is used in conjunction with CK-20 to differentiate various types of glandular tumors. *CDX2* is a highly sensitive and specific marker for adenocarcinomas of intestinal origin.⁵ The negative estrogen receptor, progesterone receptor, mammaglobin, gross cystic disease fluid protein, and *GATA3* stains are useful in excluding breast cancer (patient 1 had history of breast cancer).

When cutaneous involvement is present in pancreatic cancer, the disease usually is widespread. Multiple studies have reported involvement of other organs with cutaneous metastasis at rates of 88.9%,⁶ 90.3%,⁷ and 93.5%.² However, early recognition of metastatic cancerous lesions can lead to earlier diagnosis and earlier palliative treatment, perhaps prolonging median survival time in patients. In a review of 63 patients with cutaneous metastatic pancreatic cancer, the authors found a median survival time of 5 months, with surgery, chemotherapy, radiation therapy, or a combination helping to improve survival time from a median of 3.0 to 8.3 months.²

The location of lesions and duration of disease in both patients was atypical for arthropod assault. Acyclovir-resistant herpes zoster rarely is reported outside of human immunodeficiency patients; in addition, there was a lack of clear dermatomal distribution. Although cutaneous Crohn disease can manifest as pink papules, it is rare and unlikely as a presenting symptom. Cutaneous sarcoidosis can take many different skin manifestations, and patients can have cutaneous involvement without systemic manifestation. In both patients, medical history was more indicative of metastatic cancer than the other options in the differential diagnosis.

Cutaneous metastasis from colon cancer and pancreatic cancer is rare, and the prognosis is poor in these cases; however, in the appropriate clinical scenario, especially in a patient with a history of cancer, sinister etiologies should be considered for firm red papules of the umbilicus. Skin biopsy coupled with immunohistochemical staining can assist in identifying the primary malignancy.

REFERENCES

1. Schwartz RA. Cutaneous metastatic disease. *J Am Acad Dermatol.* 1995;33:161-165.
2. Zhou HY, Wang XB, Gao F, et al. Cutaneous metastasis from pancreatic cancer: a case report and systematic review of the literature [published online October 10, 2014]. *Oncol Lett.* 2014;8:2654-2660.
3. Galvañ VG. Sister Mary Joseph's nodule. *Ann Intern Med.* 1998;128:410.

4. Lookingbill DP, Spangler N, Helm KF. Cutaneous metastases in patients with metastatic carcinoma: a retrospective study of 4020 patients. *J Am Acad Dermatol*. 1993;29:228-236.
5. Werling RW, Yaziji H, Bacchi CE, et al. CDX2, a highly sensitive and specific marker of adenocarcinomas of intestinal origin: an immunohistochemical survey of 476 primary and metastatic carcinomas. *Am J Surg Pathol*. 2003;27:303-310.
6. Takeuchi H, Kawano T, Toda T, et al. Cutaneous metastasis from pancreatic adenocarcinoma: a case report and a review of the literature. *Hepatogastroenterology*. 2003;50:275-277.
7. Horino K, Hiraoka T, Kanemitsu K, et al. Subcutaneous metastases after curative resection for pancreatic carcinoma: a case report and review of the literature. *Pancreas*. 1999; 19:406-408.