

Point of Care Ultrasound (POCUS) for Small Bowel Obstruction in the ED

Rebecca Caton, MD, Patrick McCaffrey, MD, Jessica Zahn, MD, Joseph Colla, MD

POCUS is an effective diagnostic tool for identifying small bowel obstruction at the bedside.

Small bowel obstruction (SBO) accounts for 2% of all cases of abdominal pain presenting to the ED and 15% of abdominal pain admissions to surgical units from the ED.^{1,2} SBO can be a difficult diagnosis; the most common symptoms include nausea, vomiting, abdominal pain, obstipation, and constipation. The symptomatology depends on multiple factors: the area of the blockage, length of obstruction, and degree of the obstruction (either partial or complete).³ An upper gastrointestinal (GI) blockage classically presents with nausea and vomiting, while a lower GI blockage often presents with abdominal pain, constipation, and obstipation. Complications of obstruction range from significant morbidity—such as bowel strangulation (23%) and sepsis (31%)—to mortality (9%).⁴ ED POCUS allows for rapid and accurate diagnosis of SBO.

Case

A 60-year-old female with a past medical history of peptic ulcer disease and multiple abdominal surgeries, including umbilical hernia repair, appendectomy, and total abdominal hysterectomy, presented to the ED with an 8-hour history of nausea and vomiting. She reported that her abdomen felt bloated. She had experienced non-bloody, watery stools for the prior 3 weeks. She also reported three to four weeks of epigastric abdominal pain similar to her previous “ulcer pain.” Of note, she was evaluated in GI clinic one day prior to her ED visit for dysphagia, abdominal distention, and diarrhea and was scheduled for an outpatient upper endoscopy. Initial vitals were significant for a heart rate of 100 beats/min. Physical exam was significant for a mildly distended abdomen, tender to palpation at epigastrium without rebound or guarding. Labs showed a white blood cell count of 11.8 K/uL and otherwise unremarkable complete blood count, basic metabolic panel, liver function tests, and lactate measurement. Given the patient’s history of multiple abdominal surgeries and clinical presentation, POCUS was performed to evaluate for SBO. Dilated loops of small bowel were visualized in the lower abdomen gas, suggestive of SBO.

Dr. Caton practices in the Department of Emergency Medicine at Northwest Community Hospital, Arlington Heights, Illinois.

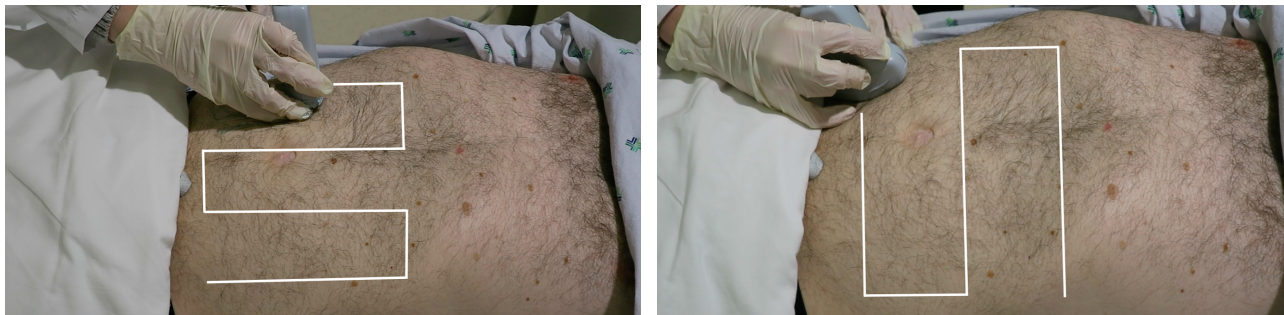
Dr. McCaffrey and **Dr. Zahn** are emergency medicine residents in the Department of Emergency Medicine at the University of Illinois at Chicago.

Dr. Colla is the Emergency Ultrasound Fellowship Director in the Department of Emergency Medicine at the University of Illinois at Chicago.

Authors’ Disclosure Statement: The authors report no actual or potential conflict of interest in relation to this article.

DOI: 10.12788/emed.2018.0109

POINT OF CARE ULTRASOUND (POCUS) FOR SMALL BOWEL OBSTRUCTION IN THE ED



Figures 1 and 2. POCUS scan pattern for SBO, known as “mowing the lawn.” Probe marker is to the patient’s right above in the transverse plane and to the patient’s head below in the sagittal plane.

Since the small bowel encompasses a large portion of the abdomen, to fully evaluate for SBO, multiple views are necessary. These include the epigastrium, bilateral colic gutters, and suprapubic regions.⁵ Use the low-frequency curvilinear transducer to obtain these views, scanning in the transverse and sagittal planes (see **Figures 1 and 2**). Scan while moving the transducer in columns (ie, “mowing the lawn”), making sure to cover the entire abdomen. To assure that you are evaluating the small bowel, and not the large bowel, look for the characteristic plicae circularis of the small bowel (shown in **Figure 3**). In children and very slender adults, the high-frequency linear probe may provide enough depth to obtain adequate views.

A fluid-filled small intestinal segment >2.5 cm is consistent with a diagnosis of SBO. Measuring the diameter of the small bowel is both the most sensitive and specific sign; a measurement of greater than 2.5 cm is diagnostic, with a sensitivity of 97% and specificity of 91% (see **Figure 4**).⁶ This can be somewhat difficult to visualize, as bowel loops are multidirectional and diameters can mistakenly be taken on an indirect cut; to avoid over- or underestimation of bowel diameter, you may want to measure in the short axis using a transverse cross-sectional view of the bowel.

Lack of peristalsis is suggestive of a closed-loop obstruction. However, this finding may be more difficult to visualize, as it requires several continuous minutes of scanning or repeated exams to truly establish absent peristalsis. In prolonged courses of SBO, the bowel wall can measure >3 mm, which suggests necrosis, warranting accelerated surgical intervention. In addition, the detection of extraluminal peritoneal fluid can help determine the severity of the SBO, and small versus large fluid amounts can help determine

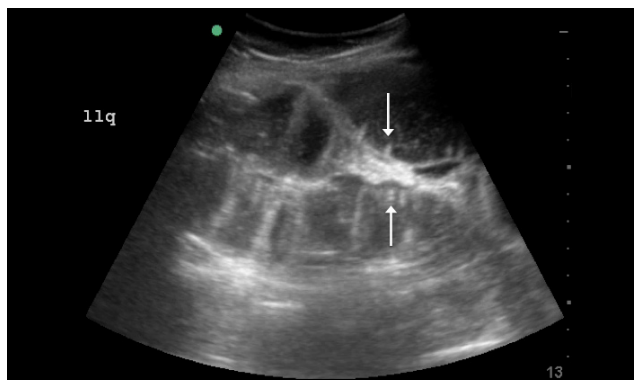


Figure 3. Dilated loops of small bowel with characteristic plicae circularis (white arrows).

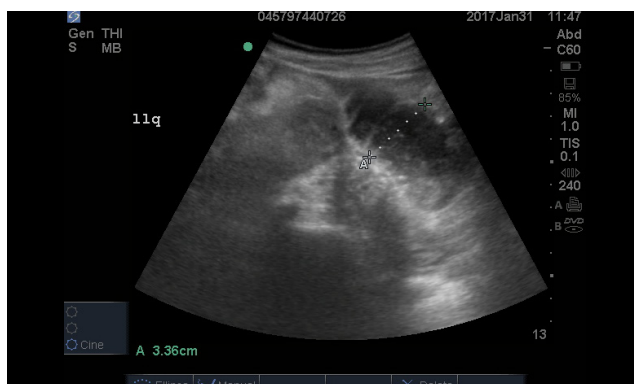


Figure 4. A dilated loop of small bowel measuring 3.36 cm.

POINT OF CARE ULTRASOUND (POCUS) FOR SMALL BOWEL OBSTRUCTION IN THE ED

whether medical or surgical management is warranted (see **Figure 5**).⁷

Discussion

Increased time to diagnosis of SBO can lead to prolonged patient suffering and greater complication rates. The gold standard for diagnosing SBO—CT with intravenous and oral contrast—can take hours, requiring patients, who are often nauseated, to ingest and tolerate oral contrast. In the past, an “obstructive series” of x-rays would have been used early in the work-up of possible SBO.⁶

Recent literature suggests that POCUS is not only faster, more cost effective, and advantageous (involving no ionizing radiation), but also more accurate than x-rays. Specifically, a meta-analysis by Taylor et al showed pooled estimates for obstructive series x-rays have a sensitivity (Sn) of 75%, a specificity (Sp) of 66%, a positive likelihood ratio (+LR) of 1.6, and a negative likelihood ratio (-LR) of 0.43.¹ On the other hand, pooled results from ED studies of emergency medicine (EM) residents performing POCUS in patients with signs and symptoms suspicious for SBO showed POCUS had a Sn of 97%, Sp of 90%, +LR of 9.5, and a -LR of 0.04.^{1,5,8} While detractors point to the operator-dependent nature of POCUS, literature suggests that with EM residents novice to POCUS for SBO (defined as less than 5 previous scans for SBO) were given a 10-minute didactic session and yielded Sn 94%, Sp 81%, +LR 5.0, -LR 0.07.⁵ Unluer et al trained novice EM residents for 6 hours and found them to yield Sn 98%, Sp 95%, +LR 19.5, and -LR 0.02.⁸ Thus, while it is no surprise that those with more training attain better results, both studies show it does not take much time for EM providers to surpass the accuracy of x-rays with POCUS.

Case Conclusion

The findings on POCUS highly suggested the diagnosis of an SBO. A CT scan of the abdomen and pelvis with intravenous and oral contrast was ordered to further evaluate obstruction, transition point, and possible complications, including signs of ischemia per surgical request. CT demonstrated dilated loops of small bowel with transition point in the right lower quadrant, with a small amount of mesenteric fluid consistent with SBO with possible early bowel compromise due to ischemia. General surgery admitted the patient; conservative treatment with serial abdominal exams, nasogastric tube, NPO and bowel rest was ordered. The patient’s diet was gradually advanced, and she was discharged on the eleventh day of hospitalization.

Summary

POCUS is a useful non-invasive tool that can accurately diagnose SBO. POCUS has increased sensitivity and specificity when compared to abdominal X-rays. This bedside imaging will not only give the ED provider rapid diagnostic information but also lead to expedited surgical intervention.

References

1. Taylor MR, Lalani N. Adult small bowel obstruction. *Acad Emerg Med*. 2013;20(6):528-544.
2. Hastings RS, Powers RD. Abdominal pain in the ED: a 35-year retrospective. *Am J Emerg Med*. 2011;29:711-716.

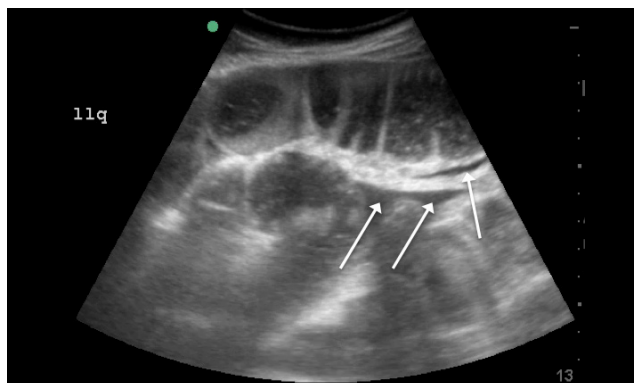


Figure 5. Dilated, fluid-filled loops of small bowel with extraluminal fluid (arrows).

POINT OF CARE ULTRASOUND (POCUS) FOR SMALL BOWEL OBSTRUCTION IN THE ED

3. Markogiannakis H, Messaris E, Dardamanis D, et al. Acute mechanical bowel obstruction: clinical presentation, etiology, management and outcome. *World J Gastroenterol.* 2007;13:432.
4. Bickell N, Federman A, Aufses A. Influence of time on risk of bowel resection in complete small bowel obstruction. *J Am Coll Surg.* 2005;201(6):847-854.
5. Jang TB, Chandler D, Kaji AH. Bedside ultrasonography for the detection of small bowel obstruction in the emergency department. *Emerg Med J.* 2011;28:676-678.
6. Carpenter CR, Pines JM. The end of X-rays for suspected small bowel obstruction? Using evidence-based diagnostics to inform best practices in emergency medicine. *Acad Emerg Med.* 2013;20:618-20.
7. Grassi R, Romano S, D'Amario F, et al. The relevance of free fluid between intestinal loops detected by sonography in the clinical assessment of small bowel obstruction in adults. *Eur J Radiol.* 2004;50(1):5-14.
8. Unlüer E, Yavaş O, Eroğlu O, Yılmaz C, Akarca F. Ultrasonography by emergency medicine and radiology residents for the diagnosis of small bowel obstruction. *Eur J Emerg Med.* 2010;17(5):260-264.