

DX ACROSS THE SKIN COLOR SPECTRUM

Longitudinal Melanonychia

Tristi M. Edwards, MBBS, MSc^a; Richard P. Usatine, MD^b; Candrice R. Heath, MD^c

Simultaneously published in *Cutis* and *Federal Practitioner*. doi:10.12788/cutis.0972

Longitudinal melanonychia (LM) is a pigmented linear band—brown, black, or gray—spanning the length of the nail plate due to the presence of excess melanin, which may be attributed to a benign or malignant process and may warrant further investigation.^{1,2} The majority of patients who present with LM are diagnosed with melanocytic activation of the nail matrix due to their inherent darker skin tone or various triggers including trauma, infection, and medications. Longitudinal melanonychia secondary to melanocytic activation often occurs spontaneously in patients with skin of color.³ Less commonly, LM is caused by a nail matrix nevus or lentigo; however, LM may arise secondary to subungual melanoma, a more dangerous cause.

A thorough clinical history including duration, recent changes in LM manifestation, nail trauma, or infection is helpful in evaluating patients with LM; however, a history of nail trauma can be misleading, as nail changes attributed to the trauma may in fact be melanoma. Irregularly spaced vertical lines of pigmentation ranging from brown to black with variations in spacing and width are characteristic of subungual melanoma.⁴ Nail dystrophy, granular hyperpigmentation, and Hutchinson sign (extension of pigmentation to the nail folds) also are worrisome features.⁵ In recent years, dermoscopy has become an important tool in the clinical examination of LM, with the development of criteria based on color and pattern recognition.^{5,6} Dermoscopy can be useful in screening potential candidates for biopsy. Although clinical examination and dermoscopy are essential to evaluating LM, the gold-standard diagnostic test when malignancy is suspected is a nail matrix biopsy.^{1,2,6,7}

EPIDEMIOLOGY

It is not unusual for patients with darker skin tones to develop LM due to melano-

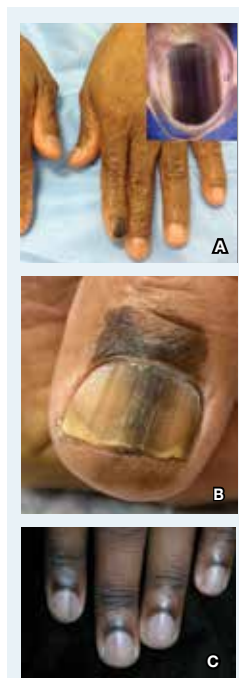
cytic activation of multiple nails with age. This finding can be seen in approximately 80% of African American individuals, 30% of Japanese individuals, and 50% of Hispanic individuals.² It has even been reported that approximately 100% of Black patients older than 50 years will have evidence of LM.³

In a retrospective analysis, children presenting with LM tend to have a higher prevalence of nail matrix nevi compared to adults (56.1% [60/106] vs 34.3% [23/66]; $P = .005$).⁸ Involvement of a single digit in children is most likely indicative of a nevus; however, when an adult presents with LM in a single digit, suspicion for subungual melanoma should be raised.^{2,3,9}

Two separate single-center retrospective studies showed the prevalence of subungual melanoma in patients presenting with melanonychia in Asia. Jin et al¹⁰ reported subungual melanoma in 6.2% (17/275) of Korean patients presenting with melanonychia at a general dermatology clinic from 2002 to 2014. Lyu et al⁸ studied LM in 172 Chinese patients in a dermatology clinic from 2018 to 2021 and reported 9% (6/66) of adults (aged ≥ 18 years) with subungual melanoma, with no reported cases in childhood (aged < 18 years).

Although the prevalence of subungual melanoma in patients with LM is low, it is an important diagnosis that should not be missed. In confirmed cases of subungual melanoma, two-thirds of lesions manifested as LM.^{3,10,11} Thus, LM arising in an adult in a single digit is more concerning for malignancy.^{2,3,7,9}

Individuals of African and Asian descent as well as American Indian individuals are at highest risk for subungual melanoma with a poor prognosis compared to other types of melanoma, largely due to diagnosis at an advanced stage of disease.^{3,9} In a retrospective study of 25 patients with surgically treated subungual melanoma, the



A Melanoma in situ manifesting as longitudinal melanonychia (LM) in a single digit in a Black man. Dermoscopy showed irregular dark bands of brown pigmentation and micro-Hutchinson sign on the cuticle (inset).

B Melanoma manifesting as LM with a prominent Hutchinson sign in a Hispanic man, with variable shades of brown covering more than 50% of the nail width.

C Longitudinal melanonychia of ≥ 2 nails with a pseudo-Hutchinson sign (pigment on the nail folds) in a young Black man demonstrating ethnic/racial melanosis. The longitudinal bands, which were caused by benign melanocytic activation, are more gray than brown and are less than 3 mm wide.

Photographs courtesy of Richard P. Usatine, MD.

mean recurrence-free survival was 33.6 months. The recurrence-free survival was 66% at 1 year and 40% at 3 years, and the overall survival rate was 37% at 3 years.¹²

Key clinical features in individuals with darker skin tones

- In patients with darker skin tones, LM tends to occur on multiple nails as a result of melanocytic activation.^{2,13}
- Several longitudinal bands may be noted on the same nail and the pigmentation of the bands may vary. With age, these longitudinal bands typically increase in number and width.¹³
- Pseudo-Hutchinson sign may be present due to ethnic melanosis of the proximal nail fold.^{13,14}
- Dermoscopic findings of LM in patients with skin of color include wider bands ($P = .0125$), lower band brightness ($P < .032$), and higher frequency of changing appearance of bands ($P = .0071$).¹⁵

WORTH NOTING

When patients present with LM, thorough examination of the nail plate, periungual skin, and distal pulp of all digits on all extremities with adequate lighting is important.² Dermoscopy is useful, and a gel interface helps for examining the nail plates.⁷

Clinicians should be encouraged to biopsy or immediately refer patients with concerning nail unit lesions. Cases of LM most likely are benign, but if some doubt exists, the lesions should be biopsied or tracked closely with clinical and dermoscopic images, with a biopsy if changes occur.¹⁶ In conjunction with evaluation by a qualified clinician, patients also should be encouraged to take photographs, as the evolution of nail changes is a critical part of clinical decision-making on the need for a biopsy or referral.

HEALTH DISPARITY HIGHLIGHT

Despite the disproportionately high mortality rates from subungual melanoma in Black and Hispanic populations,^{3,9} studies often do not adequately represent these populations. Although subungual melanoma is rare, a

delay in the diagnosis contributes to high morbidity and mortality rates.

Author affiliation

^aSUNY Downstate Health Sciences University, New York
^bFamily and Community Medicine and Dermatology, and Cutaneous Surgery, University of Texas Health, San Antonio
^cDepartment of Urban Health and Population, Science, Center for Urban Bioethics, Lewis Katz School of Medicine at Temple University, Philadelphia, Pennsylvania

References

1. Tosti A, Piraccini BM, de Farias DC. Dealing with melanonychia. *Semin Cutan Med Surg*. 2009;28:49-54. doi:10.1016/j.sder.2008.12.004
2. Piraccini BM, Dika E, Fanti PA. Tips for diagnosis and treatment of nail pigmentation with practical algorithm. *Dermatol Clin*. 2015;33:185-195. doi:10.1016/j.det.2014.12.002
3. Halteh P, Scher R, Artis A, et al. Assessment of patient knowledge of longitudinal melanonychia: a survey study of patients in outpatient clinics. *Skin Appendage Disord*. 2016;2:156-161. doi:10.1159/000452673
4. Singal A, Bisherwal K. Melanonychia: etiology, diagnosis, and treatment. *Indian Dermatol J Online*. 2020;11:1-11. doi:10.4103/idoj.IDOJ_167_19
5. Benati E, Ribero S, Longo C, et al. Clinical and dermoscopic clues to differentiate pigmented nail bands: an International Dermoscopy Society study. *J Eur Acad Dermatol Venereol*. 2017;31:732-736. doi:10.1111/jdv.13991
6. Sawada M, Yokota K, Matsumoto T, et al. Proposed classification of longitudinal melanonychia based on clinical and dermoscopic criteria. *Int J Dermatol*. 2014;53:581-585. doi:10.1111/jjd.12001
7. Starace M, Alessandrini A, Brandi N, et al. Use of nail dermoscopy in the management of melanonychia. *Dermatol Pract Concept*. 2019;9:38-43. doi:10.5826/dpc.0901a10
8. Lyu A, Hou Y, Wang Q. Retrospective analysis of longitudinal melanonychia: a Chinese experience. *Front Pediatr*. 2023;10:1065758. doi:10.3389/fped.2022.1065758
9. Williams NM, Obayomi AO, Diaz-Perez, JA, et al. Monodactylous longitudinal melanonychia: a sign of Bowen's disease in skin of color. *Skin Appendage Disord*. 2021;7:306-310. doi:10.1159/000514221
10. Jin H, Kim JM, Kim GW, et al. Diagnostic criteria for and clinical review of melanonychia in Korean patients. *J Am Acad Dermatol*. 2016;74,1121-1127. doi:10.1016/j.jaad.2015.12.039
11. Halteh P, Scher R, Artis A, et al. A survey-based study of management of longitudinal melanonychia amongst attending and resident dermatologists. *J Am Acad Dermatol*. 2017;76:994-996. doi:10.1016/j.jaad.2016.11.053
12. LaRocca CJ, Lai L, Nelson RA, et al. Subungual melanoma: a single institution experience. *Med Sci (Basel)*. 2021;9:57. doi:10.3390/medsci9030057
13. Baran LR, Ruben BS, Kechijian P, et al. Non-melanoma Hutchinson's sign: a reappraisal of this important, remarkable melanoma simulant. *J Eur Acad Dermatol Venereol*. 2018;32:495-501. doi:10.1111/jdv.14715
14. Sladden MJ, Mortimer NJ, Osborne JE. Longitudinal melanonychia and pseudo-Hutchinson sign associated with amlodipine. *Br J Dermatol*. 2005;153:219-220. doi:10.1111/j.13652133.2005.06668.x
15. Lee DK, Chang MJ, Desai AD, et al. Clinical and dermoscopic findings of benign longitudinal melanonychia due to melanocytic activation differ by skin type and predict likelihood of nail matrix biopsy. *J Am Acad Dermatol*. 2022;87:792-799. doi:10.1016/j.jaad.2022.06.1165
16. Hogue L, Harvey VM. Basal cell carcinoma, squamous cell carcinoma, and cutaneous melanoma in skin of color patients. *Dermatol Clin*. 2019;37:519-526. doi:10.1016/j.det.2019.05.009