

THE CLINICAL PICTURE

MOHAMED M. GAD, MD

Research Fellow, Department of Cardiovascular Medicine, Heart and Vascular Institute, Cleveland Clinic

AMIT GUPTA, MD

Clinical Assistant Professor, Department of Radiology, Division of Cardiothoracic Imaging, University Hospitals Cleveland Medical Center, Case Western Reserve University, Cleveland, OH

Dancing sternal wires: A radiologic sign of sternal dehiscence

A 52-YEAR-OLD MAN underwent coronary artery bypass grafting, which was complicated by cardiac tamponade requiring repeat sternotomy with mediastinal washout (Figure 1). On postoperative day 4, plain imaging revealed a midline sternal lucency and a slight leftward deviation of the second-from-the-lowest sternal wire (Figure 2), subtle signs suggesting sternal dehiscence. Those signs were missed initially, as no clinical signs of dehiscence were evident.

The next day, routine radiography showed widely separated sternal wires (Figure 3), indicating significant progression of sternal dehiscence. The patient subsequently underwent open reduction and internal fixation of the sternum.

■ STERNAL DEHISCENCE

Sternal dehiscence is a rare but serious complication of sternotomy.¹ In most cases of dehiscence, the sternal wires malfunction, leading to separation of sternal fragments. Lack of proper alignment of the sternum impairs bone healing, and the loose fragments of bone and wire pose a danger of puncturing the heart, making sternal dehiscence a surgical emergency.²

Physical examination may reveal tenderness to palpation, but findings that are more characteristic are an audible click and rocking of the sternum with coughing or forced chest movements.³

Plain chest radiography can clearly show early signs of sternal dehiscence; however, physicians rarely scrutinize the films for wire placement. Subtle signs include loss of sternal alignment with shifting of the segments and central sternal lucency. Gross signs start to appear when 2 or more wires are displaced; these signs are dramatic and rarely missed.

doi:10.3949/ccjm.86a.18091

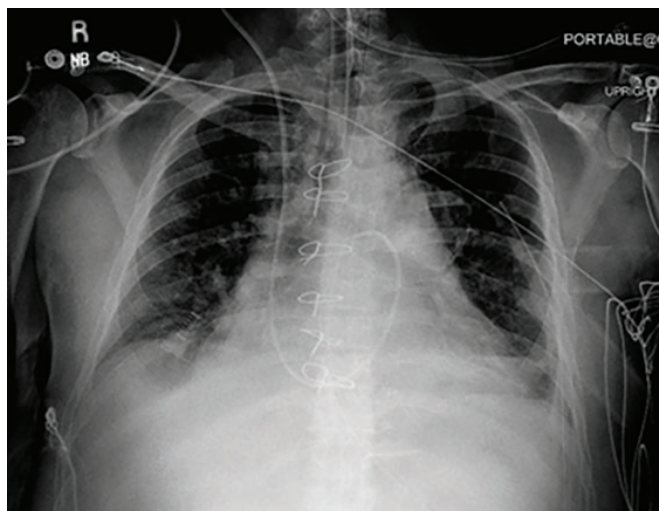


Figure 1. Radiography immediately after surgery showed cardiac tamponade, which led to repeat sternotomy with mediastinal washout.

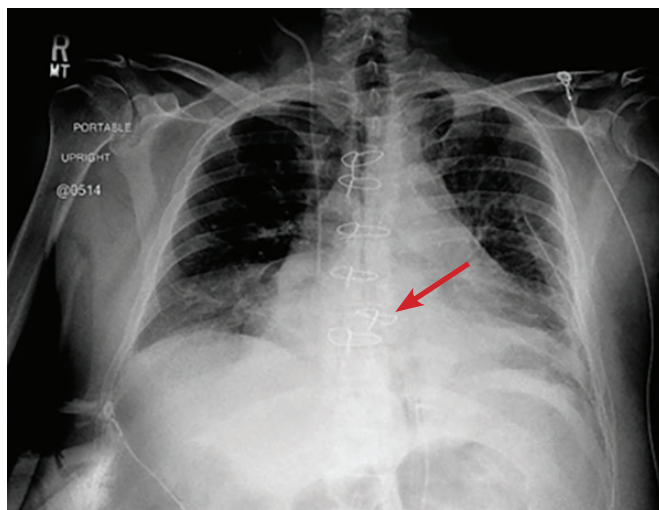


Figure 2. On postoperative day 4, midline sternal lucency and a slight leftward deviation of the second-from-the-lowest sternal wire (arrow)—early signs of dehiscence—resulted in mild loss of alignment.

STERNAL DEHISCENCE

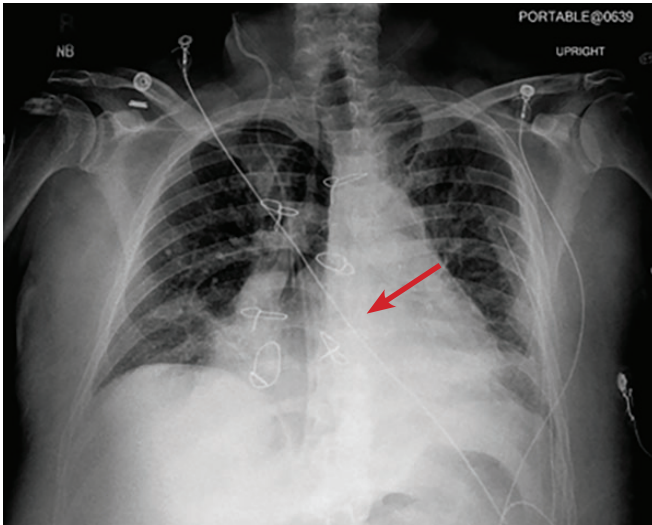


Figure 3. On postoperative day 5, the widely separated sternal wires indicated advanced sternal dehiscence.

Loss of alignment and central sternal lucency are the earliest radiographic signs of dehiscence. Awareness of early subtle signs can lead to prompt diagnosis and treatment to prevent progression to gross sternal dehiscence. ■

REFERENCES

1. **Olbrecht VA, Barreiro CJ, Bonde PN, et al.** Clinical outcomes of noninfectious sternal dehiscence after median sternotomy. *Ann Thorac Surg* 2006; 82(3):902–907. doi:10.1016/j.athoracsur.2006.04.058
2. **Efthymiou CA, Kay PH, Nair UR.** Repair of spontaneous right ventricular rupture following sternal dehiscence. A novel technique. *Interact Cardiovasc Thorac Surg* 2010; 10(1):12–13. doi:10.1510/icvts.2009.217810
3. **Santarpino G, Pfeiffer S, Concistré G, Fischlein T.** Sternal wound dehiscence from intense coughing in a cardiac surgery patient: could it be prevented? *G Chir* 2013; 34(4):112–113. PMID:23660161

ADDRESS: Amit Gupta, MD, University Hospitals Cleveland Medical Center, Case Western Reserve University, 11100 Euclid Avenue, Cleveland, OH 44106; amit.gupta@uhhospitals.org



Want to make sure you are updated on medical education that is available to you?

Need to earn continuing education credits?

Join our CME Community!

By becoming a part of the Cleveland Clinic Center for Continuing Education CME Community, you will always be on the cutting edge of educational opportunities available.



SIGN UP TODAY! CCFCME.ORG/CMEECOMMUNITY

JOIN THE
CME COMMUNITY