

SMART TESTING

MARY E. LACY, MD

Assistant Professor, Department of Internal Medicine, University of New Mexico School of Medicine, Albuquerque, NM

NAVNEET SIDHU, MD

Department Head, Hospitalist Medicine, Langley Memorial Hospital, Fraser Health, Langley, BC, Canada

JUSTIN MILLER, MD

Assistant Professor, Department of Internal Medicine, University of New Mexico School of Medicine, Albuquerque, NM



BRIEF ANSWERS
TO SPECIFIC
CLINICAL
QUESTIONS

When does acute pyelonephritis require imaging?

A PREVIOUSLY HEALTHY 44-year-old woman presents to the emergency department with 1 day of fever, flank pain, dysuria, and persistent nausea and vomiting. Her temperature is 38.7°C (101.7°F), heart rate 102 beats per minute, and blood pressure 120/70 mm Hg. She has costovertebral angle tenderness. Laboratory testing reveals mild leukocytosis and a normal serum creatinine level; urinalysis shows leukocytes, as well as leukocyte esterase and nitrites. She has no personal or family history of nephrolithiasis. Urine cultures are obtained, and she is started on intravenous antibiotics and intravenous hydration to treat pyelonephritis.

Is imaging indicated at this point? And if so, which study is recommended?

■ KEY FEATURES

Acute pyelonephritis, infection of the renal parenchyma and collecting system, most often results from an ascending infection of the lower urinary tract. It is estimated to account for 250,000 office visits and 200,000 hospital admissions each year in the United States.¹

Lower urinary tract symptoms such as urinary frequency, urgency, and dysuria accompanied by fever, nausea, vomiting, and flank pain raise suspicion for acute pyelonephritis. Flank pain is a key, nearly universal feature of upper urinary tract infection in patients without diabetes, though it may be absent in up to 50% of patients with diabetes.²

Additional findings include costovertebral angle tenderness on physical examination and leukocytosis, pyuria, and bacteriuria on laboratory studies.

■ PREDICTING THE NEED FOR EARLY IMAGING

The primary goal of imaging in acute pyelonephritis is to identify significant complications (eg, gas-forming infection, abscess formation, urinary obstruction) that may necessitate a change in management. Risk of complications is higher in patients with diabetes, compromised immunity, a recent urologic procedure, or a history of urolithiasis. Patients without these risk factors usually do not need imaging unless fever or leukocytosis persists 72 hours after the start of antibiotics. **Figure 1** offers guidance on deciding when imaging is needed in these patients.

Though guidelines state that imaging is inappropriate in most patients with pyelonephritis,²⁻⁴ it is nevertheless often done for diagnosis or identification of complications, which have been reported in more than two-thirds of patients.²⁻⁴

Acute pyelonephritis is generally classified as complicated or uncomplicated, though different definitions exist with regard to these classifications. The American College of Radiology's Appropriateness Criteria² consider patients with diabetes, immune compromise, a history of urolithiasis, or anatomic abnormality to be at highest risk for complications, and therefore recommend early imaging to assess for hydronephrosis, pyonephrosis, emphysematous pyelonephritis, and intrinsic or perinephric abscess.²

A clinical rule for predicting the need for imaging in acute pyelonephritis was developed and validated in an emergency department population in the Netherlands.³ The study suggested that restricting early imaging to patients with a history of urolithiasis, a urine

Acute pyelonephritis accounts for an estimated 250,000 office visits and 200,000 hospitalizations each year

ACUTE PYELONEPHRITIS

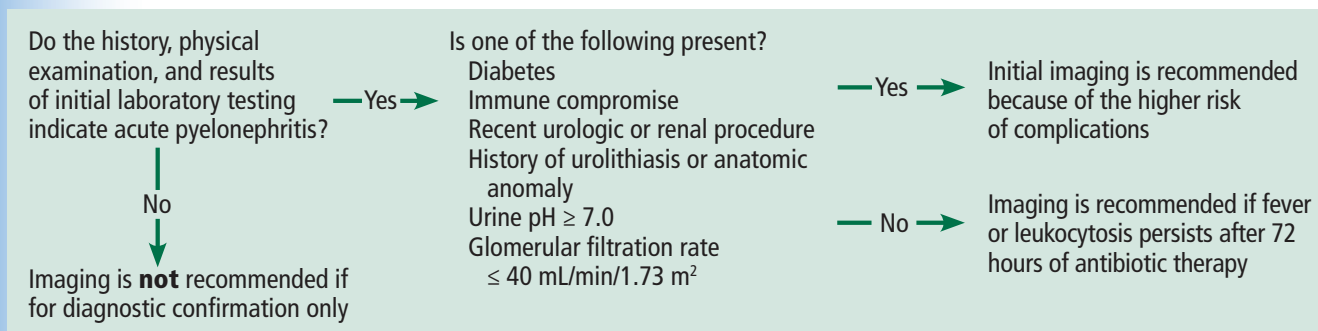


Figure 1. Pathway for considering imaging in acute pyelonephritis. The recommended imaging study is computed tomography of the abdomen and pelvis with contrast, or computed tomography without and with contrast. The choice may be tailored to the patient's clinical condition.

pH of 7.0 or higher, or renal insufficiency—defined as a glomerular filtration rate (GFR) of 40 mL/min/1.73m² or lower as estimated by the Modification of Diet in Renal Disease formula—would provide a negative predictive value of 94% to 100% for detection of an urgent urologic disorder (pyonephrosis, renal abscess, or urolithiasis). This high negative predictive value highlights that an absence of these signs and symptoms can safely identify patients who do not need renal imaging.

The positive predictive value was less useful, as only 5% to 23% of patients who had at least 1 risk factor went on to have urgent urologic risk factors.³

Implementation of this prediction rule would have resulted in a relative reduction in imaging of 40% and an absolute reduction of 28%. Of note, use of reduced GFR in this prediction rule is not clearly validated for patients with chronic kidney disease, as the previous GFR for most patients in this study was unknown.³

Based on these data, initial imaging is recommended in patients with diabetes, immune compromise, a history of urolithiasis, anatomic abnormality, a urine pH 7.0 or higher, or a GFR 40 mL/min or lower in a patient with no history of significant renal dysfunction. Early imaging would also be reasonable in patients with a complex clinical presentation, early recurrence of symptoms after treatment, clinical decompensation, or critical illness.

■ TREATMENT FAILURE

In a retrospective review of 62 patients hospitalized for acute renal infection, Soulen et al⁵ found that the most reliable indicator of

complicated acute pyelonephritis was the persistence of fever and leukocytosis at 72 hours. And another small prospective study of patients with uncomplicated pyelonephritis reported a time to defervescence of no more than 4 days.⁶

In accordance with the Appropriateness Criteria² and based on the best available evidence, imaging is recommended in all patients who remain febrile or have persistent leukocytosis after 72 hours of antibiotic therapy. In such cases, there should be high suspicion for a complication requiring treatment.

■ OPTIONS FOR IMAGING

Computed tomography

Computed tomography (CT) of the abdomen and pelvis with contrast is considered the study of choice in complicated acute pyelonephritis. CT can detect focal parenchymal abnormalities, emphysematous changes, and anatomic anomalies, and can also define the extent of disease. It can also detect perinephric fluid collections and abscesses that necessitate a change in management.^{2,5}

A retrospective study in 2017 found that contrast-enhanced CT done without the usual noncontrast and excretory phases had an accuracy of 90% to 92% for pyelonephritis and 96% to 99% for urolithiasis, suggesting that reduction in radiation exposure through use of only the contrast-enhanced phase of CT imaging may be reasonable.⁷

Magnetic resonance imaging

Magnetic resonance imaging (MRI) is increasingly acknowledged as effective in the

Computed tomography of the abdomen and pelvis with contrast is the study of choice in complicated acute pyelonephritis

evaluation of renal pathology, including the diagnosis of pyelonephritis; but it lacks the level of evidence that CT provides for detecting renal abscesses, calculi, and emphysematous pyelonephritis.^{2,8,9}

Though it is more costly and time-consuming than CT with contrast enhancement, MRI is nevertheless the imaging study of choice if iodinated contrast or ionizing radiation must be avoided.

MRI typically involves a precontrast phase and a gadolinium contrast-enhanced phase, though there are data to support diffusion-weighted MRI when exposure to gadolinium poses a risk to the patient, such as in pregnancy or renal impairment (particularly when the estimated GFR is $< 30 \text{ mL/min/1.73 m}^2$).¹⁰

Ultrasonography

Conventional ultrasonography is appealing due to its relatively low cost, its availability and portability, and the lack of radiation and contrast exposure. It is most helpful in detecting hydronephrosis and pyonephrosis rather than intrarenal or perinephric abscess.^{2,9}

Color and power Doppler ultrasonography may improve testing characteristics but not to the level of CT; in one study, sensitivity for detection of pyelonephritis was 33.3% with ultrasonography vs 81.0% with CT.¹¹

Recent studies of ultrasonography with contrast enhancement show promising results,² and it may ultimately prove to have a similar efficacy with lower risk for patients, but this has not been validated in large studies, and its availability remains limited.

Ultrasonography should be considered for patients in whom obstruction (with resulting hydronephrosis or pyonephrosis) is a primary concern, particularly when contrast exposure or radiation is contraindicated and MRI is unavailable.²

Abdominal radiography

While emphysematous pyelonephritis or a large staghorn calculus may be seen on abdominal radiography, it is not recommended for the assessment of complications in acute pyelonephritis because it lacks sensitivity.²

RETURN TO THE CASE SCENARIO

The patient in our case scenario meets the clinical criteria for uncomplicated pyelonephritis and is therefore not a candidate for imaging. Intravenous antibiotics should be started and should lead to rapid improvement in her condition. ■

ACKNOWLEDGMENT: *The authors would like to thank Dr. Lisa Blacklock for her review of the radiology section of this paper.*

REFERENCES

1. Foxman B, Klemstine KL, Brown PD. Acute pyelonephritis in US hospitals in 1997: hospitalization and in-hospital mortality. *Ann Epidemiol* 2003; 13(2):144–150. pmid:12559674
2. Expert Panel on Urologic Imaging: Nikolaidis P, Dogra VS, Goldfarb S, et al. ACR appropriateness criteria acute pyelonephritis. *J Am Coll Radiol* 2018; 15(11S):S232–S239. doi:10.1016/j.jacr.2018.09.011
3. van Nieuwkoop C, Hoppe BP, Bonten TN, et al. Predicting the need for radiologic imaging in adults with febrile urinary tract infection. *Clin Infect Dis* 2010; 51(11):1266–1272. doi:10.1086/657071
4. Kim Y, Seo MR, Kim SJ, et al. Usefulness of blood cultures and radiologic imaging studies in the management of patients with community-acquired acute pyelonephritis. *Infect Chemother* 2017; 49(1):22–30. doi:10.3947/ic.2017.49.1.22
5. Soulen MC, Fishman EK, Goldman SM, Gatewood OM. Bacterial renal infection: role of CT. *Radiology* 1989; 171(3):703–707. doi:10.1148/radiology.171.3.2655002
6. June CH, Browning MD, Smith LP, et al. Ultrasonography and computed tomography in severe urinary tract infection. *Arch Intern Med* 1985; 145(5):841–845. pmid:3888134
7. Taniguchi LS, Torres US, Souza SM, Torres LR, D'Ippolito G. Are the unenhanced and excretory CT phases necessary for the evaluation of acute pyelonephritis? *Acta Radiol* 2017; 58(5):634–640. doi:10.1177/0284185116665424
8. Rathod SB, Kumbhar SS, Nanivadekar A, Aman K. Role of diffusion-weighted MRI in acute pyelonephritis: a prospective study. *Acta Radiol* 2015; 56(2):244–249. doi:10.1177/0284185114520862
9. Stunell H, Buckley O, Feeney J, Geoghegan T, Browne RF, Torreggiani WC. Imaging of acute pyelonephritis in the adult. *Eur Radiol* 2007; 17(7):1820–1828.
10. American College of Radiology. ACR Manual on Contrast Media. www.acr.org/clinical-resources/contrast-manual. Accessed June 19, 2019.
11. Yoo JM, Koh JS, Han CH, et al. Diagnosing acute pyelonephritis with CT, Tc-DMSA SPECT, and Doppler ultrasound: a comparative study. *Korean J Urol* 2010; 51(4):260–265. doi:10.4111/kju.2010.51.4.260

ADDRESS: *Mary E. Lacy, MD, Department of Internal Medicine, University of New Mexico School of Medicine, MSC 10-550, University of NM SOM, Albuquerque, NM 87131; melacy@salud.unm.edu*