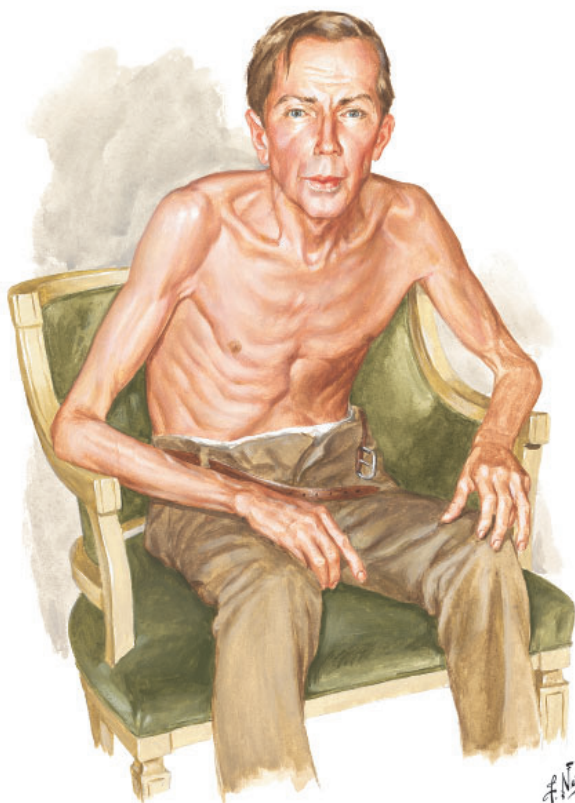


EDITORIAL

SALVATORE MANGIONE, MD

Associate Professor of Medicine and Director
History of Medicine Series, Sidney Kimmel
Medical College at Thomas Jefferson University,
Philadelphia, PA

You can observe a lot by watching



Netter illustration from www.netterimages.com. © Elsevier Inc. All rights reserved.

Figure 1. The Pink Puffer.

“I have trained myself to see what others overlook.”
—Sherlock Holmes¹

THE ARTICLE BY Grandjean and Huber in this issue² is a timely reminder of the importance of skilled observation in medical care. Osler³ considered observation to represent “the whole art of medicine,” but warned that “for some men it is quite as difficult to

“You can observe a lot by watching” are words yelled in 1964 by New York Yankees’ manager Yogi Berra to his players, who were not paying attention to the game (Berra Y. *The Yogi Book*. New York, NY: Workman Publishing Company, 1998).

doi:10.3949/ccjm.86a.19056

record an observation in brief and plain language.” This insight captures not only the never-ending feud between written and visual communication, but also the higher efficiency of images. Leonardo da Vinci, a visual thinker with a touch of dyslexia,⁴ often boasted in colorful terms about the superiority of the visual. Next to his amazing rendition of a bovine heart he scribbled, “[Writer] how could you describe this heart in words without filling a whole book? So, don’t bother with words unless you are speaking to the blind...you will always be overruled by the painter.”⁵

See related article, page 439, and editorial, page 443

Ironically, physicians have often preferred the written over the visual. Oliver Wendell Holmes Sr., professor of anatomy at Harvard Medical School and renowned essayist, once wrote a scathing review of a new anatomy textbook that, according to him, had just too many pictures. “Let a student have illustrations,” he thundered “and just so surely will he use them at the expense of the text.”⁶ The book was *Gray’s Anatomy*, but Holmes’ tirade exemplifies the conundrum of our profession: to become physicians we must read (and memorize) lots of written text, with little emphasis on how much more efficiently information might be conveyed through a single picture.

This trend is probably worsening. When I first came to the United States 43 years ago, I was amazed at how many of my professors immediately grabbed a sheet of paper and started drawing their explanations to my questions. But I have not seen much of this lately, and that is a pity, since pictures are undoubtedly a better way of communicating.

■ OBSERVING A PATIENT WITH COPD

Take for example *The Pink Puffer* (Figure 1), a picture that Frank Netter created in the 1970s. If we force ourselves to pay attention to detail, this image discloses a treasure trove of evidence-based clinical information. First, the patient is shown in tripod position. This sitting up, leaning-forward “thinker” posture not only accounts for the Dahl’s sign discussed by Grandjean and Huber, but also relieves dyspnea by maximizing inspiratory pressures.⁷ It also lifts the shoulder girdle, thus improving the action of both pectoralis major and minor.⁸

Netter’s patient is also exhaling through pursed lips. This reduces the respiratory rate and carbon dioxide level, while improving distribution of ventilation,^{9,10} oxygen saturation, tidal volume, inspiratory muscle strength, and diaphragmatic efficiency.^{11,12} Since less inspiratory force is required for each breath, dyspnea is also improved.^{13,14} Diagnostically, pursed-lip breathing increases the probability of chronic obstructive pulmonary disease (COPD), with a likelihood ratio of 5.05.¹⁵

The man in *The Pink Puffer* is using accessory respiratory muscles, which not only represents one of the earliest signs of airway obstruction, but also reflects severe disease. In fact, use of accessory respiratory muscles occurs in more than 90% of COPD patients admitted for acute exacerbations.⁷

Lastly, Netter’s patient exhibits inspiratory retraction of supraclavicular fossae and interspaces (tirage), which indicates increased airway resistance and reduced forced expiratory volume in 1 second (FEV₁).^{16,17} A clavicular “lift” of more than 5 mm correlates with an FEV₁ of 0.6 L.¹⁸

But what is odd about this patient is what Netter did not portray: clubbing. This goes against the conventional wisdom of the time but is actually correct, since we now know that clubbing is more a feature of chronic bronchitis than emphysema.¹⁹ In fact, if present in a “pink puffer,” it should suggest an underlying malignancy. Hence, Netter reminds us that we should never convince ourselves that we see something simply because we know it should be there. Instead, we should always rely on what we see. This is, after all, how Vesalius debunked Galen’s anatomic errors: by seeing

for himself. Tom McCrae, Osler’s right-hand man at Johns Hopkins, used to warn his students that one misses more by not seeing than by not knowing. Leonardo put it simply: “Wisdom is the daughter of [visual] experience.”²⁰ In the end, Netter’s drawing reminds us that a picture is truly worth a thousand words.

■ TEACHING STUDENTS TO OBSERVE

Unfortunately, detecting detail is difficult. It is also very difficult to teach. For the past few months I’ve been asking astute clinicians how they observe, and most of them seem befuddled, as if I had asked which muscles they contract in order to walk. They just walk. And they just observe.

So, how can we rekindle this important but underappreciated component of the physician’s skill set? First of all, by becoming cognizant of its fundamental role in medicine. Second, by accepting that this is something that cannot be easily tested by single-best-answer, black-and-white, multiple-choice exams. Recognizing the complexity of clinical skills reminds us that not all that counts in medicine can be counted, and not all that can be counted counts. Yet it also provides a hurdle, since testing typically drives curriculum. If we cannot assess observation, how can we reincorporate it in the curriculum? Lastly, we need to regain ownership of the teaching of this skill. No art instructor can properly identify and interpret clinical findings. Hence, physicians ought to teach it. In the end, learning how to properly observe is a personal and lifelong effort. As Osler put it, “There is no more difficult art to acquire than the art of observation.”²¹

Leonardo used to quip that “There are three classes of people: those who see, those who see when they are shown, and those who do not see.”²² Yet this time Leonardo might have been wrong. There are really only two kinds of people: those who have been taught how to observe and those who have not. Leonardo was lucky enough to have been apprenticed to an artist whose nickname was Verrocchio, which resembles the Italian words *vero occhio*, a “fine eye.” Without Verrocchio, even Leonardo might not have become such a skilled observer. How many Verrocchios are around today? ■

Learning to properly observe is a personal, lifelong effort

REFERENCES

1. Doyle AC. A case of identity. In: The Adventures of Sherlock Holmes. London, UK: George Newnes; 1892.
2. Grandjean R, Huber LC. Thinker's sign. *Cleve Clin J Med* 2019; 86(7):439. doi:10.3949/ccjm.86a.19036
3. Osler W. The natural method of teaching the subject of medicine. *JAMA* 1901; 36(24):1673–1679. doi:10.1001/jama.1901.52470240001001
4. Mangione S, Del Maestro R. Was Leonardo da Vinci dyslexic? *Am J Med* 2019 Mar 7; pii:S0002-9343(19)30214-1. Epub ahead of print. doi:10.1016/j.amjmed.2019.02.019
5. Leonardo Da Vinci. Studies of the Heart of an Ox, Great Vessels and Bronchial Tree (c. 1513); pen and ink on blue paper, Windsor, London, UK Royal Library (19071r).
6. Holmes OW Sr. Gray's Anatomy. The Boston Medical and Surgical Journal 1859; 60(25):489–496.
7. O'Neill S, McCarthy DS. Postural relief of dyspnoea in severe chronic airflow limitation: relationship to respiratory muscle strength. *Thorax* 1983; 38(8):595–600. PMID:6612651
8. Banzett RB, Topulos GP, Leith DE, Nations CS. Bracing arms increases the capacity for sustained hyperpnea. *Am Rev Respir Dis* 1988; 138(1):106–109. doi:10.1164/ajrccm/138.1.106
9. Mueller RE, Petty TL, Filley GF. Ventilation and arterial blood gas changes induced by pursed lips breathing. *J Appl Physiol* 1970; 28(6):784–789. doi:10.1152/jappl.1970.28.6.784
10. Thoman RL, Stoker GL, Ross JC. The efficacy of pursed-lips breathing in patients with chronic obstructive pulmonary disease. *Am Rev Respir Dis* 1966; 93(1):100–106.
11. Breslin EH. The pattern of respiratory muscle recruitment during pursed-lip breathing. *Chest* 1992; 101(1):75–78. PMID:1729114
12. Jones AY, Dean E, Chow CC. Comparison of the oxygen cost of breathing exercises and spontaneous breathing in patients with stable chronic obstructive pulmonary disease. *Phys Ther* 2003; 83(5):424–431. PMID:12718708
13. el-Manshawi A, Killian KJ, Summers E, Jones NL. Breathlessness during exercise with and without resistive loading. *J Appl Physiol* (1985) 1986; 61(3):896–905. doi:10.1152/jappl.1986.61.3.896
14. Nield MA, Soo Hoo GW, Roper JM, Santiago S. Efficacy of pursed-lips breathing: a breathing pattern retraining strategy for dyspnea reduction. *J Cardiopulm Rehabil Prev* 2007; 27(4):237–244. doi:10.1097/01.HCR.0000281770.82652.cb
15. Mattos WL, Signori LG, Borges FK, Bergamin JA, Machado V. Accuracy of clinical examination findings in the diagnosis of COPD. *J Bras Pneumol* 2009; 35(5):404–408. PMID:19547847
16. Stubbing DG. Physical signs in the evaluation of patients with chronic obstructive pulmonary disease. *Pract Cardiol* 1984;10:114–120.
17. Godfrey S, Edwards RH, Campbell EJ, Newton-Howes J. Clinical and physiological associations of some physical signs observed in patients with chronic airways obstruction. *Thorax* 1970; 25(3):285–287. PMID:5452279
18. Anderson CL, Shankar PS, Scott JH. Physiological significance of sternomastoid muscle contraction in chronic obstructive pulmonary disease. *Respir Care* 1980; 25(9):937–939.
19. Myers KA, Farquhar DR. The rational clinical examination. Does this patient have clubbing? *JAMA* 2001; 286(3):341–347. PMID:11466101
20. Richter JP. The Notebooks of Leonardo Da Vinci. New York: Dover Books; 1970.
21. Osler W. On the educational value of the medical society. *Yale Medical Journal* 1903; 9(10):325.
22. Goodreads. Leonardo da Vinci Quotable Quote. <http://www.goodreads.com/quotes/243423-there-are-three-classes-of-people-those-whosee-those>. Accessed April 15, 2019.

ADDRESS: Salvatore Mangione, MD, Sidney Kimmel Medical College at Thomas Jefferson University, Hamilton Building, Suite 309C, 1001 Locust Street, Philadelphia, PA 19107; salvatore.mangione@jefferson.edu

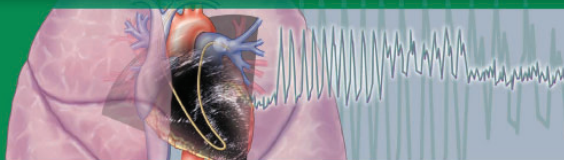


Pulmonary Hypertension Summit 2019

November 7-8, 2019

- ▶ InterContinental Hotel and Bank of America Conference Center Cleveland, OH
- ▶ Sonesta Fort Lauderdale Fort Lauderdale, FL

TWO LOCATIONS!
Choose the best for you



Register Today! www.cfcme.org/PH2019

ABIM Earn MOC Points

The Summit will provide you with an overview of the practical issues in the diagnosis, evaluation, and management of patients with pulmonary hypertension. The Summit will synthesize the World Symposia on Pulmonary Hypertension proceedings. Expert speakers will present the most recent advances in the context of challenges faced by physicians and other health care providers caring for these patients.

Key Features

- Learn from shared experts broadcast between two locations – Cleveland, OH and Fort Lauderdale, FL
- Expand and enhance decision-making skills in highly complex clinical situations through case discussions
- Increase your confidence to devise and implement effective treatment plans for patients
- Learn available combination therapies and how to incorporate them into patient care strategies
- New this year in Cleveland - optional pulmonary hypertension clinical immersion hands on workshop
- Live online stream available for those who can't attend in person

This activity has been approved for AMA PRA Category 1 Credit™.