Surgical techniques for relief from seizures[1]

Joseph F. Hahn, M.D.
Margot Sellers

Surgery for the relief of seizures is a well-known technique since the early 1930s; however, only approximately 250 procedures are done for the relief of epilepsy each year. Various techniques have been developed which include hemispherectomy, stereotactic ablations, corticectomy and lobectomy, most often of the temporal lobe and a section of the corpus callosum. Recent advances have been in the development of techniques to isolate the seizure focus and thereby enhance its definition for surgery. The authors present their format for this, and show examples of subdural electrodes in place. An analysis of the data is included.

Index terms: Epilepsy, surgery · Seizures
Cleve Clin Q 51:307–311, Summer1984

Surgery for the relief of seizures is not a new technique. Early in the 1930s, surgeons at institutions such as the Montreal Neurological Institute were doing various surgical maneuvers to relieve epilepsy. What has progressed is the ability to define the area of concern. In the past, a great deal of emphasis was placed on scalp recordings. Various techniques were added to increase the ability to determine the exact area of the seizure focus. Such things as sphenoidal electrodes, nasopharyngeal electrodes, photic stimulation, hyperventilation, sleep deprivation, etc, were added to help define the limits of the epileptogenic area. We have devised a technique which we believe outlines the focus as well as the important structural areas to be avoided. The purpose of this paper is to describe this technique as well as to discuss some of the surgical interventions that are applied.

[1] Department of Neurosurgery, The Cleveland Clinic Foundation. Submitted for publication and accepted Oct 1983.

0009-8787/84/02/0307/05/$2.25/0

Copyright © 1984, The Cleveland Clinic Foundation.

Who is a candidate for epilepsy surgery is beyond the scope of this paper. The reader is referred to the previous paper in the *Cleveland Clinic Quarterly*, concerning the role of surgery in epilepsy.[1]

Preoperative evaluation

After the patient has been evaluated by the clinical neurophysiology team and deemed an appropriate candidate, he is admitted to the hospital for the insertion of subdural electrodes (*Figure*). These are manufactured for the individual patient in the biomedical engineering department. The electrodes are 1.5-mm discs, which are imbedded in Silastic and the wiring passed through a Silastic cable, which crosses the dura, the bone, and the scalp. This plate can be made in any array, but the usual number of electrodes is 64 in an 8 × 8-cm pattern. We have made them larger and smaller. The plate can be tailored at surgery to cover the area of brain which is thought to be epileptogenic. It is made quite large so that a large area of brain can be covered and the boundaries determined more easily. The patient then undergoes a two-week intensive period of both recording and stimulation.

The recording phase consists of the patient being tapered off his anti-seizure medications and an attempt made to record a minimum of three seizures. These are spontaneously occurring seizures.

The other week is devoted to stimulation, at which time, using various currents through each electrode, maps are made of both the sensory and motor area. Using this type of technique, we are able to quite specifically localize such important functions as speech, mouth movement, finger movement, etc. We have used this as a "road map" to guide us in our area of resection. This has been quite efficacious in allowing us to do a rather large resection in areas of the brain which were thought to be important for function. As the technique has evolved, we have learned more about the anatomy and its various diversifications.

These electrodes are left in place for periods up to as long as 36 days. The patient is not confined to the hospital bed and/or EEG machine. At the present time we have done this on 44 patients. Early in our series, cerebrospinal fluid leakage along the cable lines was an almost universal problem. This has been eliminated by making a watertight closure of the dura and putting several purse strings around each cable where they exit the dura and scalp.

We have had two episodes of a wound infection with extension into the intracranial cavity along the cable. One occurred at a time when we were completing a randomized study on the use of intraoperative antibiotics, and the patient was receiving a placebo.

A second case has recently occurred: a patient in whom a second craniotomy was done to move the plate more posteriorly developed meningitis.

A third complication is that the size of the plate may produce a mass effect which then causes a shift of the brain and a deterioration of the neurologic condition of the patient. This has happened on two occasions, necessitating removal of the plate. This occurred at a time when the plate was made of hard Silastic and was not malleable. The sheer bulk produced a shift and therefore created the problems. This has been alleviated by making a much more flexible plate and by tailoring the number of electrodes to the actual area of the brain to be covered.

A fourth problem which has evolved is the interaction of various anti-epileptic drugs with steroids, cimetidine (Tagamet), and some antibiotics. We have had approximately seven cases in which the patient did well in the first 24 hours only to become lethargic over the second postoperative day. Emergency scans and evaluation were unrevealing and each has had a dramatic increase in the serum anti-epileptic drug level. This was thought to be due to interactions of the various drugs which the patient had been taking. At the present time, we have an ongoing prospective study to try and elucidate more clearly some of these interactions. We wish to alert clinicians dealing with patients in the immediate postoperative period who are on anti-epileptic drugs to be aware of this. Preliminary evaluation of the data suggests an interaction with cefamandole nafate (Mandol) as a probable course.

Surgical techniques

Once the patient has completed the evaluation phase, the patient is then prepared for surgery. The clinical neurophysiology team meets and discusses the best approach to each patient. There are several different types of surgical procedures that can be performed.

Hemispherectomy is a procedure that is not used frequently. It is an effective way to eradicate the seizure focus, but patients who are candidates for this surgery are those with infantile hemiplegia and a focal seizure disorder in the hemisphere that relates to the hemiplegia. The success rate

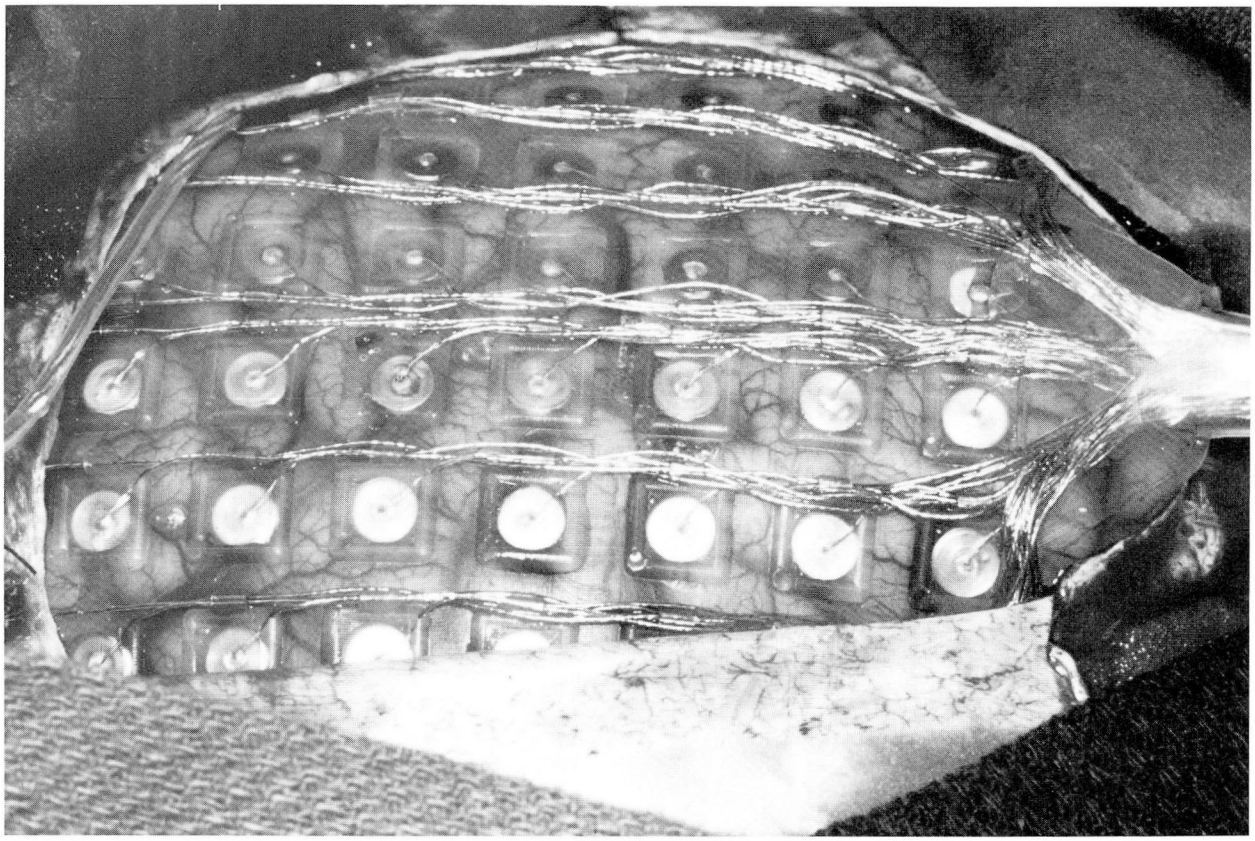

Figure Subdural electrodes

in alleviating seizures is in the neighborhood of 88%. There are some disadvantages to this technique, the most notable being that if the patient is only hemiparetic, his neurologic deficit can be made much worse.

The technique itself consists of removing essentially the cortex down to the level of the ventricles in its entirety. Originally, the hemisphere was removed totally. This produced complications, most notably cerebral hemosiderosis. The concept of cerebral hemosiderosis is that repeated small hemorrhages in the area of resection cause deposition of iron pigment which produces a chemical reaction. This can result in signs and symptoms suggestive of a brain neoplasm. In order to circumvent this problem, an attempt is made to leave as much brain as possible. Therefore, both the frontal and occipital lobe may be left in place.

If the ventricle is entered, hydrocephalus and ependymitis may result. *Stereotactic amygdalotomy* is another rare technique used for control of epilepsy. There has been no large series reported in the literature of patients having this procedure. Therefore, it makes it difficult to determine who is an ideal candidate. A series including 29 patients was reported by Narabayashi.[2] Each of the patients reported had severe behavioral problems as well as epilepsy. These problems included uncontrollable violent explosions of temper, easy excitability, or unsteadiness in mood and emotional lability.

The technique itself consists of inserting a probe percutaneously through the squamous portion of the temporal bone into the amygdala. The target is determined by filling the ventricular system with a material that will outline the ventricles on radiographs. In the past, this had been air, but more recently has been metrizamide. Using computed tomography (CT), all contrast agents can be eliminated. It is possible to direct the probe using CT guidance. Once the temporal horn is visualized using measurements, as outlined by Talairich and Szikla,[3] the amygdala and hippocampal gyri can be located. This can be done to a rather precise point and the number of millimeters from the inner table of the skull calculated. The probe is then inserted using a stereotactic apparatus into this focus. Using a cyroprobe, the amygdala is then destroyed.

There is relatively little danger and by using correct timing methods there is little chance of destruction involving the hippocampus.

In the work presented by Narabayashi,[2] data are detailed on only 18 patients. Eighteen were thought to be essentially cured and able to return to work. There were no complications and no adverse psychological, intellectual, or autonomic side effects noted. There was no evidence of loss of memory function or evidence of the Kluver-Bucy syndrome. (Penfield and Mathieson[4] have shown that memory function is not related to the amygdaloid nucleus.) The only noticeable side effects following stereotactic amygdalectomy were a transient inertia shortly after surgery which lasted for several days and a transient tendency for an increase in appetite which lasted approximately two weeks in about one third of the cases.[2]

Cerebellar stimulation was at one time proposed for the control of intractable epilepsy. This technique has now been abandoned as it apparently does not provide as much benefit as was originally thought.

Section of the corpus callosum has been proposed for seizures that have a bilateral focus or the focus is inaccessible. The obvious rationale for this type of approach is to prevent the spread from one hemisphere to the other. The technique itself includes a section of the corpus callosum in its entirety as well as the anterior commissure and one fornix. The procedure requires that the surgeon identify the cingulate gyrus and the anterior cerebral arteries. Problems have arisen when the cingulate gyrus is mistaken for the corpus callosum and a portion of it removed. The corpus callosum has virtually no blood vessels within it; therefore, it looks white as compared to the cingulate gyrus. Secondly, the anterior cerebral arteries must be identified and swept to one side or the other. The approach is from above between the hemispheres; therefore, one will be looking directly down on top of these arteries. With gentle retraction, they can be moved to the right or the left, but it is not wise to split them. The callosum itself can be sectioned quickly as there are no major blood vessels to contend with. In the literature, it has been suggested that the ependyma be left intact. Even using the microscope, this could be a difficult endeavor. The complications noted when the ventricular system has been violated have been both aseptic ventriculitis and/or hydrocephalus.

An acute disconnection syndrome occurs in almost all patients. The syndrome is characterized by mutism, bilateral grasp reflexes, bilateral Babinski responses, and focal motor seizures on alternating sides without loss of consciousness. Confusion, lack of concentration, and memory deficits, as well as regression to childish behavior, may also occur. This has gradually resolved in all of our patients and has not been a long-term problem. Wilson et al[5] have reported one of the most recent articles on corpus callosum section for seizure surgery. This series consisted of 12 patients, of whom 8 were analyzed in depth. Six were reported to be improved, 1 required a nursing home, and there was 1 death. However, a follow-up more recently within the last year has reported a second death and a relapse of some of the previously reported patients (Wilson, personal communication). A more recent paper coming from the neuro-psychology department will update the long-term results.

The final technique of seizure surgery includes both *corticectomy* and *temporal lobectomy*. Corticectomy includes resection of a part of the cerebral cortex. This may be accomplished in any of the lobes, but we have done corticectomy in both the frontal and occipital lobes. The technique itself consists of undermining the cortex down to the level of the white matter and undercutting it for the extent of the epileptic focus. The patients who have had this done in the frontal area have had a successful result. One of the 2 patients who have had this type of procedure in the occiptal area has been a failure; this patient had hemicortical atrophy and multifocal interictal epileptiform discharges, but all seizures preoperatively had been of occipital origin.

Temporal corticectomy has also been performed, but the most standard approach is a temporal lobectomy. Using the techniques we have perfected, we are able to outline important neuroanatomic areas and avoid them. This has allowed us to make rather generous resections of up to 8.5 to 9 cm on the left temporal lobe as well as 10 to 12 cm on the right temporal lobe. The resection itself is carried laterally to medially, and en block resection is done through the temporal horn and involves the mesial structures. We have removed the hippocampus and amygdala and uncus in the en block resection. A side issue is that this has been quite helpful in evaluating the temporal lobe in the neuropathology department. Secondly, it has confirmed a finding previously noted by the Montreal group, namely that the success rate for seizure reduction is higher if, in fact, the mesial structures are removed. One of our failures was due to the fact

that we left the mesial structures in place. During a second operation, it was determined that a mesial focus was still present.

In the series on cortical resection as discussed by Rasmussen,[6] there were organic lesions accounting for 20% of the patients in the operated group. In patients who did not have tumors and/or arteriovenous malformations, 27% were thought to be due to brain swelling or gliosis as a result of birth trauma, and 15% due to postinflammatory brain scarring.

In the series of patients that were evaluated postoperatively, an attack was defined as one that interfered with the patient's contact with his environment or one that was visible to an observer. This included 1,407 patients with medically refractory epilepsy caused by nontumoral lesions. There was satisfactory follow-up data in excess of two years' duration for approximately 1,300 of these patients. Nineteen per cent had no seizures since discharge from the hospital, 14% became seizure-free shortly after having a few attacks for a combination of 33% who have remained seizure-free after surgery. One hundred sixty-eight patients (13%) have had late recurrence of occasional attacks after having been seizure-free for periods ranging from three to 25 years. Two hundred forty patients (19%) have had less than 1% to 2% as many attacks compared to the preoperative state.These two groups comprising 408 patients make up 32% of the follow-up group and are considered to have experienced a marked reduction in seizure frequency. Therefore, 65% of medically refractory patients with epilepsy have benefited from the surgical procedure.

According to Rasmussen, the remaining one third have had a lesser reduction of seizure frequency. Some of these have had only 5% to 10% as many attacks compared to the preoperative rate.

In this large series of 1,400 patients, 131 required reoperation a second time and occasionally a third and fourth time. In 45% of those patients reoperated on, the reoperation was sufficient to put them in the "good-result" category.

Review of Cleveland Clinic cases

Analysis of our own series revealed 45 patients (1 patient was done twice) (16 females and 28 males). The seizure durations ranged from 1½ to 33 years. Twelve patients were known to have underlying pathology prior to surgery. These included an arachnoid cyst, primary brain tumors, and arteriovenous malformations.

The most common procedure was a temporal lobectomy. However, six procedures were done on the frontal lobe, two on the occipital, and two on the parietal. Most of the latter procedures were for epileptic foci in association with parenchymal lesions. Of those done in the parietal region, one was associated with a tumor, and this patient has been seizure-free since the surgery. Of those located in the frontal region, three out of six were associated with tumor. Five have had a successful result. Of those located in the occipital region, one was associated with hemicortical atrophy, and seizures were not controlled by the occipital resection.

In the analysis of our surgical cases, we have 29 that are rated very good, meaning they have either no seizures or only one to two per year. We have 3 patients that have a significant reduction in seizure frequency, are of an altered duration and are not as severe. These in all likelihood should be included with the previous 29. Therefore, we have 76% of our patients in what Rasmussen describes as groups 1 and 2.

There are 6 patients who have a decrease in their seizure frequency, but not as dramatically as the first two groups; however, all of these patients have returned to their daily activities and report being "happy" with results. There are five in whom there is no change recorded. These are patients who have parenchymal lesions (either neoplasms or hemicortical atrophy). Converting these figures to percentages, we have a 76% success rate. We have an 11% no-change rate, with the remainder being rated as changed, but certainly not significantly enough to allow them to return to a completely normal lifestyle.

References

1. Hahn JF. The role of surgery in epilepsy. Cleve Clin Q 1983; **50**:353–359.
2. Narabayashi H. Long-range results of medial amygdalotomy on epileptic traits in adult patients. [In] Rasmussen T, Marino R Jr, eds. Functional Neurosurgery. New York, Raven Press, 1979, pp 243–252.
3. Talairach J, Szikla G. Stereotactic neuroradiological concepts applied to surgical removal of cortical epileptogenic areas. [In] Rasmussen T, Marino R Jr, eds. Functional Neurosurgery. New York, Raven Press, 1979, pp 219–242.
4. Penfield W, Mathieson G. Memory. Autopsy findings and comments on the role of hippocampus in experimental recall. Arch Neurol 1974; **31**:145–154.
5. Wilson DH, Reeves A, Gazzaniga M, Culver C. Cerebral commissurotomy for control of intractable seizures. Neurology 1977; **27**:708–715.
6. Rasmussen T. Cortical resection for medically refractory focal epilepsy. [In] Rasmussen T, Marino R Jr, eds. Functional Neurosurgery. New York, Raven Press, 1979, pp 253–269.