Local hypothermia in the treatment of spinal cord injuries

Report of seven cases

Dexter D. Koons, M.D.*
Philip L. Gildenberg, M.D., Ph.D.†
Donald F. Dohn, M.D.
Malcolm Henoch, B.A.

Department of Neurological Surgery

In 1968 Albin et al[1] reported on the beneficial effects of spinal cord cooling as a treatment of spinal cord injury in experimental animals. Two groups of rhesus monkeys received identical spinal cord injuries, and 4 hours after injury one of the groups was treated by irrigating the traumatized cords with cold saline solution. The recovery in this group was dramatic when compared with the control group, in which virtually no recovery took place. The clinical application of this method was advised for the treatment of spinal cord injuries.

We have had the opportunity to treat seven patients with local hypothermia. Five patients had been in accidents, and signs of cord damage after operations for other conditions had developed in two patients.

Case reports

Case 1. A 13-year-old girl was admitted by the orthopaedic service for surgical correction of congenital idiopathic scoliosis (*Fig. 1*). Neurological examination was normal. A myelogram demonstrated a congenital bar on the right side in the T-4 to T-6 area (*Fig. 2*).

* *Fellow, Department of Neurological Surgery.*
† Present address: University of Arizona Medical Center, Tucson, Arizona 85724.

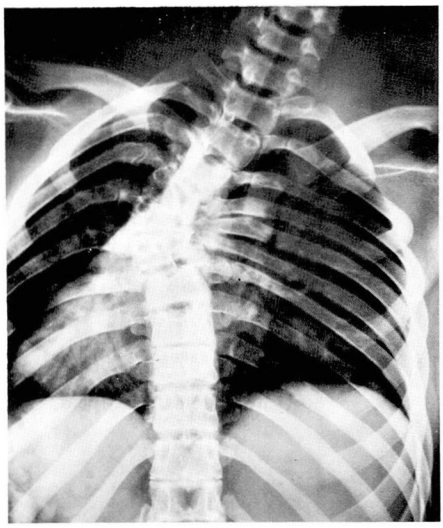

Fig. 1. Case 1. X-ray film showing severe scoliosis of the thoracic spine.

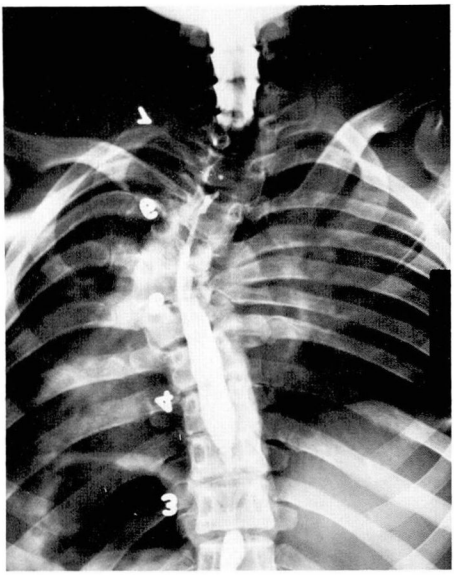

Fig. 2. Myelogram of same area as in *Figure 1* (numerals do not indicate vertebral level).

A Risser cast was applied, and 4 days later Harrington rods were inserted. The bar demonstrated on the myelogram was interrupted by an osteotomy, and a bone graft was done from T-3 to T-7. The patient became paraplegic postoperatively. The wound was reopened, and a large epidural hematoma was found. A decompressive laminectomy was performed, and the bone graft and Harrington rods were removed. Partial improvement occurred, but no further progress was observed after the 14th postoperative day. A second myelogram showed a complete block at T-6 (*Fig. 3*).

A third operation was performed which revealed that the cord was compressed by angulation of the spine and by epidural fibrous material. This material was removed, and the concave side of the curvature was unroofed. There was transient improvement, but deterioration was noted on the second postoperative day, and the patient underwent a fourth operation. Epidural material was again removed, and

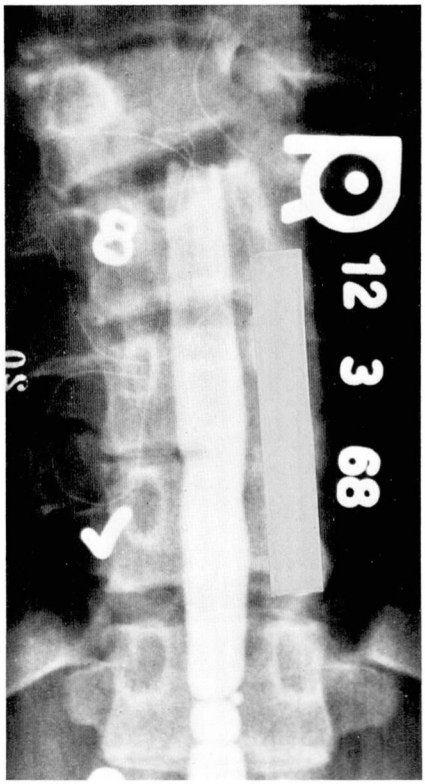

Fig. 3. Second myelogram of Case 1 showing complete block to flow of pantopaque at T-6 (numerals do not indicate vertebral level).

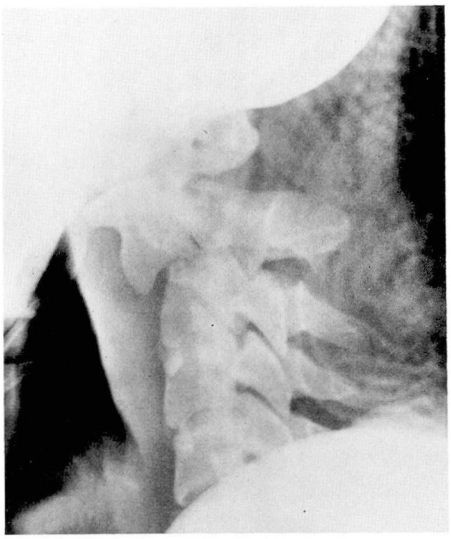

Fig. 4. Case 2. Fracture dislocation of C-2 on C-3.

the dura was opened. The cord appeared grossly normal. The cord was irrigated for 30 minutes with cold Ringer solution and saline slush. The dura was then closed with a silastic graft.

There was immediate improvement postoperatively. Seven months after spinal cord cooling, the patient was capable of independent ambulation. She had normal motor and sensory function of the left leg, but a spastic weakness and a mild sensory loss in the right leg. A Risser cast was applied and the scoliosis improved somewhat.

Case 2. A 20-year-old man sustained a fracture dislocation of C-2 on C-3 (*Fig. 4*), when a dumbwaiter fell on his neck as he was looking down an elevator shaft. He was immediately quadriplegic and in respiratory distress. At a local hospital Crutchfield tongs were inserted, and he was given respirator assistance.

He was transferred to Cleveland Clinic Hospital and was found to be completely quadriplegic with anesthesia below C-4. He was immediately taken to surgery, which was approximately 7 hours after the injury. A decompressive laminectomy of C-2 to C-4 was performed. The dura was opened and the cord looked normal. The cord was cooled with saline slush for 30 minutes, after which the dura was closed primarily.

The patient was able to move all extremities as soon as he recovered from anesthesia, and this improvement continued. His hospital course was complicated by hemorrhage from a gastric ulcer which necessitated laparotomy. An anterior interbody fusion of C-2 to C-3 was ultimately done. When seen 15 months later, he had a spastic left hemiparesis with normal strength of his right extremities. He is capable of independent ambulation, with the aid of a cane.

Case 3. A 21-year-old man was quadriparetic as the result of a fracture dislocation of C-4 on C-5 (*Fig. 5*) caused by a diving injury. On admission it was noted that he had minimal motion in his upper extremities, which were weaker than the lower extremities.

An operation was performed 3 hours after injury, consisting of insertion of Crutchfield tongs, tracheostomy, and decompressive laminectomy from C-3 to C-6. The dura bulged posteriorly, and when opened, dark venous blood gushed from beneath the dura. The cord, which ap-

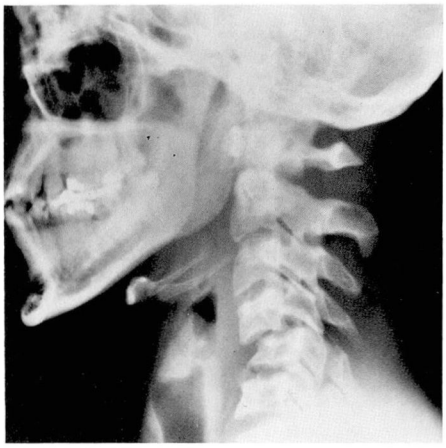

Fig. 5. Case 3. Fracture dislocation of C-4 on C-5.

Fig. 6. Case 4. Compression fractures of T-11 and T-12 with dislocation of T-11 on T-12.

peared normal, was irrigated with iced Ringer solution for 30 minutes; the dura was left open.

Postoperative improvement was gradual but progressive. An anterior fusion from C-3 to C-6 was performed 6 weeks after operation. The only neurological deficit 7 months after injury was weakness of the intrinsic muscles of the right hand.

Case 4. A 15-year-old boy fell 30 feet from a tree and became immediately paraplegic. Roentgenograms demonstrated fractures of T-11 and T-12 (*Fig. 6*). The paraplegia was complete with anesthesia below T-11. The patient was taken to surgery 5 hours after injury where a decompressive laminectomy of T-10 to T-12 was done. The dura was opened, and the cord was found to be completely disrupted on the left side, with the remainder diffusely ecchymotic. The cord was cooled for 30 minutes with saline slush, and the dura was closed with a silastic graft. Two months later the patient had not recovered any function.

Case 5. A 23-year-old woman sustained fractures of T-5 and T-6 in an automobile accident (*Fig. 7*). Findings on physical examination disclosed total flaccid paraplegia and anesthesia below T-5. She underwent operation 6 hours after injury, at which time a decompressive laminectomy of T-5 to T-8 was performed. The dura was opened and the cord looked normal. The cord was irrigated for 30 minutes using a Swenko Hypothermostat at 12 C. The dura was closed with a silastic graft. Two years later the patient had not recovered any function.

Case 6. A 45-year-old woman was admitted to the hospital with a 5-year history of progressive weakness of her right hand and both legs. On examination there was atrophy of the intrinsic muscles of her right hand and spastic paraparesis. Plain roentgenograms of her spine were normal. A myelogram disclosed an extradural defect at C-6 to C-7 (*Fig. 8*). A right hemilaminectomy was done, and a round, firm, extradural mass at C-6 was easily removed. The pathologic findings indicated that this mass was an "osteophyte."

Postoperatively she was completely para-

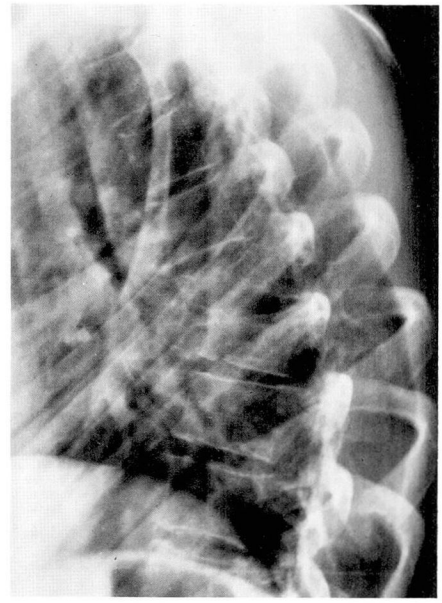

Fig. 7. Case 5. Compression fracture of T-5 and T-6 with dislocation of T-5 on T-6.

Fig. 8. Case 6. Myelogram showing extradural defect at C-6 and C-7.

plegic. She was returned to surgery for a complete laminectomy of C-5 to C-6. The dura was opened, and the cord was noted to be ecchymotic on the right side. On the left side the dura was posteriorly displaced, and a soft disc protrusion was removed through a transdural incision. The cord was then cooled with iced saline solution for 30 minutes, and the dura was closed primarily. The patient had not recovered any function 1 month later.

Case 7. A 24-year-old man sustained fractures of T-2 to T-4 in an automobile accident (*Fig. 9*). Findings on physical examination disclosed complete flaccid paraplegia with anesthesia below T-5. The patient was taken to surgery 4 hours after the injury. A decompressive laminectomy of T-2 to T-4 was performed; the dura was opened, and the cord was observed to be ecchymotic at the T-3 to T-4 level. The cord was cooled with iced saline for 40 minutes, after which the dura was closed with a silastic graft. At follow-up 1 month later, the patient had not recovered any function.

Technique of local hypothermia

To be clinically feasible it must be possible to perform spinal cord cooling effectively in any operating room with relatively simple equipment. It is likely that the surgeon who first sees the patient will be operating in a community hospital, rather than in a medical center with elaborate facilities and heat exchangers. The simplified technique described here requires inexpensive and readily available equipment and, as we have demonstrated, cord temperature levels are within the range described by others using more elaborate techniques. The effectiveness of the apparatus was evaluated on 12 dogs, so temperature measurements could be made from within the spinal

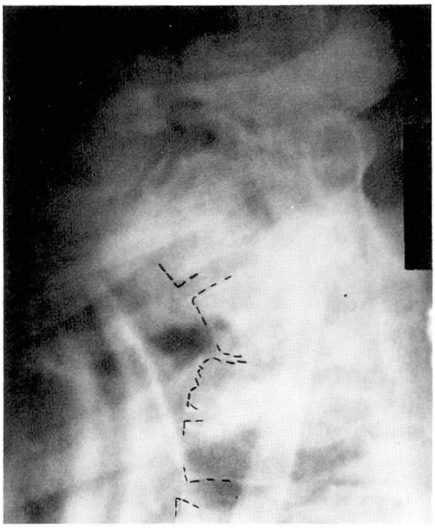

Fig. 9. Case 7. Compression fractures of T-2 to T-4 with dislocation of T-2 on T-3.

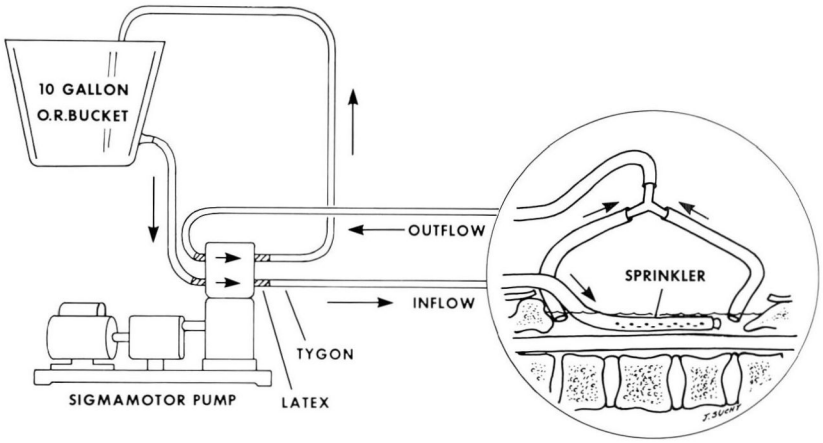

Fig. 10. Diagram of simplified system for spinal cord cooling.

cord as well as on its surface and in the adjacent muscle.

The reservoir is a 10-gallon covered bucket modified by soldering a nozzle ¼ inch in diameter at the side wall near the bottom. A sigma pump (Sigmamotor Model T-6S) is used to circulate the fluid, since in this apparatus the fluid does not come into contact with any part of the pump.

Two types of tubing are used in the system. Tygon tubing (ID $^3/_{16}$ inch, OD $^5/_{16}$ inch) is used throughout most of the system because of its excellent heat insulating properties. However, amber wall, soft latex surgical tubing (ID ¼ inch, OD ⅜ inch) must be used through the pump. The tubing is arranged as in *Figure 10*. The distal end of the tubing which sprinkles the cool solution across the cord has holes 1.0 mm in diameter punched around one half the circumference of the tubing. The length of the sprinkler segments should be equal to that of the exposed cord. The distal end of the tubing is occluded with a Tygon plug. A convenient way to suspend the sprinkler segment above the cord is to insert a 2-inch straight suture needle (Keith). Then the needle should be suspended between the muscle on either side, so that the sprinkler segment of the tubing is 5 mm above the surface of the cord.

The two tubes are used for the drainage system so the cooling solution can be removed from both ends of the laminectomy. The height at which the drainage tubing is placed will determine the depth of the cooling solution. The pool of solution should be quite shallow so that there is a constant flow over the surface of the cord with no dead space.

Cooling is done with saline solution or Ringer solution. Frozen solution should be prepared by filling Fenwal T8-10 transfer packs (1000 ml capacity with the inlet tube). These can be packed in sterile wrappers and stored in a freezer below 0 C. The plastic packs can be cut open so that the frozen Ringer or saline solution can be crushed and mixed with saline. Solution from two transfer packs can be crushed and mixed with 3 liters of liquid saline or Ringer solution in the bucket reservoir. The pump should be adjusted to maintain a flow of 600 ml/

min or slightly more. Evaluation reveals that this system at this rate of flow can maintain the spinal cord temperature at 1.5 C on the dorsal surface and 3.0 C on the ventral surface, with a maximum internal temperature of 14.5 C.

Discussion

In any heterogeneous group of patients, there are always multiple factors which contribute to the final result, especially in a situation as complex as a spinal cord injury. For that reason, it would be foolish to attribute recovery in any one case entirely to spinal cord cooling, just as it does not make sense to equate failure to recover with failure of spinal cord cooling as a method of treatment. Investigation of new methods of treatment would be justified solely by the fact that there are approximately 4,000 new quadriplegics each year in the United States.[2]

Bosch et al[2] emphasized that patients with injured spinal cords should be divided into two groups depending on whether the neurological lesions appear to be complete. They state that total and complete paraplegia or quadriplegia with no voluntary activity and complete anesthesia is an irreversible condition. Schwartz et al[3] agree, stating that "decompressive laminectomy in patients who developed immediate and complete sensorimotor paralysis following injury has rarely, if ever, resulted in significant functional recovery." They also point out that the prognosis is much better with the incomplete or partial lesion, and such a patient may almost completely recover.

In our series, five of seven patients were in the complete or irreversible category. Four of these five patients did not recover any function after surgery. One patient (Case 2), however, has recovered dramatically from complete quadriplegia to independent ambulation.

Two patients in this series had incomplete lesions, and the prognosis was more favorable regardless of treatment. One patient (Case 3) had signs of the "central cord syndrome" described by Schneider.[4] This type of patient constituted the largest group (70%) in the Bosch et al[2] series. These authors state that surgery is contraindicated with this lesion, since some spontaneous recovery always occurs, and surgery may further jeopardize the cord. However, 68% of the patients in their series were never capable of ambulation.

Decompressive laminectomy alone, or in combination with opening of the dura, may have contributed to the recovery in our three cases. It should be noted however, that the results of decompressive laminectomy have not been completely satisfactory. It would seem that if cord compression were responsible for the initial deficit, this should have been apparent at the time of operation. An epidural hematoma was found in one patient (Case 3), but in another patient (Case 2), no such compression was evident. The patient in Case 1 did have an epidural mass, but previous decompression procedures had not been of lasting value.

All of our patients received dexamethasone postoperatively, and this may have played a role in the recovery. Ducker and Hamit[5] found that improvement with dexamethasone alone was almost as great as that with spinal cord cooling. The patient (Case 1)

who was treated early with dexamethasone received no lasting benefit.

Spinal cord hypothermia appears to be a relatively safe procedure. Albin et al[6] studied the effects of hypothermia alone without injury on the spinal cords of dogs. They did not note any permanent deficit, although some animals demonstrated transient weakness. There was histological evidence of minimal edema and myelin degeneration, primarily at the sites of catheter placement. There was a slight decrease in body temperature in two animals. In a later study,[7] none of the animals had decreased body temperatures or neurological deficit. Negrin[8] also did not find any deficit in dogs treated by cooling for several hours.

The period of time during which spinal cord cooling is effective seems to be limited to 8 hours after the injury.[9] The maximal benefit was noted by Albin et al[1] when cooling was done within 4 hours of injury.

The mechanism of improvement after spinal cord cooling is not known, but it is postulated to be based on the reduction of edema and improvement in cord perfusion.[5] It has been observed experimentally that after cooling, the size of the ecchymotic edematous cord is often reduced.[1, 5]

Another possible explanation for the effectiveness of spinal cord cooling may concern the local accumulation of norepinephrine, as described by Osterholm and Mathews.[10] They note that after an experimental spinal cord injury similar to that produced by Albin et al[1] there is a gradual accumulation of norepinephrine at the site of injury, probably of neuronal origin. They have demonstrated that this norepinephrine is toxic to the cord and causes a hemorrhagic necrosis. One might speculate that the decreased metabolic activity of the neurons during the period of hypothermia might either decrease the production of norepinephrine or decrease the toxic effects of norepinephrine on the cord.

Clinical experience with spinal cord cooling has not been as encouraging as the experimental results for a number of reasons. The experimental injuries have been largely in the lower thoracic cord, which is supplied by the artery of Adamkiewicz, and is probably the part of the cord with the best blood supply. Only one of our patients was injured in this region, and he had anatomical disruption of the cord. Another factor is the extreme variability of the amount of trauma applied to the cord in the clinical situation. The experimental animals received threshold injuries which would have the greatest potential for recovery.

We believe that the experimental evidence in favor of spinal cord cooling is very convincing, and we are encouraged by our experience with a few patients. Although the small size of our series does not allow any definite conclusions, we encourage further clinical trials with this technique. We also urge that all clinical experience with this procedure be reported, so that sufficient clinical experience can be accumulated to evaluate objectively the procedure of spinal cord cooling.

References

1. Albin MS, White RJ, Acosta-Rua G, et al: Study of functional recovery produced by delayed localized cooling after spinal cord injury in primates. J Neurosurg **29:** 113–120, 1968.
2. Bosch A, Stauffer ES, Nickel VL: Incomplete traumatic quadraplegia. A ten-year review. JAMA **216:** 473–478, 1971.
3. Schwartz HG, Coxe WS, Goldring S: Definitive treatment of spinal cord injuries, pp. 277–286 *in* Neurological Sur-

gery of Trauma. Edited by AM Meirowsky, Washington, D. C., Office of the Surgeon General, Dept. of the Army, 1965.
4. Schneider RC, Cherry GR, Pantek H.: The syndrome of acute central cervical spinal cord injury, with special reference to mechanisms involved in hyperextension injuries of the cervical spine. J Neurosurg **11:** 546–577, 1954.
5. Ducker TB, Hamit HF: Experimental treatments of acute spinal cord injury. J Neurosurg **30:** 693–697, 1969.
6. Albin MS, White RJ, MacCarty CS: Effects of sustained perfusion cooling of the subarachnoid space. Anesthesiology **24:** 72–80, 1963.
7. Albin MS, White RJ, Locke GE, et al: Spinal cord hypothermia by localized perfusion cooling. Nature **210:** 1059–1060, 1966.
8. Negrin J Jr: Spinal cord hypothermia to relieve muscle spasticity in multiple sclerosis—preliminary observations. J Nerv Ment Dis **144:** 430–434, 1967.
9. Albin MS, White RJ, Yashon D, et al: Functional and electrophysiologic limitations of delayed spinal cooling after impact injury. Surg Forum **19:** 423–424, 1968.
10. Osterholm JL, Mathews GJ: Treatment of severe spinal cord injuries by biochemical norepinephrine manipulation. Surg Forum **22:** 415–417, 1971.