

Cher. Clin. Quart. (1945) 12:65-67

REMOVAL OF BROKEN KNIFE BLADE FROM SPINAL CANAL

Report of a Case

W. JAMES GARDNER, M.D.

In the absence of infection the presence of a metallic foreign body in the tissues may be of little clinical significance. This, however, is not always true. The following case is reported because it demonstrates conclusively that a metallic foreign body can cause progressive damage to adjacent nerve tissue. The foreign body was a chrome-plated steel knife blade with a nick exposing the steel on that part of the blade which lay within the spinal cord. Corrosion occurred at this site. Pain was the first irritative symptom and began one month after introduction of the foreign body. Signs of cord damage progressed rapidly from the twelfth to the fourteenth month and began to subside within five days after the blade's removal.

CASE REPORT

A white man, aged 37, was first examined on October 11, 1944 with complaints of weakness in the legs, numbness from the waist down, and pains about the lower chest. While employed as a bus driver in October 1943 he was attacked by a passenger. As he ducked under his assailant's arm, he received a blow on the back and dropped to the floor paralyzed from the waist down. He was taken to a hospital, and his wife was told the paralysis was caused by hysteria.

Roentgenologic examination of the spine ten days after the accident was said to be normal. At the end of fifteen days a slow gradual return of function began and continued for three months, after which numbness and weakness remained static. After the injury the patient had constipation, hesitancy and urgency of urination, and complete impotence. A month after the accident he developed gradually increasing pains radiating from his spine forward about the lower borders of the ribs. The patient was examined by a neurologist six months after injury and was told that he had a stab wound of the spinal cord. Because of disability of the lower extremities he was advised to get a sedentary job and became a clerk in a steel plant. He sought further advice because of increasing pain.

Examination revealed a small transverse scar 2 cm. in length just left of the mid-line below the tip of the ninth dorsal spinous process. At the time of injury this wound was apparently considered a superficial laceration. The gait was very spastic, especially movement of the right leg. The abdominal reflexes were active and equal. The patellar and Achilles tendon reflexes were hyperactive. Babinski reflex and ankle clonus were present on the right. There was almost complete analgesia of the left lower extremity up to the eleventh dorsal dermatome, and slight hypalgesia in a corresponding distribution on the right. Thermal perception was similarly disturbed over a similar area. Perception of light touch was less impaired. Roentgenologic examination of the lower dorsal spine showed the broken end of a knife blade 6 cm. in length passing between the lamina of the ninth and the tenth dorsal vertebra. The tip was buried in the posterior

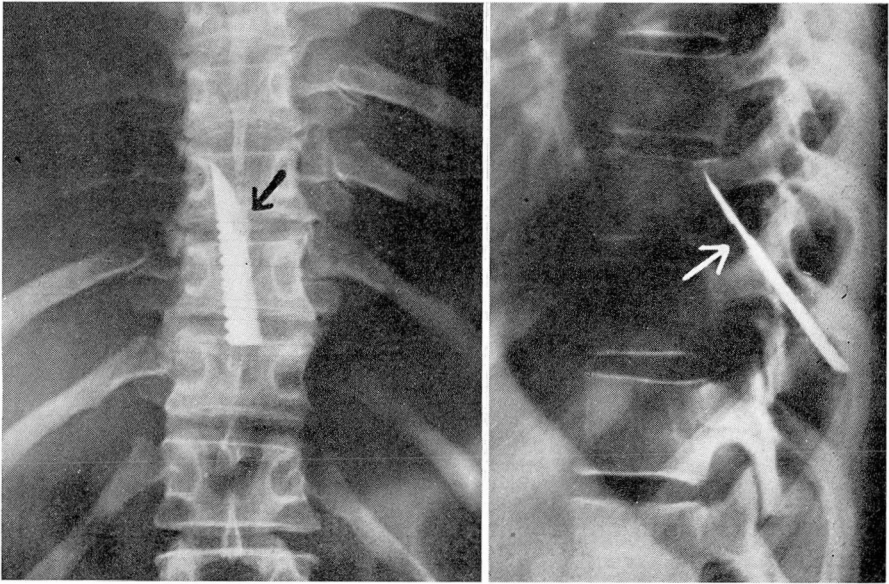


FIGURE 1. Roentgenograms showing position of blade. Arrows point to location of nick within spinal canal.

portion of the body of the ninth dorsal vertebra (figure 1). The diagnoses were stab wound of the spinal cord causing Brown-Sequard's paralysis and foreign body in the spinal canal.

The patient was informed of the presence of the foreign body and was advised to have it removed if paralysis increased. Immediate operation was not advised because of the risk of aggravation of symptoms, which might accompany the trauma of removal. He was fitted with a spinal brace and advised to limit his activity and to sleep on a firm bed.

The patient was admitted to the hospital two months later. He had increasing difficulty in walking during the past five weeks and for three weeks had been unable to walk alone. He had increasing constipation as well as frequency, urgency, and occasional loss of urinary control. Examination revealed virtually complete paralysis of both legs, a bilateral Babinski response, and more pronounced sensory findings than on previous study. Bladder function appeared to be automatic.

The patient was operated upon on December 11, 1944 under pentothal anesthesia. The broken knife blade was found passing forward between the ninth and the tenth spinous process. The eighth, ninth, and tenth spinous processes and their laminae were removed. After exposing the extraspinal portion, the knife blade was found to be loose and freely movable and was withdrawn readily from the spinal canal. The scar in the dura and cord was freed by incising the dura surrounding it. Some constriction of the spinal cord by scar tissue contraction of the dura was evident. The knife blade had entered the posterior aspect of the spinal cord about 3 mm. to the left of the midline and had passed diagonally forward and to the right. Whether the blade had entirely severed

REMOVAL OF BROKEN KNIFE BLADE

the right lateral aspect of the cord was uncertain, but it appeared probable because of the width of the blade. Some of the scarred dura was removed for microscopic study. The wound was closed with several tiers of interrupted black silk sutures.

The knife blade was sharp, of chrome-plated steel, 6 cm. in length and 11 mm. in its greatest width, and had on its posterior edge a series of saw-toothed serrations apparently designed for scaling fish. A thumbnail groove indicated that it was a clasp knife. On the cutting edge 1.5 cm. from the point and corresponding to the nick shown on the roentgen film was an area of corrosion measuring 7 by 4 by 1.5 mm. This rusty portion of the blade had been embedded in the spinal cord. The broken end of the blade, which had been buried in the muscles outside the spinal canal, showed virtually no corrosion, although more of the steel was exposed here than at the nick on the cutting edge.

The patient's postoperative course was uneventful. Munro tidal drainage was carried out until the eighth postoperative day when he began to void voluntarily. When discharged on the twelfth postoperative day, he was able to walk, and his pain was relieved. Two months after operation the patient was able to walk without support although with considerable spasticity. The sensory picture was unchanged. He voided with some difficulty and still had complete impotence. He was beginning to have some recurrence of root pain in the distribution of the right ninth dorsal dermatome.

COMMENT

A common mistake of clinicians in diagnosing lesions of the spinal cord is to place the lesion too low in the vertebral column. This is largely due to the fact that nerve roots ascend within the spinal canal to enter the cord at a level higher than the corresponding vertebrae. Thus it is not uncommon for a roentgenogram of the lumbar spine to be ordered in a case of spastic paraplegia, when the spasticity alone is positive proof that the lesion is above the lumbar level. In this case roentgenologic examination at the time of the accident was probably made at too low a level, and therefore the foreign body was not discovered. The neurologist who examined the patient six months later was told that the initial examination was negative and did not request additional films. Twelve months after the accident this omission was almost repeated.

It seems unlikely that pressure due to the increasing bulk of the rusting foreign body could have been responsible for the progressive damage to the cord. The fact that the blade was not closely invested by surrounding tissue suggests intolerance on the part of the host to the metals of the knife blade. It is interesting to speculate why the exposed portion of steel within the spinal cord oxidized more rapidly than that portion buried in the spinal muscles.