CLEVELAND CLINIC QUARTERLY
Volume 38, April 1971
Copyright © 1971 by The Cleveland Clinic Foundation
Printed in U.S.A.

# Dubin-Johnson syndrome with varied manifestations

## *Report of two cases*

RICHARD G. FARMER, M.D.
Department of Gastroenterology

WILLIAM A. HAWK, M.D.
Department of Pathology

B. H. SULLIVAN, JR., M.D.
Department of Gastroenterology

WHAT is now known as the Dubin-Johnson syndrome was originally reported in 1954 as "chronic idiopathic jaundice." [1] That same year Sprinz and Nelson[2] reported four cases with similar clinical and histologic features; in 1958 Dubin[3] reviewed 50 cases. Since then there have been other case reports, which have emphasized the familial nature[4, 5] and world-wide occurrence of the syndrome.[6]

Recent studies have concerned selected features of the Dubin-Johnson syndrome with particular attention given to the delay in secretion of sulfobromophthalein in patients with that disease.[7, 8] Further, electron microscopic studies of the ultrastructure of the hepatic cell have been done,[9] but without positive identification of the abnormal pigment present in the hepatic cell. It is usually considered to be in the lipochrome or lipofuscin family of pigment. The exact mechanism of hyperbilirubinemia remains unknown, although conjugated hyperbilirubinemia is the hallmark of the syndrome. Since hyperbilirubinemia is intermittent, it has been postulated that there is an inherited failure of biliary secretion, with inconstant clinical manifestations.[10-13] It has been this unusual aspect of the Dubin-Johnson syndrome which has attracted most recent attention. There has been considerable emphasis on biliary secretion, cholestasis, and excretion of conjugated bilirubin by the liver cell;[10-13] and yet the Dubin-Johnson syndrome seems to be a unique form of failure of excretion of conjugated bilirubin. The only syndrome which appears to be similar is the Rotor syndrome,[10-14] in which there is also a failure of biliary excretion of conjugated bilirubin, but without the presence of lipochrome pigment.

Recently, we have seen two patients with the Dubin-Johnson syndrome. Both had unusual manifestations of jaundice, and in each instance the diagnosis of Dubin-Johnson syndrome could easily have been overlooked if one were not considering such an entity in the differential diagnosis. Because

of the unusual clinical manifestations and because of the continuing interest in this unusual but not rare syndrome, we are presenting a report of two cases.

**Case 1.** A 17-year-old man was referred to the Cleveland Clinic for evaluation and treatment, because of the onset of jaundice after a knee operation in April 1970. He had had an operation on his right knee in March 1969, for a football injury, and a reoperation in April 1970. After the second operation he became jaundiced; this cleared spontaneously after a few days. Following football practice in August 1970 he became slightly icteric again. He was then referred to the Cleveland Clinic by his physician because of concern over the diagnosis, prognosis, therapy, and the possible relationship to halothane anesthesia, which had been administered during both knee operations. His medical records indicated a maximum serum bilirubin content of 3.6 mg per 100 ml in April 1970. At that time the direct Van den Bergh registered 2.5 mg and the indirect 1.1 mg. In May the direct bilirubin was 1.6 mg, indirect 0.8 mg, total 2.4 mg. On June 19 (at the time of a periodic evaluation by his local physician because of the history) the direct bilirubin was 1.1 mg, indirect 1.7 mg, and total 2.8 mg. On August 14, following the onset of clinical jaundice, the direct bilirubin was 1.7 mg, indirect 1.5 mg, and total 3.2 mg. On August 28 the direct was 2.15 mg, indirect 1.5 mg, and total 2.65 mg. On September 4 the direct bilirubin was 1.8 mg, indirect 1.2 mg, and total 3.0 mg. On September 11 the direct bilirubin was 3.1 mg, indirect 1.6 mg, and total bilirubin had reached its maximum of 4.7 mg. Other liver function studies including serum glutamic-oxalacetic transaminase (SGOT), glutamic-pyruvic transaminase, prothrombin time, alkaline phosphatase were performed in April and were normal. Results of other studies at that time included normal values for blood cholesterol, total protein, serum albumin, and methemoglobin. The blood counts were normal; Coombs' test was negative.

At the time of initial physical examination the patient was asymptomatic, he had not had anorexia, weight loss, abdominal pain, nausea, vomiting, or pruritis. There had been no change in the color of urine or stool; he remembered that the urine had been "darker" at the time of the second operation. The physical examination was entirely normal. He had no hepatosplenomegaly, no icterus and there were no stigmata of liver disease.

The following laboratory studies were normal: hemoglobin, hematocrit, white cell count and differential, platelet count, red cell count, urinalysis, serology, LE test, antinuclear factor, smooth muscle, antibody, prothrombin time, protein electrophoretic pattern, LDH, alkaline phosphatase, SGOT, cholesterol, calcium, phosphorus, uric acid, blood urea nitrogen, blood sugar. Lymphocyte transformation test for halothane was negative with no significant blast cell formation with halothane. Two bilirubin determinations were abnormal, with direct of 2.3 or a total of 3.6 mg and a total of 2.8 mg respectively. Sulfobromophthalein dye retention was 7 percent in 45 minutes.

He was admitted to the hospital for liver biopsy, which was done using the Menghini technic. This demonstrated centrilobular lipochrome pigment desposition and was typical of the Dubin-Johnson syndrome (*Fig. 1 and 2*).

The patient was discharged to his home and was told that he could play football and engage in other physical activity.

**Case 2.** A 49-year-old man was referred to the Cleveland Clinic in April 1970 because of chest pain and fever. He had a history of intermittent jaundice since 1945, at which time he had been hospitalized while in the military service. He stated that the jaundice had cleared and he was said to be "cured." He did not recall whether or not a diagnosis of hepatitis had been made. Since 1945 he had noted jaundice on a few occasions; usually only scleral icterus and usually transient. He had noted a mild degree of scleral icterus with his present illness. He stated that he had felt well until March 1970.

On physical examination there were no specific abnormalities noted except for mild scleral icterus. There was no hepatosplenomegaly or other stigmata of liver disease.

Extensive studies were undertaken while he was hospitalized, and the clinical diagnosis was benign relapsing pericarditis with recent evidence of pulmonary embolism. He had a history of myocardial infarction three years previously, and it was thought that he likely had had multiple pulmonary emboli during that period. Pulmonary angiography, and scanning, intravenous urogram, upper gastrointestinal series, and other studies were performed.

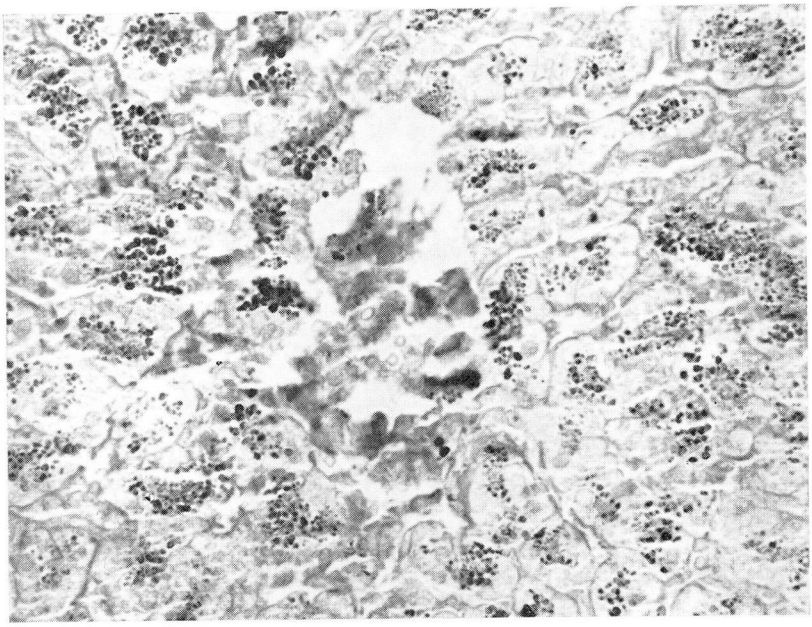

**Fig. 1.** A photomicrograph of a representative centrilobular area showing the intracytoplasmic collections of pigment granules in most of the liver cells (Case 1). Hematoxylin-eosin stain; magnification × 400.



**Fig. 2.** A photomicrograph of an acid-fast preparation demonstrating the abundant pigment granules. The granules stained bright red; magnification × 400.

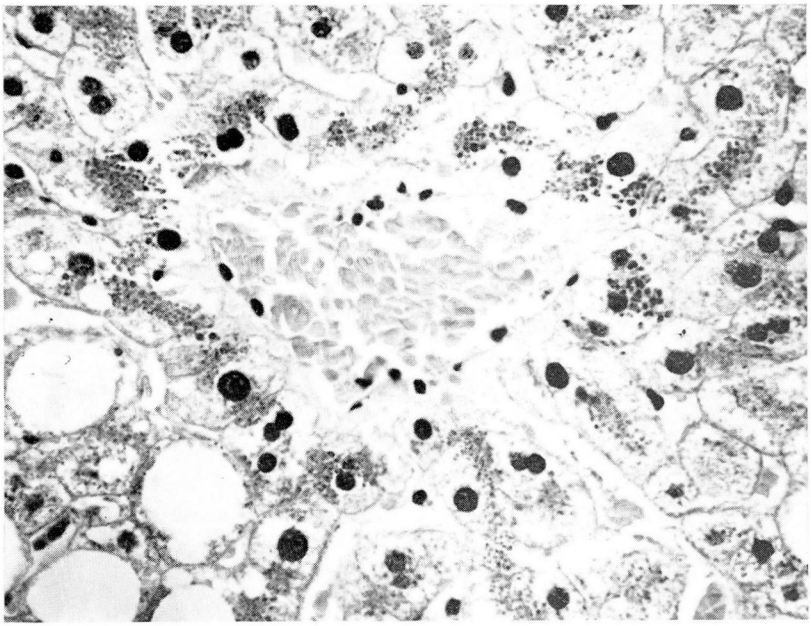

**Fig. 3.** A photomicrograph of a centrilobular area in the liver biopsy of Case 2. The collections of granules are similar to Case 1; the fatty change is regarded as unrelated to the pigment accumulation. Hematoxylin-eosin stain; magnification × 400.

Laboratory studies with regard to hepatic function demonstrated serum bilirubin of 3.8 mg per 100 ml total, direct reacting bilirubin was 2.0 mg, and indirect 1.8 mg. Subsequent bilirubin determinations were 2.7 mg total with 1.0 mg direct, and 2.5 mg total with 1.4 mg direct. Two determinations of SGOT and three determinations of serum alkaline phosphatase were normal. Serum protein electrophoretic pattern was normal; immunoglobulins were normal; prothrombin time was normal. Smooth muscle antibody, mitochondrial antibody, antinuclear factor, LE test, and Australian antigen were negative. An oral cholecystogram done following a double dose of dye showed nonvisualization.

Liver biopsy performed using the Menghini needle demonstrated intracytoplasmic pigment, lipochrome-like, principally in the central areas, and was typical of the Dubin-Johnson syndrome (*Fig. 3*). The patient was informed that this was an incidental finding and bore no relationship to the other disease process.

## Discussion

Although unusual, the Dubin-Johnson syndrome is a form of jaundice which continues to excite much interest, and is now thought of in the category of biliary secretory failure.[10, 11] An interesting feature of the Dubin-Johnson syndrome is that it appears to be a selective form of failure of excretion of conjugated bilirubin, as other substances—particularly bile salts—are excreted in a normal manner. The relationship in biliary excretion between bilirubin and sulfobromophthalein has been emphasized by studies of patients with the Dubin-Johnson syndrome and delayed excretion of sulfobromophthalein.[7, 8]

Of particular interest in our two cases is the relationship to other illnesses or surgery, and mild exacerbation of the icterus associated with failure of

biliary excretion. The first patient illustrates the concern over the possibility that the jaundice was related to the administration of halothane,[15, 16] which has become a significant medical and at times medicolegal problem. The age of the patient and the importance of conveying a benign prognosis are additional features of this case. (A medically minor but psychologically important factor was his return to full activity as a quarterback of his high school football team.) The occurrence of jaundice during the course of an unrelated illness is perhaps a more typical manifestation, as illustrated by case 2. Again, the ability to differentiate the benign Dubin-Johnson syndrome from other clinical manifestations was of definite significance in the management of the patient's problems.

The histologic appearance of needle biopsies of the liver in patients with the Dubin-Johnson syndrome is most helpful in establishing the diagnosis. In general, the lesion observed is a collection of coarse pigment granules within the cytoplasm of the centrilobular hepatocytes and within some Kupffer cells. This pigment imparts a dark brown coloration which may be observed grossly in the needle biopsy specimen. In hematoxylin-eosin stained sections, the centrilobular areas are often strikingly brown. The pigment possesses the tinctorial properties of a lipofuscin, being iron negative, weakly positive for lipids, and acid-fast when stained using a modified Ziehl-Nielson method. In addition, sections exposed to ultraviolet light demonstrate the autofluorescence of this type of pigment. Aside from the abnormal accumulation within the hepatocytes and Kupffer cells, there are no other histologic abnormalities noted. The relationship of this pigment to the abnormal excretion of conjugated bilirubin continues to be obscure. In recent publications[17, 18] a disease of similar character has been observed in sheep; and in one of these publications,[17] it was reported that the pigment had been established as a metabolite of epinephrine and also possessing properties of melanin.

In recent years much has been learned about the metabolism of bilirubin, and the clinical differentiation of various types of jaundice is now more sophisticated as further elaborations of the mechanisms of metabolism of bilirubin are delineated.[12, 13] The diagnosis of Dubin-Johnson syndrome should be considered for any patient with a history of intermittent jaundice, intermittent jaundice since childhood, jaundice following other illnesses, injuries, or operations, and/or a family history of intermittent jaundice. Because the defect resides in the excretion of conjugated bilirubin, the hyperbilirubinemia in the Dubin-Johnson syndrome is largely of the "direct" type and thus can be readily differentiated from Gilbert syndrome[12, 13] (*Table 1*), which appears to be a defect in bilirubin uptake by the liver cell and/or hepatic conjugation with glucuronyl transferase.[19] Finally, the concern in differential diagnosis and especially, as illustrated by case 1, the possible relationship to halothane an interesting manifestations of this form of congenital jaundice.

**Table 1.**—Features of Dubin-Johnson and Gilbert syndromes

| | Dubin-Johnson | Gilbert |
|---|---|---|
| Jaundice associated with stress or fatigue | + | + |
| Total serum bilirubin less than 5 mg/100 ml | + | + |
| Bilirubin predominately unconjugated | 0 | + |
| Bilirubin predominately conjugated | + | 0 |
| Nonvisualization of gallbladder | + | 0 |
| Pigment in liver cells | + | 0 |
| Abnormal sulfobromophthalein retention | + | 0 |

## Summary

Two patients with the Dubin-Johnson syndrome seen within six months at the Cleveland Clinic are presented. One patient had jaundice after a second knee operation, and it was felt that clinically this represented a relationship to halothane anesthesia. The second patient developed jaundice during the course of another illness. In both situations liver biopsy was diagnostic for the Dubin-Johnson syndrome, and the conditions could be recognized as benign and unrelated to the potential or significant problems presented in the differential diagnosis. The Dubin-Johnson syndrome probably is more common than has been thought. It should be considered in the differential diagnosis of patients with intermittent jaundice, especially those in whom the jaundice is associated with illness or operation. The benign nature of the Dubin-Johnson syndrome is again emphasized.

## References

1. Dubin, I. N., and Johnson, F. B.: Chronic idiopathic jaundice with unidentified pigmented liver cells. A new clinicopathologic entity with a report of 12 cases. Medicine **33:** 155–197, 1954.
2. Sprinz, H., and Nelson, R. S.: Persistent nonhemolytic hyperbilirubinemia associated with lipochrome-like pigment in liver cells: report of four cases. Ann. Intern. Med. **41:** 952–962, 1954.
3. Dubin, I. N.: Chronic idiopathic jaundice: a review of 50 cases. Amer. J. Med. **24:** 268–292, 1958.
4. Butt, H. R., and others: Studies of chronic idiopathic jaundice (Dubin-Johnson syndrome). II. Evaluation of a large family with the trait. Gastroenterology **51:** 619–630, 1966.
5. Blanck, C., and others: Chronic idiopathic jaundice (Dubin-Johnson's syndrome) in three sisters. Acta Paediat. Scand. **55:** 329–336, 1966.
6. Powell, K. C., and others: Dubin-Johnson syndrome. Med. J. Australia **1:** 957–958, 1970.
7. Dollinger, M. R., and Brandborg, L. L.: Late elevation in serum bromsulfalein in Dubin-Johnson syndrome. A comparative case study. Amer. J. Dig. Dis. **12:** 413–417, 1967.
8. Gutstein, S.; Alpert, S., and Arias, I. M.: Studies of hepatic excretory function. IV. Biliary excretion of sulfobromophthalein sodium in a patient with the Dubin-Johnson syndrome and a biliary fistula. Israel J. Med. Sci. **4:** 36–40, 1968.

9. Toker, D., and Trevino, N.: Hepatic ultrastructure in chronic idiopathic jaundice. Arch. Path. **80:** 453–460, 1965.

10. Sherlock, S.: Biliary secretory failure in man. The problem of cholestasis. Ann. Intern. Med. **65:** 397–408, 1966.

11. Arias, I. M.: The excretion of conjugated bilirubin by the liver cell. Medicine **45:** 513–515, 1966.

12. Billing, B. H., and Black, M.: Bilirubin metabolism. Gut **10:** 250–254, 1969.

13. Gartner, L. M., and Arias, I. M.: Formation, transport, metabolism and excretion of bilirubin. New Engl. J. Med. **280:** 1339–1345, 1969.

14. Rotor, A. B.; Manahan, L., and Florentin, A.: Familial nonhemolytic jaundice with direct van den Bergh reaction. Acta Med. Philipp. **5:** 37–49, 1948.

15. Klion, F. M.; Schaffner, F., and Popper, H.: Hepatitis after exposure to halothane. Ann. Intern. Med. **71:** 467–477, 1969.

16. Peters, R. L., and others: Hepatic necrosis associated with halothane anesthesia. Amer. J. Med. **47:** 748–764, 1969.

17. Arias, I., and others: Black liver disease in Carriedale sheep: a new mutation affecting hepatic excretory function. (Abstract) J. Clin. Invest. **43:** 1249–1250, 1964.

18. Cornelius, C. E., and others: Dubin-Johnson syndrome in immature sheep. Amer. J. Dig. Dis. **13:** 1072–1076, 1968.

19. Berk, P. D., and others: Constitutional hepatic dysfunction (Gilbert's syndrome). A new definition based on kinetic studies with unconjugated radiobilirubin. Amer. J. Med. **49:** 296–305, 1970.