CLEVELAND CLINIC QUARTERLY
Volume 38, October 1971
Copyright © 1971 by The Cleveland Clinic Foundation
Printed in U.S.A.

# Unusual arteriovenous communications: arteriographic and hemodynamic studies

EDWARD D. FROHLICH, M.D.*
Division of Research

VICTOR G. DEWOLFE, M.D.
Department of Peripheral Vascular Disease

CEDOMIL F. VUGRINCIC, M.D., SC.D.†

THE existence of hyperkinetic cardiovascular states due to abnormal arteriovenous communications has been well-documented, particularly in congenital heart disease with shunts and in traumatic and congenital arteriovenous fistulas of large vessels. Less information is available concerning hyperkinetic cardiovascular states associated with rare forms of arteriovenous communications, including those diseases characterized by innumerable small arteriovenous communications.

Abnormal arteriovenous communications are now more readily detected and amenable to treatment because of new or improved diagnostic and surgical technics. Moreover, with renewed interest in earlier and more precise diagnosis than was formerly possible, new information is becoming available concerning morphologic and physiologic changes.

This report concerns the clinical and hemodynamic findings in seven patients with various types of arteriovenous communications associated with evidence of hyperkinetic circulation, and highlights the importance of arteriographic and hemodynamic studies in evaluation of the lesions.

## Materials and methods

Seven patients with clinical and laboratory evidence of arteriovenous communications were evaluated in the Cleveland Clinic Hospital. Hemodynamic studies were performed after treatment had been discontinued for one month. Catheters were inserted percutaneously through an antecubital vein and brachial artery, and were advanced centrally to the level of the superior vena cava or subclavian vein and axillary artery, respectively. Cardiac output was determined with indocyanine green dye and a Gilford densitometer as described previously.[1, 2] Heart rate was measured from a continuously recording electrocardiograph, arterial pressure by a Statham

* *Associate Professor of Medicine, The University of Oklahoma Medical Center, Oklahoma City, Oklahoma.*
† *Former Special Fellow, Department of Peripheral Vascular Disease, Cleveland Clinic.*

P23Db transducer, and left ventricular ejection time from a rapid recording (100 mm per sec) of the arterial pressure tracing. The other derived indices were calculated from conventional formulas. In the case of the more common lesion (a femoral arteriovenous fistula—Case 1), renal blood flow was measured using the indocyanine green dye-dilution method.[3]

## Report of cases

**Case 1.** *Traumatic arteriovenous fistula.* A 37-year-old woman was referred to the Cleveland Clinic on January 23, 1967, because of a pulsating mass in the left groin. Five years previously a bullet had pierced the left thigh and lodged in the groin from where it was removed; however, the pulsation persisted. Physical examination confirmed the pulsatile mass in the left femoral triangle, and a continuous bruit and a thrill were observed over the mass. Compression of the femoral artery above the mass was associated with a slowing of heart rate (Nicoladoni-Branham's sign) (*Table 1*).[4, 5] Other arterial pulsations in the extremity were normal. The heart was moderately enlarged. Transverse cardiac diameter on the posteroanterior chest roentgenograms obtained before and during compression of the left femoral artery (proximal to the mass) demonstrated a decrease of 1 cm during compression (*Fig. 1*). Arteriograms revealed an enlarged left common femoral artery and a communication between the deep femoral artery and a vein (*Fig. 2*). Selective renal arteriograms demonstrated normal, single, renal arteries. The renal arteries and veins were catheterized bilaterally, separate renal blood flows were measured, and systemic hemodynamic studies revealed a hyperkinetic state (*Table 1*). Increased heart rate, cardiac output, and left ventricular ejection rate were corrected when the femoral artery proximal to the fistula was compressed (*Table 1*). On this second and rather extensive study, the reflexive bradycardia (Branham's Sign) was not demonstrated (presumably because the

**Table 1.**—Case 1. Hemodynamic data

| Measurement | Traumatic arteriovenous fistula | |
|---|---|---|
| | Open | Closed |
| Immediate response | | |
| Arterial pressure (mm Hg) | 100/74 | 132/94 |
| Heart rate (beats per min) | 96 | 54 |
| Delayed response | | |
| Arterial pressure (mm Hg) | 132/76 | 148/104 |
| Mean arterial pressure (mm Hg) | 95 | 119 |
| Heart rate (beats per min) | 88 | 88 |
| Ejection time (msec) | 318 | 224 |
| Cardiac output (ml per min) | 11,390 | 5,865 |
| Cardiac index (ml per min per $M^2$) | 6,584 | — |
| Stroke volume (ml per beat) | 129 | 67 |
| Total peripheral resistance (mm Hg per ml per min) | .008 | .020 |
| Mean rate left ventricular ejection (index) (ml per sec per $M^2$) | 235 | 142 |
| Renal blood flow | | |
| Right (ml per min) | 608 | 775 |
| Left (ml per min) | 496 | 847 |
| Total (ml per min) | 1,104 | 1,622 |
| Total renal blood flow/cardiac output (percent) | 9 | 28 |

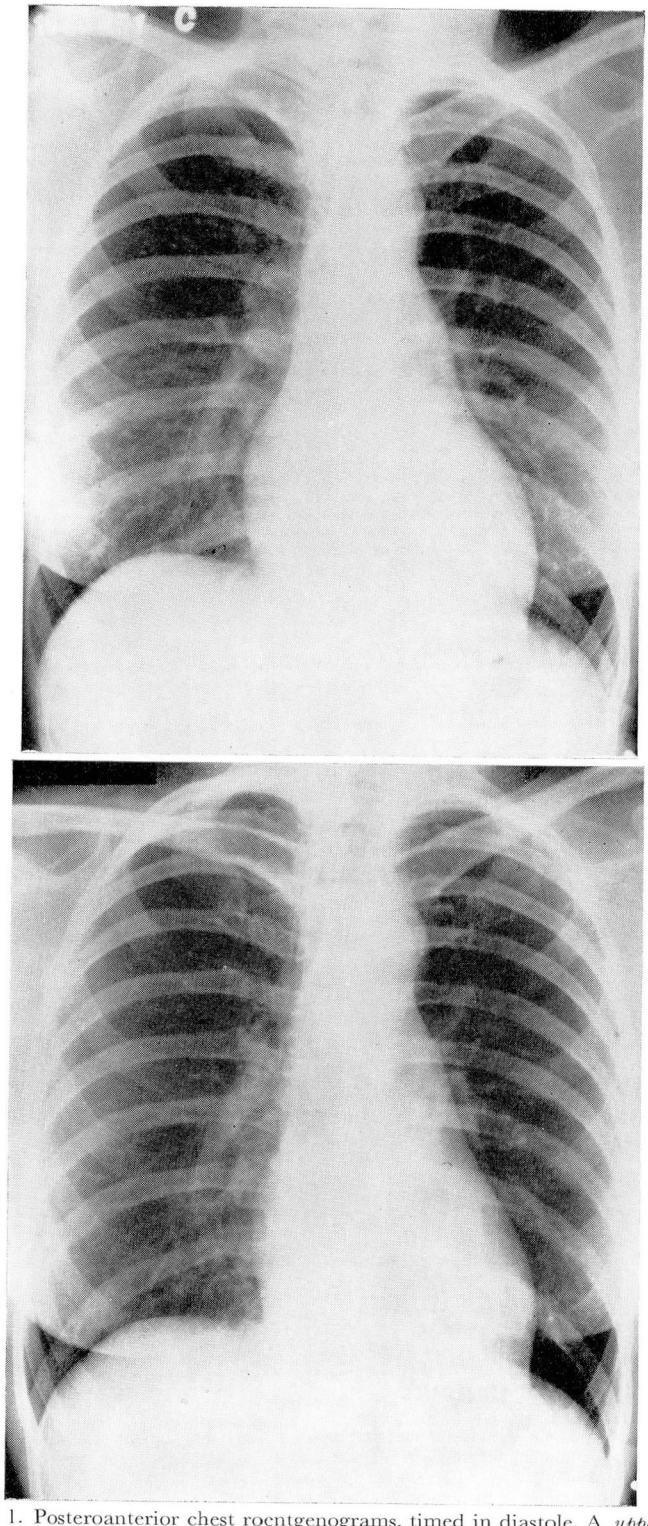

**Fig. 1.** Case 1. Posteroanterior chest roentgenograms, timed in diastole. A, *upper*, Before; B, *lower*, During compression of the left femoral artery proximal to the mass.

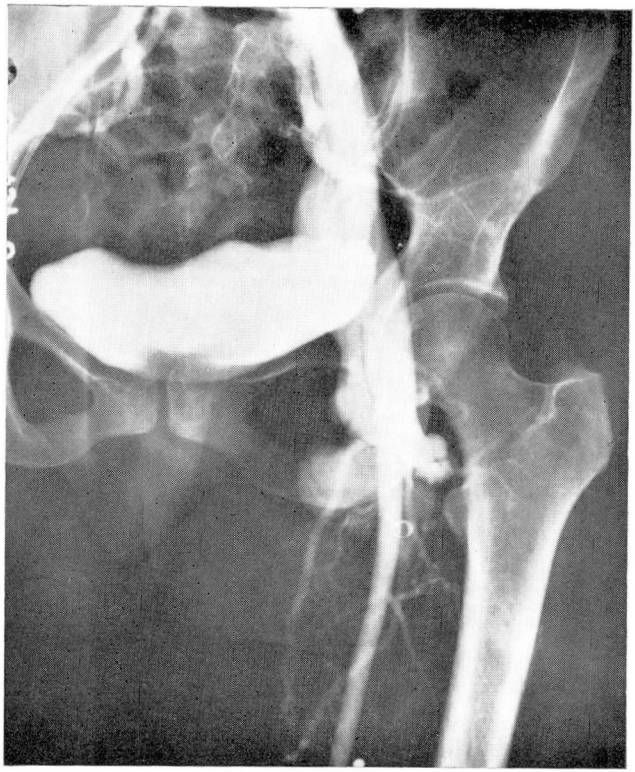

**Fig. 2.** Case 1. Femoral arteriogram revealing an enlarged left common femoral artery and a communication between the deep femoral artery and vein.

premedication given the patient was pentobarbital and meperidine); nevertheless, cardiac output was reduced by femoral arterial compression. Total renal blood flow, however, increased 48 percent after obliteration of the fistula. Before femoral arterial compression, renal blood flow accounted for only 9 percent of cardiac output; but with closure of the fistula, the renal fraction of cardiac output increased to a normal proportion (approximately 28 percent).

Surgical correction was advised. At operation the left common femoral and deep femoral arteries were found to be greatly enlarged; and the superficial femoral artery was small. A large fistula between the deep femoral artery and vein arising about 2 cm from the origin of the deep femoral artery could not be dissected out completely, because of communication between many large arterial and venous tributaries. The fistula and all visible arterial and venous tributaries were oversewn. One month postoperatively, hemodynamic studies demonstrated that the cardiac output had decreased to 7.2 liters per min (preoperatively, 11.4 liters per min); nevertheless, it still remained elevated. Arteriography was repeated and confirmed incomplete repair of the fistula, although the size and number of communicating vessels were less than before operation.

**Case 2.** *Superior mesenteric–portal vein fistula.* A 53-year-old woman was referred on February 27, 1969, because of an arteriovenous fistula between the superior mesenteric artery and the portal vein. One year previously she had incurred an abdominal gunshot wound. Three months later, a loud epigastric, systolic bruit and thrill were observed when the patient was examined preoperatively for a small intestinal obstruction. The arteriovenous fistula was found at the time of this second operation. At the present admission a selective superior mesenteric arteriogram demonstrated the fistula between a large branch

of the mesenteric artery (probably the middle colic artery) 7.0 cm from its origin and the portal vein (*Fig. 3*); selective celiac arteriography was normal. The hemodynamic study revealed an increased cardiac index (3.8 liters per min per $M^2$) (*Table 2*). An operation was advised, and the abnormality was corrected surgically.

**Case 3.** *Congenital and surgical femoral arteriovenous fistulas.* A 5-year-old boy was referred in July 1963, because of a limp and increased right leg length which also had dusky coloration of four months' duration. On examination, the right leg was longer, larger, and warmer than the left. There were prominent superficial veins to the level of the groin, ankle edema and, with dependency, the skin became cyanotic. Cardiac examination revealed an increased precordial thrust; the apex beat was 1 cm outside the left midclavicular line; and an apical systolic ejection murmur was audible. Arteriograms demonstrated an apparent arteriovenous malformation with increased vascularity at the level of the right knee, probably in the terminal branches of genicular arteries. Oxygen saturation of blood from the right femoral vein was 96 percent compared to 82 percent in the left femoral vein. Repair of the fistula was attempted by ligation and division of the descending branch of the lateral femoral circumflex, genicular, and anterior tibial arteries. During a four-year follow-up study, the discrepancy in leg lengths increased and the superficial veins became more prominent. However, a bruit could not be heard. He was readmitted to the hospital in June 1967 to have a 5-mm arteriovenous fistula made between the left superficial femoral artery and vein at the level of the mid-thigh in an attempt to lengthen the left leg. Preoperatively, hemodynamic studies demonstrated increased cardiac index (3.8 liters per min per $M^2$) consistent with the presence of a congenital arteriovenous fistula (*Table 3,* June 1967 A). Postoperatively, hemodynamic studies revealed a further increase in the cardiac index to 4.7 liters per min per $M^2$ (*Table 3,* June 1967 B).

The studies repeated six and 18 months postoperatively demonstrated persistence of the increased cardiac index (*Table 3,* 1968 B). With compression of the left femoral artery proximal to the fistula, cardiac output was reduced to the level of that before the fistula was made (*Table 3,* 1968 A). Moreover, simultaneous compression of both femoral arteries above the fistulas caused the cardiac output to be reduced to normal (*Table 3,* Dec. 1969 B).

**Case 4.** *Vascular hamartoma.* A 48-year-old man was first examined on May 22, 1966, because of a left buttock mass of 22 years' duration. For 18 years it had remained unchanged, but then became large and painful. One year before admission, venous bleeding from the dorsum of the left foot necessitated ligation and stripping of veins at another hospital. Thereafter, he noted tightness and heaviness of that leg, and skin ulcerations above the ankle.

Examination revealed a huge mass in the left buttock, varicose veins, and hyperpigmentation of the lower part of the leg. The heart was enlarged; and there was a left ventricular lift and fourth heart sound. Roentgenograms of the chest confirmed cardiomegaly, and retrograde femoral arteriography revealed the left external and internal iliac and deep femoral arteries with numerous tumor vessels supplied mainly by distal branches of the internal iliac and deep femoral arteries (*Fig. 4*). Late exposures showed a large arteriovenous malformation in the center of the tumor. A major part of the tumor was avascular.

Hemodynamic studies (*Table 2*) revealed an increased cardiac index (7.5 liters per min per $M^2$), stroke volume (166 ml), and left ventricular ejection rate index (283 ml per sec per $M^2$); total peripheral resistance was decreased (.007 mm Hg per ml per min).

At operation a 30 by 20 cm mass was excised, and microscopic studies revealed a vascular hamartoma. The tumor could not be removed completely because of extensive and multiple vascular communications. Postoperatively, the patient was much improved clinically, and when hemodynamic studies were repeated the cardiac output, although still high, had decreased from 13.61 to 9.11 liters per min.

**Case 5.** *Metastatic hypernephroma.* A 60-year-old man was first examined on April 13, 1968, because of a left buttock mass. Examination revealed a pulsating tumor with a continuous bruit over the left buttock and inguinal regions. The heart was slightly enlarged and a systolic ejection murmur was audible at the apex and along the left sternal border. The arterial pressure was 200/60 mm Hg and the heart rate was 100 beats per min. Left iliac arteriograms demonstrated a large vascular pelvic mass and destruction of the left inferior ramus of the pubic and ischial bones extending into the acetabulum (*Fig. 5*). The tumor was supplied by the left external pudendal and medial femoral circumflex arteries. The veins were dilated. Selective renal arteriograms revealed a well-vascularized left renal

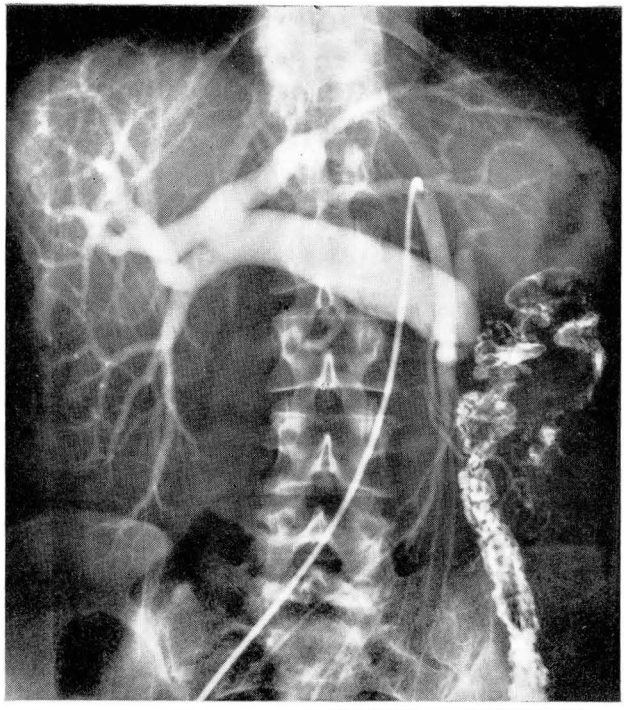

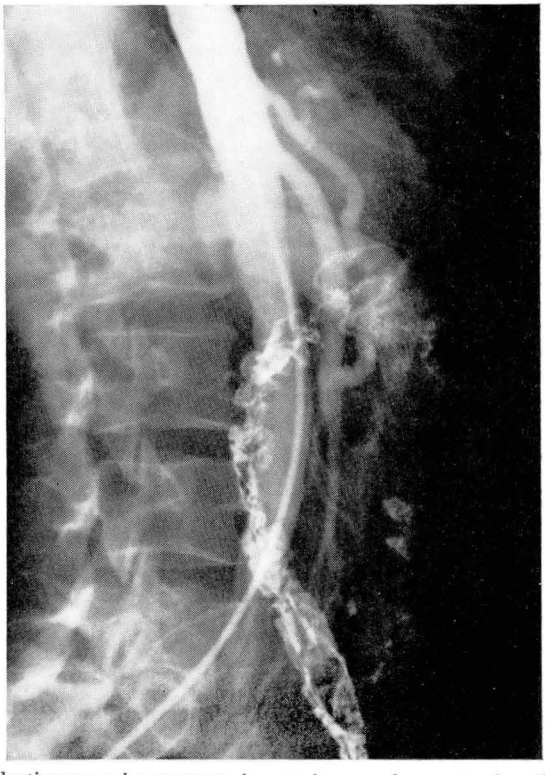

**Fig. 3.** Case 2. Selective superior mesenteric arteriogram demonstrating the fistula between a large branch of the superior mesenteric artery (probably the middle colic artery) and the portal vein. A, *upper,* Posteroanterior projection. B, *lower,* Lateral projection.

**Table 2.**—Summary of hemodynamic data of seven patients with abnormal arteriovenous communications

| Diagnosis | Patient Age, sex | Body surface area, ($M^2$) | Arterial pressure, (mm Hg) | Mean arterial pressure, (mm Hg) | Heart rate (beats per min) | Ejection time, (msec) | Cardiac output (ml per min) | Cardiac index (ml per min per $M^2$) | Stroke volume, (ml per beat) | Total peripheral resistance, (mm Hg per ml per min) | Mean rate left ventricular ejection (index) (ml per sec per $M^2$) | Blood volume, (ml) | Plasma volume, (ml per cm) |
|---|---|---|---|---|---|---|---|---|---|---|---|---|---|
| 1. Posttraumatic arteriovenous fistula | 36 F | 1.73 | 132/86 | 95 | 88 | 318 | 11390 | 6584 | 129 | 0.008 | 235 | 4750 | 17.7 |
| 2. Posttraumatic arteriovenous fistula | 53 F | 1.40 | 155/79 | 106 | 87 | 310 | 5348 | 3825 | 62 | 0.020 | 143 | 3069 | — |
| 3. Congenital and surgically-induced arteriovenous fistula | 9 M | 1.25 | 140/80 | 100 | 64 | 294 | 6038 | 4828 | 95 | 0.017 | 258 | — | — |
| 4. Vascular hamartoma | 48 M | 1.83 | 143/76 | 99 | 82 | 319 | 13600 | 7450 | 166 | 0.007 | 283 | 6700 | 27.2 |
| 5. Hypernephroma | 66 M | 1.94 | 164/9 | 61 | 92 | 257 | 11337 | 5850 | 122 | 0.005 | 245 | — | — |
| 6. Polyostotic fibrous dysplasia | 15 M | 2.26 | 165/74 | 103 | 152 | 201 | 15325 | 6780 | 101 | 0.007 | 221 | 8450 | 27.0 |
| 7. Paget's disease | 54 M | 1.89 | 143/55 | 84 | 69 | 304 | 7617 | 4025 | 111 | 0.011 | 193 | 7380 | 29.8 |

**Table 3.**—Case 3. Hemodynamic data

| | June 1967 | | December 1967 | | December 1968 | |
|---|---|---|---|---|---|---|
| | A | B | A | B | A | B |
| | Right congenital arteriovenous fistula | Right congenital arteriovenous and left surgical arteriovenous fistula | Left femoral artery occluded | Right arteriovenous fistula and left arteriovenous fistula | Left femoral artery occluded | Both femoral arteries occluded |
| Blood pressure (mm Hg) | 140/85 | 128/65 | 125/68 | 129/63 | 130/78 | 135/73 |
| Mean arterial pressure (mm Hg) | 103 | 87 | 87 | 85 | 95 | 94 |
| Heart rate (beats per min) | 54 | 70 | 55 | 68 | 75 | 50 |
| Ejection time (msec) | 322 | 286 | 290 | 287 | 244 | 289 |
| Cardiac output (ml per min) | 4126 | 5236 | 3896 | 4932 | 4625 | 3800 |
| Cardiac index (ml per min per $M^2$) | 3760 | 4675 | 3460 | 4400 | 3700 | 3040 |
| Stroke volume (ml per beat) | 73 | 75 | 70 | 73 | 62 | 76 |
| Stroke index (ml per beat per $M^2$) | 67 | 63 | 63 | 65 | 50 | 60 |
| Total peripheral resistance (mm Hg per ml per min) | 25 | 17 | 22 | 17 | 20 | 25 |
| Mean rate of left ventricular ejection time (ml per sec per $M^2$) | 207 | 234 | 216 | 227 | 254 | 210 |

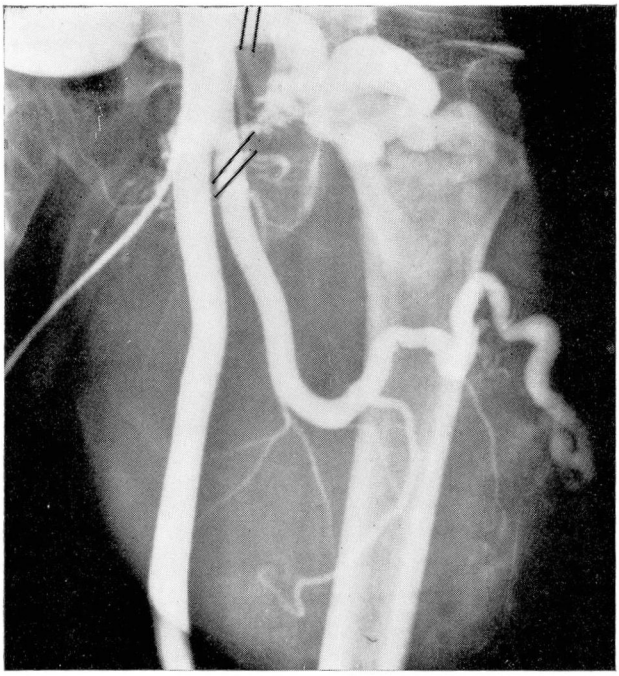

**Fig. 4.** Case 4. Retrograde femoral arteriogram demonstrating the left external and internal iliac and deep femoral arteries with numerous tumor vessels supplied mainly by distal branches of the internal iliac and deep femoral arteries. The patient had a vascular hamartoma.

tumor. The cardiac index (5.9 liters per min per $M^2$), stroke volume (122 ml) and left ventricular ejection rate index (245 ml per sec per $M^2$) were increased, and total peripheral resistance was decreased (.005 mm Hg per ml per min) (*Table 2*). Surgical exploration revealed a hypernephroma with metastases to the left gluteal region and the ischial and pubic bones. The histopathologic diagnosis was vascular clear-cell carcinoma, most likely of renal origin.

**Case 6.** *Polyostotic fibrous dysplasia.* A 15-year-old boy was first seen on August 10, 1968, because of a limp of 2 years' duration and a history of multiple fractures. Polyostotic fibrous dysplasia had been diagnosed in 1966. Examination revealed a brown, irregular, macular pigmentation of the skin and bony deformities typical of Albright's syndrome. There was no history or evidence of prematurity. Roentgenograms of the bones revealed deformities, demineralization, radiolucencies, distortion of the trabecular pattern, and evidence of old fractures. These changes were consistent with polyostotic fibrous dysplasia affecting the pelvis, femurs, tibias, fibulas, ribs, and skull; and right tibial biopsy confirmed the diagnosis. Serum calcium and inorganic phosphorus concentrations were 11.8 mg and 4.3 mg per 100 ml, respectively; serum alkaline phosphatase, 81.6 King-Armstrong units. Hemodynamic studies revealed increased heart rate (152 beats per min), cardiac output (15.3 liters per min), and left ventricular ejection rate index (221 ml per sec per $M^2$); and a reduced total peripheral resistance (.007 mm Hg per ml per min) (*Table 2*).

**Case 7.** *Paget's disease.* A 54-year-old man was referred on May 18, 1968, because of Paget's disease of several years' duration. Roentgenograms showed involvement of the bony structures of the thorax, spine, pelvis, both shoulder girdles, and hips. The serum alkaline phosphatase was 213 King-Armstrong units. Hemodynamic studies demonstrated increased cardiac index (4.06 liters per min per $M^2$), stroke volume (111 ml per beat), left ventricular

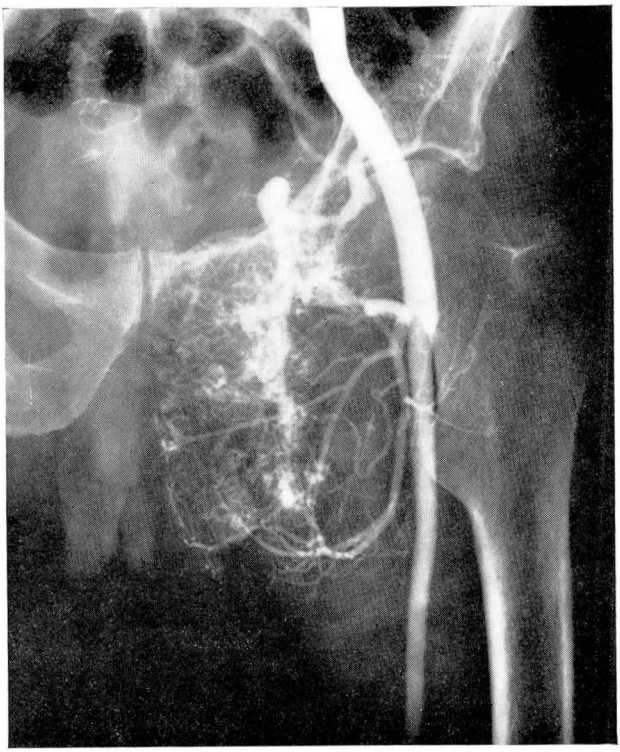

**Fig. 5.** Case 5. Left iliac arteriogram of a metastatic hypernephroma, demonstrating a large vascular pelvic mass, destruction of the left inferior ramus of the pubic and ischial bones extending into the acetabulum.

ejection rate index (193 per ml per sec per $M^2$); and decreased total peripheral resistance (.011 mm Hg per ml per min) (*Table 2*).

## Discussion

An abnormal arteriovenous communication is a pathologic connection between an artery and a vein without an intervening capillary bed; thus, the patient is literally bleeding into his veins because blood is shunted away from the tissues. To compensate for the resulting anoxia, peripheral vasodilatation, and otherwise unopposed hypotension, the heart increases its output both by an enhanced stroke output and an increased heart rate.[6] The hemodynamic changes of experimentally-induced arteriovenous fistulas and traumatic fistulas in patients have been studied extensively and are characterized by increased local blood flow, reduced total peripheral resistance, increased right atrial return, and augmented cardiac output.[7-10] Thus, immediately after the arteriovenous fistula is made, heart rate, central venous pressure, and cardiac output increase and systolic blood pressure decreases; venous oxygen saturation of the shunted blood also increases. In time,

diastolic pressure decreases as systolic pressure increases toward normal, thereby producing a wider pulse pressure. Intravascular volume increases coincident with the increase in venous return and cardiac output; the cardiac silhouette enlarges.[9-12] The increase in cardiac output approximates the amount of blood shunted through the fistula.[6, 8, 13]

With closure of a fistula, there is immediate slowing of the heart rate,[4, 5] a fall in central venous pressure, and reduction of cardiac output.[14] The mechanisms for this phenomenon are not understood entirely, although the reflexive cardiac slowing can be prevented by pretreatment with atropine.[15]

Renal function studies have revealed no changes in glomerular filtration rate, renal blood flow, or renal venous pressure whether a fistula was opened or closed.[16] However, even though the arteriovenous fistula demonstrated in the first patient in this present study is a fairly common clinical problem, it is reported because the renal hemodynamic measurements provided different information from that reported by Epstein and associates.[16] Thus, even though renal blood flow was normal in this patient, the renal fraction of cardiac output (9 percent) was greatly reduced. Moreover, when renal flow was measured immediately following occlusion of the fistula by femoral arterial compression, it was increased from 1104 to 1622 ml per min; since cardiac output concomittently fell, the renal fraction of cardiac output increased to a normal ratio (28 percent) (*Table 1*). Perhaps one explanation for this apparent discrepancy in findings may be differences in technics for measuring renal blood flow. Using indicator-dilution technics, as was done in the first patient, more rapid flow changes can be detected than with clearance technics which require prolonged collection periods.

Arteriovenous fistula may cause high-output cardiac failure especially in elderly persons with already diminished myocardial reserve.[10, 14, 17, 18] Cardiac failure also may occur with a normal or even a reduced cardiac output when there is preexisting myocardial functional impairment.[14, 17] Under certain circumstances hemodynamic studies can be the determining factor in the choice of therapy. For example, surgical correction of an arteriovenous fistula would be indicated in an aged person with high output cardiac failure. However, surgery may not be indicated if cardiac failure is absent or easily corrected with conventional medical therapy, if cardiac output is only slightly elevated, or if the patient's clinical condition is poor.

Despite clinical signs of arteriovenous fistula, the diagnosis may be overlooked, as in the first patient, who had undergone cardiac catheterization four years previously because of suspected congenital heart disease. Hemodynamic studies were consistent with arteriovenous fistula, and she demonstrated the typical physiological responses to closure of the fistula. Postoperatively, hemodynamic studies indicated incomplete repair (cardiac output 7.2 liters per min), which was later confirmed by arteriography.

Superior mesenteric artery to portal vein fistula is an unusual location for traumatic fistula.[19, 20] There has been one report[21] suggesting that a fistula in this location is not associated with increased cardiac output; however, in our patient cardiac output was increased.

Congenital arteriovenous fistulas generally show physiological alterations similar to those produced by trauma. However, the changes develop gradually and are associated with a rather lengthy period of adaptation. Moreover, in congenital fistulas the arteriovenous communications are usually multiple in contrast with those in the acquired type which are less extensive. Furthermore, the congenital type can also cause heart failure, especially in children.[22-24] In Case 3, the patient with congenital and surgically-induced arteriovenous fistulas provided an unusual opportunity to study natural and induced arteriovenous fistulas. The surgically-created fistula in the normal leg further increased the cardiac output over the already elevated output resulting from the congenital fistula. Follow-up studies of this patient with both fistulas, opened and closed, provided an excellent demonstration of the pathologically-induced hemodynamic changes.

Hamartoma (Case 4) is an example of an acquired arteriovenous fistula in a congenital vascular anomaly. More frequent evaluation of the systemic hemodynamic changes in such patients would provide valuable information on the size of the shunt and its physiological effects. Thus, an increase in cardiac output may be a most important factor in making a decision in regard to surgery, and a decrease postoperatively an indicator of the success of the operation.

Arteriovenous fistulas have been observed in a variety of malignant tumors not of vascular origin,[25-27] although hypernephroma is the one most often associated with a hyperkinetic circulation.[28-32] In Case 5, the patient with metastatic hypernephroma presents an example of such a vascular tumor associated with an elevated cardiac output. Since many primary and metastatic neoplasms are highly vascular, arteriography has been most helpful in determining the extent and size of such tumors, and the increased and abnormal vascularization is often diagnostic for malignancy.

A hyperkinetic circulatory state has been found in patients with polyostotic fibrous dysplasia[33-36] and Paget's disease.[36-41] Histopathologic studies in both diseases show innumerable small vessels within the lesions, and the hyperkinetic syndrome results, therefore, from numerous arteriovenous shunts by these small vessels. By analogy, it would seem worthwhile to perform hemodynamic studies in patients who have other diseases associated with similar vascular changes, for example hemangiomas, and familial hemorrhagic telangiectases (Osler's disease).

## Conclusion

The physiological significance of abnormal arteriovenous communications and the need for medical therapy or corrective surgery are based

upon arteriographic and hemodynamic findings. Moreover, postoperative studies may reveal information concerning the success or failure of attempts to correct surgically the hyperkinetic state. Finally, periodic studies may be of great value in those diseases known to be associated with numerous arteriovenous shunts through only or predominantly small vessels; under such circumstances, early evidence of developing hyperkinetic circulation may be detected and potential cardiac decompensation may be anticipated.

## Summary

Seven patients with hyperkinetic cardiovascular states resulting from abnormal and unusual arteriovenous communications are reported herein. The abnormalities demonstrated by angiography or by biopsy include: a posttraumatic deep femoral arteriovenous fistula, superior mesenteric artery-portal vein fistula, congenital femoral arteriovenous fistula with contralateral surgically-induced arteriovenous fistula, vascular hamartoma, metastatic hypernephroma, Paget's disease, and fibrous dysplasia of bone. Preoperative hemodynamic studies provided useful information concerning the significance of the abnormalities, and thereby provided a means for determining the physiological need for corrective surgery. Postoperative studies revealed information concerning the preoperative hyperkinetic state.

## References

1. Frohlich, E. D.; Ulrych, M.; Tarazi, R. C.; Dustan, H. P., and Page, I. H.: A hemodynamic comparison of essential and renovascular hypertension. Cardiac output and total peripheral resistance: supine and tilted patients. Circulation **35:** 289–297, 1967.
2. Frohlich, E. D.; Tarazi, R. C.; Ulrych, M.; Dustan, H. P., and Page, I. H.: Tilt test for investigating a neural component in hypertension. Its correlation with clinical characteristics. Circulation **36:** 387–393, 1967.
3. Cohn, J. N., and Gombos, E. A.: Unilateral renal hemodynamics studied by an indicator-dilution technic in man. Am. J. Cardiol. **16:** 820–827, 1965.
4. Nicoladoni, C.: Phlebarteriectasie der Rechten Oberen Extremität. Arch. klin. Chir. **18:** 252–274, 1875.
5. Branham, H. H.: Aneurismal varix of the femoral artery and vein following a gunshot wound. Internat. J. Surg. **3:** 250–251, 1890.
6. Nickerson, J. L.; Elkin, D. C., and Warren, J. V.: The effect of temporary occlusion of arteriovenous fistulas on heart rate, stroke volume, and cardiac output. J. Clin. Invest. **30:** 215–219, 1951.
7. Holman, E.: Arteriovenous Aneurysm. Abnormal communications between the arterial and venous circulations. New York: Macmillan Company, 1937.
8. Warren, J. V.; Nickerson, J. L., and Elkin, D. C.: The cardiac output in patients with arteriovenous fistulas. J. Clin. Invest. **30:** 210–214, 1951.
9. Warren, J. V.; Elkin, D. C., and Nickerson, J. L.: The blood volume in patients with arteriovenous fistulas. J. Clin. Invest. **30:** 220–226, 1951.
10. Holman, E.: Abnormal arteriovenous communications. Great variability of effects with particular reference to delayed development of cardiac failure. Circulation **32:** 1001–1009, 1965.

11. Epstein, F. H., and Ferguson, T. B.: The effect of the formation of an arteriovenous fistula upon blood volume. J. Clin. Invest. **34:** 434–438, 1955.

12. Holman, E.: The vicissitudes of an idea. The significance of total blood volume in the story of arteriovenous fistula. Rev. Surg. **20:** 153–174, 1963.

13. Guyton, A. C., and Sagawa, K.: Compensations of cardiac output and other circulatory functions in areflex dogs with large A-V fistulas. Am. J. Physiol. **200:** 1157–1163, 1961.

14. Maldonado, J. E.; Sheps, S. G.; Bernatz, P. E.; DeWeerd, J. H., and Harrison, E. G.: Renal arteriovenous fistula. A reversible cause of hypertension and heart failure. Am. J. Med. **37:** 499–513, 1964.

15. Kramer, M. L., and Kahn, J. W.: Effect of atropine on the Branham sign in arteriovenous fistula. Arch. Intern. Med. **78:** 28–30, 1946.

16. Epstein, F. H.; Post, R. S., and McDowell, M.: The effect of an arteriovenous fistula on renal hemodynamics and electrolyte excretion. J. Clin. Invest. **32:** 233–241, 1953.

17. Spurny, O. M., and Pierce, J. A.: Cardiac output in systemic arteriovenous fistulas complicated by heart failure. Am. Heart J. **61:** 21–24, 1961.

18. Dorney, E. R.: Peripheral A-V fistula of fifty-seven years' duration with refractory heart failure. Am. Heart J. **54:** 778–781, 1957.

19. Sumner, R. G.; Kistler, P. C.; Barry, W. F., Jr., and McIntosh, H. D.: Recognition and surgical repair of superior mesenteric arteriovenous fistula. Circulation **27:** 943–950, 1963.

20. Stone, H. H.; Jordan, W. D.; Acker, J. J., and Martin, J. D., Jr.: Portal arteriovenous fistulas. Am. J. Surg. **109:** 191–196, 1965.

21. Murray, M. J.; Thal, A. P., and Greenspan, R.: Splenic arteriovenous fistulas as cause of portal hypertension. Am. J. Med. **29:** 849–856, 1960.

22. Glatt, B. S., and Rowe, R. D.: Cerebral arteriovenous fistula associated with congestive heart failure in the newborn; report of two cases. Pediatrics **26:** 596–603, 1960.

23. Levine, O. R.; Jameson, A. G.; Nelhaus, G., and Gold, A. P.: Cardiac complications of cerebral arteriovenous fistula in infancy. Pediatrics **30:** 563–575, 1962.

24. Cooper, A. G., and Bolande, R. P.: Multiple hemangiomas in an infant with cardiac hypertrophy; postmortem angiographic demonstration of the arteriovenous fistulae. Pediatrics **35:** 27–35, 1965.

25. Nalle, B. C., Jr.: Distant metastases of 58 renal neoplasms; case report of secondary metastatic pulsations from renal tumor. J. Urol. **57:** 662–668, 1947.

26. Storstein, O.: Circulatory failure in metastatic carcinoma of the lung; physiologic and pathologic study of its pathogenesis. Circulation **4:** 913–919, 1951.

27. Pierce, J. A.; Reagan, W. P., and Kimball, R. W.: Unusual cases of pulmonary arteriovenous fistulas, with a note on thyroid carcinoma as a cause. N. Engl. J. Med. **260:** 901–907, 1959.

28. Zucker, G., and Levine, J.: Pulsating metastasis of the femur from a silent hypernephroma. Ann. Intern. Med. **48:** 897–902, 1958.

29. Scheifley, C. H.; Daugherty, G. W.; Greene, L. F., and Priestley, J. T.: Arteriovenous fistula of the kidney; new observations and report of three cases. Circulation **19:** 662–671, 1959.

30. Caplan, H. I.; Sparkes, R. S.; Lemay, M. J., and Mahony, D.: Arteriovenous shunt produced by metastatic hypernephroma. J.A.M.A. **177:** 788–790, 1961.

31. Abbot, C. E., and Poutasse, E. F.: Renal arteriovenous fistula; occurrence in renal-cell carcinoma. Report of a case. Cleve. Clin. Q. **28:** 283–288, 1961.

32. Vetto, R. M.; Bigelow, J. C., and Dueger, W. C., Jr.: Arteriovenous fistula in pulsatile metastatic carcinoma. Report of chronic heart failure relieved by resection. Am. Surg. **32:** 557–560, 1966.

33. McIntosh, H. D.; Miller, D. E.; Gleason, W. L., and Goldner, J. L.: The circulatory dynamics of polyostotic fibrous dysplasia. Am. J. Med. **32:** 393–403, 1962.

34. Benedict, P. H.: Endocrine features in Albright's syndrome (fibrous dysplasia of bone.) Metabolism **11:** 30–45, 1962.

35. Moldawer, M., and Rabin, E.: Polyostotic fibrous dysplasia with thyrotoxicosis. Report of a complete autopsy and skeletal reconstruction. Arch. Intern. Med. **118:** 379–384, 1966.

36. Reifenstein, E. C., Jr., and Albright, F.: Paget's disease: its pathologic physiology and the importance of this in the complications arising from fracture and immobilization. N. Engl. J. Med. **231:** 343–355, 1944.

37. Sornberger, C. F., and Smedal, M. I.: The mechanism and incidence of cardiovascular changes in Paget's disease (osteitis deformans). Circulation **6:** 711–726, 1952.

38. Edholm, O. G., and Howarth, S.: Studies on the peripheral circulation in osteitis deformans. Clin. Sci. **12:** 277–291, 1953.

39. Storsteen, K. A., and Janes, J. M.: Arteriography vascular studies in Paget's disease of bone. J.A.M.A. **154:** 472–474, 1954.

40. Lequime, J., and Denolin, H.: Circulatory dynamics in osteitis deformans. Circulation **12:** 215–219, 1955.

41. Alpert, S.: Cardiovascular complications of Paget's disease; a case report. Ann. Intern. Med. **48:** 871–876, 1958.