

# Urticaria and angioedema

ANDREW E. DAVIDSON, MD; S. DAVID MILLER, MD; GUY SETTIPANE, MD; DONALD KLEIN, MD

■ Urticaria and angioedema are commonly seen in the outpatient setting. Their pathogenesis involves complex cellular and humoral factors. Diagnosis depends on historical information such as duration of symptoms, exacerbating factors, and atopy. While many etiologic factors have been implicated, in most chronic cases no specific etiology is found. This article reviews physical and hereditary syndromes and discusses therapeutic regimens based on the duration and severity of symptoms.

□ INDEX TERMS: URTICARIA; ANGIONEUROTIC EDEMA □ CLEVE CLIN J MED 1992; 59:529-534

**T**HE RELATIVELY COMMON clinical syndromes of urticaria and angioedema present challenging problems for the practicing physician. Although a spectrum of diverse factors has been implicated in their etiology, in most chronic cases no specific etiologic factor is found. The resulting diagnosis is "idiopathic urticaria."

Urticaria is characterized by erythematous, pruritic, cutaneous elevations that blanch with pressure. The lesions may occur anywhere on the body. Biopsy of acute lesions reveals dilated small venules and capillaries in the superficial dermis. Chronic lesions contain non-necrotizing perivascular mononuclear cell infiltrates, including T cells, monocytes, and mast cells.<sup>1</sup>

Clinically, urticaria and angioedema are not distinct: they frequently occur together.<sup>2,3</sup> Angioedema of the deep dermal and subcutaneous tissues frequently involves the face, tongue, extremities, and genitals. Laryngeal edema may be life-threatening.

## PATHOGENESIS

Antibodies, inflammatory cells, complement, histamine, kinins, cytokines, and prostaglandins have all been implicated in the pathogenesis of urticaria and angioedema (Figure).<sup>2,4,5</sup> Immunoglobulin E (IgE)-

mediated histamine release from cutaneous mast cells and basophils is thought to be the primary event in allergic urticaria (as seen in food allergies and IgE-mediated drug reactions).<sup>4,6</sup> In response to specific antigens or nonspecific stimuli, mast cells release prostaglandin D<sub>2</sub>, leukotrienes C<sub>4</sub> and D<sub>4</sub>, and platelet-activating factor, which cause vasodilation and increased vascular permeability.<sup>4,7</sup> Increased vascular permeability then leads to plasma kinin generation via Hageman factor autoactivation.<sup>2,8</sup> Mast cells also release enzymes capable of generating and releasing bradykinin and kallikrein.<sup>2,9</sup>

Complement components C3a, C4a, and C5a are nonspecific factors causing basophil and mast cell histamine release.<sup>6</sup> C5a is a chemotactic factor for eosinophils, monocytes, and neutrophils.<sup>2</sup> C1 esterase inhibitor inhibits kinin formation and digestion of C2 and C4.<sup>10</sup> These factors may play an important role in hereditary and acquired angioedema with C1 esterase inhibitor deficiency (formerly "hereditary angioedema").

Factors released from T lymphocytes and macrophages also cause histamine release from mast cells. Interleukin 3 and granulocyte macrophage colony stimulating factor have been implicated.<sup>11</sup>

A syndrome of urticaria and angioedema with aspirin sensitivity has been described<sup>6</sup> which may involve increased production of leukotrienes secondary to decreased cyclooxygenase activity with shunting of metabolites into the lipoxygenase pathway.<sup>2</sup>

From the Department of Pediatrics and Medicine, Rhode Island Hospital, Providence.

Address reprint requests to A.E.D., Rhode Island Hospital, Department of Pediatrics and Medicine, Division of Allergy, APC 6, 593 Eddy Street, Providence, RI 02903.

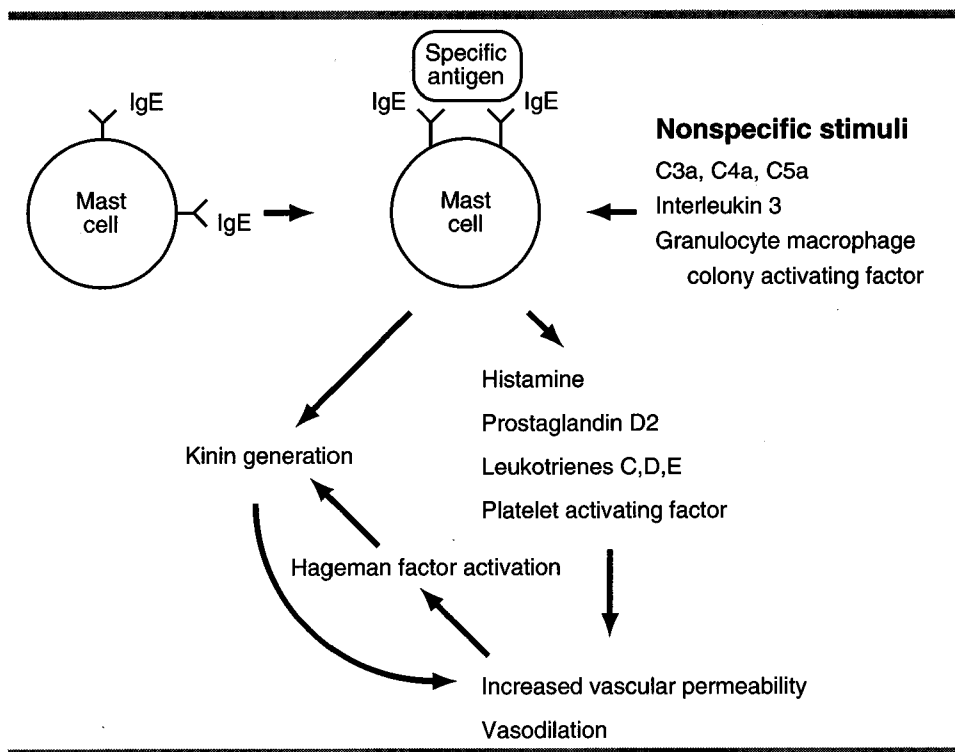


FIGURE. Pathogenesis of urticaria and angioedema.

TABLE 1  
DRUGS IMPLICATED IN ACUTE URTICARIA  
AND ANGIOEDEMA

Amphetamines	Heterologous serum	Phenylbutazone
Angiotensin-converting enzyme inhibitors	Hydralazine	Polymyxin
Aspirin	Insulin	Probenecid
Atropine	Iodinated contrast dye	Procaine
Barbiturates	Isoniazid	Protamine Sulfate
Cephalosporins	Narcotics	Quinine
Chymotrypsin	Nitrofurantoin	Streptokinase
Curare	Nonsteroidal anti-inflammatory drugs	Sulfonamides
Cyanocobalamin	Pancreatin	Suxamethonium
Deferoxamine	Pancuronium	Tartrazine dye
Dextran	Papain	Thiamine
Furosemide	Penicillins	Thiouracil
Gallamine	Phenothiazines	d-Tubocurarine

CLINICAL SYNDROMES

Acute urticaria

Urticaria and angioedema are prevalent, affecting 10% to 20% of the population at some time in their lives.<sup>2,3</sup> The symptoms are transient in most patients and resolve with symptomatic treatment. Drug reactions, both IgE- and non-IgE-mediated, are frequently

implicated. Reactions to penicillins, sulfonamides, analgesics, contrast dye, sedatives, and diuretics are common (Table 1).<sup>2,12,13</sup> Angiotensin-converting enzyme inhibitors have been associated with angioedema, with increased kinin production as a postulated mechanism.<sup>14</sup> Patients with urticaria and aspirin sensitivity may also react to other nonsteroidal anti-inflammatory drugs (indomethacin, ibuprofen) and tartrazine dye.<sup>15</sup> These patients may tolerate salsalate or choline magnesium trisalicylate, but some cross-reactivity has been reported.<sup>16</sup> Patients with potentially life-threatening reactions of angioedema and anaphylaxis should avoid all nonsteroidal anti-inflammatory drugs.<sup>2</sup>

Foods, including shellfish, nuts, eggs, and milk, are common causes of acute urticaria and angioedema but only rarely cause chronic problems.<sup>2</sup> Viral infections, particularly in children, have been associated with acute urticaria.<sup>17</sup> Seasonal allergen exposure in atopic patients occasionally results in urticaria.<sup>3,6</sup> Allergic reactions to Hymenoptera venom may result in urticaria or angioedema.<sup>18,19</sup> Transfusion reactions have also been associated with acute onset of urticaria and angioedema.<sup>2</sup>

Chronic urticaria

Urticaria of greater than 6 weeks' duration is chronic. In most cases no etiologic factor is found, despite investigation of the patient's history, physical examination, and laboratory evaluation.<sup>2,3</sup>

An urticarial rash can develop in patients with systemic vasculitis in conjunction with Sjögren's syndrome, systemic lupus erythematosus, polyarteritis nodosa, rheumatoid arthritis, cryoglobulinemia, or serum sickness. Untreated infections, particularly viral hepatitis, infectious mononucleosis, and helminthic parasitic infections, have been associated with urticaria.<sup>6,20-22</sup> Cases of urticaria with bacterial and fungal

**TABLE 2**  
PHYSICAL SYNDROMES OF URTICARIA AND ANGIOEDEMA

Disorder	Symptoms	Diagnosis	Passive transfer	Therapy	Special characteristics	Reference
Acquired cold urticaria	Localized wheal or systemic urticaria with or without angioedema,	Ice cube test	Positive in some cases	Cyproheptadine	Rarely associated with cryoglobulins, cryofibrinogens, paroxysmal cold hemoglobinuria, Donath-Landsteiner antibody	2,6,26, 27,32
Familial cold urticaria	Erythematous burning patches or papules with pyrexia, leukocytosis, arthralgias	History	Negative	Avoidance, responds poorly to antihistamines	Autosomal dominant inheritance	2,6
Cholinergic urticaria	Multiple 1-2 mm wheals occur with exertion, perspiration, anxiety	Exercise test, mecholy skin test	—	May respond to hydroxyzine	Overlap with syndromes of exercise-induced anaphylaxis and food-related exercise-induced anaphylaxis	3,6,27, 28,29, 30,32
Delayed pressure urticaria	Local swelling, erythema, and pain 4-6 hours after pressure	Sling test	—	Avoidance, responds poorly to antihistamines	Occurs in patients with chronic idiopathic urticaria	6,30
Symptomatic dermographism	Stroking skin produces wheal and flare	Dermographometer	Positive	Hydroxyzine, cyproheptadine, terfenadine	Can be seen in control subjects	6,31,32
Solar urticaria	Erythema, pruritus, papules or wheals	Monochrometer	Positive in some patients	Sunscreens, avoidance	Different patients are sensitive to different wavelengths of light, erythropoietic protoporphyria should be excluded	6,26, 27, 32-34
Vibratory angioedema	Edema at site of vibration	Vortex vibration of forearm for 5 minutes	Negative	Avoidance response to antihistamine is variable	Autosomal dominant hereditary form reported	30,32
Aquagenic urticaria	Pruritic wheals on upper body	Water compress at body temperature	—	Terfenadine hydroxyzine	Other syndromes should be ruled out	30,32

infections have been reported.<sup>23</sup> Malignancies associated with urticaria include carcinoma of the colon, rectum, and lung, B-cell lymphoma, and Hodgkin's lymphoma.<sup>2</sup> Urticaria can occur with hyperthyroidism and, rarely, with hypothyroidism.<sup>2,24</sup>

In urticaria pigmentosa, brown cutaneous macules are present which urticate with stroking (Darier's sign). This disease is primarily seen in children and often resolves prior to adulthood. When diffuse cutaneous involvement is present, or when adult onset of the disease occurs, systemic mastocytosis should be suspected. In the latter disease, mast cell infiltration of the skeletal system, liver, spleen, and lymph nodes may accompany skin involvement. Overall, 90% of patients with mast cell disease have urticaria pigmentosa limited to the skin.<sup>25</sup>

Syndromes of physical and hereditary urticaria and angioedema are rare but interesting causes of chronic disease. The physical syndromes are summarized in Table 2.

### Hereditary syndromes

Several familial syndromes of urticaria or angioedema have been described. Familial cold urticaria is an autosomal-dominant syndrome of cold intolerance. Patients develop papular skin lesions, burning, fever, chills, arthralgias, myalgias, headache, and leukocytosis approximately 30 minutes after cold exposure. This systemic disorder is clinically distinct from the sporadic form of cold urticaria.<sup>2,6</sup>

Hereditary angioedema is an autosomal-dominant deficiency of C1 esterase inhibitor activity. The disease is characterized by attacks of nonpruritic swelling involving the gastrointestinal, respiratory, and genitourinary tracts. While patients commonly have edema of the face and extremities, they do not develop urticaria. Attacks usually last 3 to 4 days. Acute exacerbations have been associated with trauma. While most patients have low or absent levels of the C1 esterase inhibitor protein, 15% to 20% of patients have normal levels of an inactive protein. C4 levels are low during

**TABLE 3**  
LABORATORY EVALUATION OF CHRONIC URTICARIA

<i>Standard tests</i>	
Complete blood count with differential	
Chest radiography	
Erythrocyte sedimentation rate	
Rheumatoid factor	
Antinuclear antibody	
VDRL test	
Stool ova and parasites	
Thyroid function tests	
<i>Tests in selected patients</i>	
Skin biopsy	
Skin testing	
C1 esterase inhibitor	
C4	
Heterophil agglutinins (Monospot)	
Hepatitis B surface antigen	
Ice cube test (cold urticaria)	
Exercise test (cholinergic urticaria)	
Sling test (pressure urticaria)	
Darier's sign (urticaria pigmentosa)	

asymptomatic periods and extremely low during acute attacks. C2 levels may be low during acute attacks but are otherwise normal. Cases of acquired C1 esterase inhibitor deficiency have been associated with systemic lupus erythematosus, B-cell lymphoma, and carcinoma. Anti-C1 esterase inhibitor IgG and IgA autoantibodies have recently been reported as a cause of acquired disease.<sup>2,3,6,35,36</sup>

Other hereditary syndromes include autosomal-dominant hereditary vibratory angioedema, C3b inactivator deficiency which appears to be autosomal-recessive,<sup>37,38</sup> and an autosomal-dominant condition of urticaria and amyloidosis.<sup>39,40</sup>

### Chronic idiopathic urticaria

In the great majority of patients with chronic urticaria (80% to 95% in some series), the condition is idiopathic.<sup>2,3</sup> The differential diagnosis includes syndromes mentioned above, including urticaria secondary to systemic diseases, physical and hereditary syndromes, and vasculitis. Food additives such as butylated hydroxyanisole and butylated hydroxytoluene have been implicated in rare cases.<sup>41</sup> Psychological factors and emotional stress may aggravate the condition in some patients.<sup>2</sup> Papular urticaria on the extremities of small children can be related to recurrent insect bites.<sup>2,3</sup>

Since chronic urticaria may be related to systemic disease, a search for an underlying cause should be undertaken. The workup should include history and physical, chest radiography, complete blood count,

erythrocyte sedimentation rate, VDRL test, antinuclear antibody (ANA) test, rheumatoid factor, stool examination for ova and parasites, and thyroid function tests (Table 3).<sup>2,42</sup> In selected cases, skin biopsy may be helpful to rule out a vasculitic process, particularly in the presence of arthralgias, myalgias, purpura, or an abnormal erythrocyte sedimentation rate, ANA test, or rheumatoid factor. Skin testing for food allergens may help rule out food allergy.<sup>43,44</sup> Patients with idiopathic urticaria should have normal leukocyte count, sedimentation rate, and IgE levels. The incidence of atopic disease is not increased in patients with idiopathic urticaria.

The course and prognosis of chronic idiopathic urticaria is highly variable. Symptoms vary from mild to severe and debilitating and may resolve spontaneously. While about 50% of patients are free of symptoms after 1 year, other patients have disease that may persist for decades.<sup>2,3,32</sup>

### TREATMENT

Antihistamines are the treatment of choice for urticaria or angioedema in the absence of respiratory or circulatory compromise. Hydroxyzine, cyproheptadine, and diphenhydramine have been used extensively. For patients with acute urticaria, symptomatic treatment with antihistamines may be the only therapy required. The nonsedating antihistamines terfenadine and astemizole effectively treat chronic urticaria without the unwanted side effect of sedation.<sup>45-47</sup> Ketotifen, an H-1 antagonist with mast cell stabilizing properties, is also effective; however, it is not yet approved for use in the United States.<sup>48</sup>

Combinations of H-1 and H-2 antagonists have been recommended for patients with symptoms that resist H-1 antagonist therapy alone.<sup>32</sup> While some controlled studies of H-2 antagonists have shown benefit, results of other trials have been less encouraging.<sup>49</sup> A therapeutic trial of an H-2 antagonist is not unreasonable, since cimetidine and ranitidine are generally well tolerated.

Doxepin, a tricyclic antidepressant with potent H-1 and H-2 antagonist properties, is effective in treating chronic idiopathic urticaria at the relatively low dose of 25 mg tid.<sup>32,50,51</sup> Its adverse effects include lethargy, dry mouth, and constipation, but therapy is generally well tolerated.<sup>50</sup> A trial of doxepin may be considered when chronic urticaria is resistant to H-1 antagonists, particularly when psychological factors are thought to be involved.

Occasionally, chronic urticaria can be severe and debilitating. If this type of disease is resistant to H-1 and H-2 antagonists, a trial of corticosteroids should be considered. One regimen starts with prednisone 40 mg daily for 3 days followed by a 5 mg/day decrease. When the dose is at 25 mg/day, it is then decreased by 5 mg/day on alternate days until a dose of 25 mg qod is reached. Patients may then decrease the 25 mg qod dose by 5 mg every 2 weeks depending on symptom recurrence.<sup>2</sup> Physicians prescribing corticosteroids should be aware of their potential long-term side effects, and patients should be educated about these effects. Systemic corticosteroid therapy should not be used routinely for managing chronic idiopathic urticaria, since the side effects in most patients are out of proportion to potential benefits.<sup>32,51</sup>

In two recent placebo-controlled trials, calcium-channel antagonists were effective in treating urticaria that was unresponsive to antihistamines.<sup>52,53</sup> The effect is thought to result from the inhibition of calcium-influx-dependent mast cell histamine release. However, these studies involved only small numbers of patients; further studies are indicated, and the use of calcium-channel antagonists for the treatment of urticaria should be considered experimental at this time.

If patients present with respiratory symptoms,

hypotension, or anaphylaxis, parenteral epinephrine should be administered immediately. These patients should carry kits for epinephrine self-administration in case of recurrence.

Patients with C1 esterase inhibitor deficiency may present with life-threatening laryngeal edema which may not respond to epinephrine therapy.<sup>54</sup> Administration of concentrated C1 esterase inhibitor or fresh frozen plasma can reverse the deficiency acutely.<sup>55</sup> Maintenance infusion of C1 esterase inhibitor concentrate has shown promise for preventing acute exacerbations.<sup>56,57</sup> Maintenance therapy with anabolic steroids (stanozolol, danazol) has been effective in reducing the incidence of acute attacks with minimal toxicity.<sup>58,59</sup>

#### SUMMARY

Urticaria and angioedema represent diverse clinical syndromes that range from mild irritation and discomfort to life-threatening systemic illness. In most cases, a specific etiology is not found. While disease limited to the skin can often be controlled with antihistamines, corticosteroids may be required for resistant symptoms. Patients with respiratory compromise or anaphylaxis should be treated with epinephrine.

#### REFERENCES

- Elias J, Boss E, Kaplan AP. Studies of the cellular infiltrates of chronic idiopathic urticaria: prominence of T-lymphocytes, monocytes and mast cells. *J Allergy Clin Immunol* 1986; **78**:914-918.
- Kaplan AP. Urticaria and angioedema. In: Middleton E, Reed C, Ellis E, editors. *Allergy Principles and Practice*. 3rd ed. St. Louis: CV Mosby, 1988:1377-1401.
- Kaplan AP. Urticaria and angioedema. In: Kaplan AP, editor. *Allergy*. New York: Churchill Livingstone, 1985:439-471.
- White MV. The role of histamine in allergic diseases. *J Allergy Clin Immunol* 1990; **86**:599-605.
- Kaplan AP, Horakova Z, Katz SI. Assessment of tissue fluid histamine in patients with urticaria. *J Allergy Clin Immunol* 1978; **61**:350-354.
- Kaplan AP, Buckley RH, Mathews KP. Allergic skin disorders. *JAMA* 1987; **258**:2900-2909.
- Schleimer RP, Macglashan DW Jr, Peters SP, Pinckard RN, Adkinson NF, Lichtenstein LM. Characterization of inflammatory mediator release from purified human lung mast cells. *Am Rev Respir Dis* 1986; **133**:614-617.
- Silverberg M, Dunn JT, Garen L, Kaplan AP. Autoactivation of human Hageman factor. Demonstration utilizing a synthetic substrate. *J Biol Chem* 1980; **255**:7281-7286.
- Proud D, Macglashan DW, Newball HH, Schulman ES, Lichtenstein LM. Immunoglobulin E-mediated release of a kininogenase from purified human lung mast cells. *Am Rev Respir Dis* 1985; **132**:405-408.
- Fields T, Ghebrehwet B, Kaplan AP. Kinin formation in hereditary angioedema plasma: evidence against kinin derivation from C2 and in support of "spontaneous" formation of bradykinin. *J Allergy Clin Immunol* 1983; **72**:54-60.
- Haak-Frendscho M, Arai N, Arai K, Baeza ML, Finn A, Kaplan AP. Human recombinant granulocyte-macrophage colony stimulating factor and interleukin 3 cause basophil histamine release. *J Clin Invest* 1988; **82**:17-20.
- Patterson R, DeSwarte RD, Greenberger PA, Grammer LC. Drug allergy and protocols for management of drug allergies. *Allergy Proc* 1986; **7**:325-342.
- Anderson JA, Adkinson NF Jr. Allergic reactions to drugs and biologic agents. *JAMA* 1987; **258**:2891-2899.
- Orfan N, Patterson R, Dykewicz MS. Severe angioedema related to ACE inhibitors in patients with a history of idiopathic angioedema. *JAMA* 1990; **264**:1287-1289.
- Settipane GA, Pudupakkam RK. Aspirin intolerance. III. Subtypes, familial occurrence, and cross-reactivity with tartrazine. *J Allergy Clin Immunol* 1975; **56**:215-221.
- Stevenson DD, Hougham BA, Schrank PJ, Goldlust MB, Wilson RR. Salsalate cross-sensitivity in aspirin-sensitive patients with asthma. *J Allergy Clin Immunol* 1990; **86**:749-758.
- Shapiro GG. Urticaria and angioedema. In: Bierman CW, Pearlman DS, editors. *Allergic diseases of infancy, childhood and adolescence*. Philadelphia: WB Saunders, 1980:440-446.
- Hunt KJ, Valentine MD, Sobotka AK, Benton AW, Amodio FJ, Lichtenstein LM. A controlled trial of immunotherapy in insect hypersensitivity. *N Engl J Med* 1978; **299**:157-161.
- Settipane GA, Boyd KG. Anaphylaxis from insect stings. Myths, controversy, and reality. *Postgrad Med* 1989; **86**:273-281.

20. Cowdrey SC, Reynolds JS. Acute urticaria in infectious mononucleosis. *Ann Allergy* 1969; **27**:182-187.
21. Lockshin NA, Hurley H. Urticaria as a sign of viral hepatitis. *Arch Derm* 1972; **105**:570-571.
22. Koehn GG, Thorne EG. Urticaria and viral hepatitis. *Arch Derm* 1972; **106**:422.
23. Shelley WB. Urticaria of nine year's duration cleared following dental extraction. *Arch Derm* 1969; **100**:324-325.
24. Issacs NJ, Ertel NH. Urticaria and pruritus: uncommon manifestations of hyperthyroidism. *J Allergy Clin Immunol* 1971; **48**:73-81.
25. Johnson ML. Mast cell disease. In: Wyngaarden JB, Smith LH, editors. *Cecil textbook of medicine*. 17th ed. Philadelphia: WB Saunders, 1985:2271.
26. Houser DD, Arbesman CE, Ito K, Wicher K. Cold urticaria. Immunologic studies. *Am J Med* 1970; **49**:23-33.
27. Kaplan AP, Gray L, Shaff RE, Horakova Z, Beaven MA. In vivo studies of mediator release in cold urticaria and cholinergic urticaria. *J Allergy Clin Immunol* 1975; **55**:394-402.
28. McNeil D, Strauss RH. Exercise-induced anaphylaxis related to food intake. *Ann Allergy* 1988; **61**:440-442.
29. Armentia A, Martin-Santos JM, Bianco M, Carretero L, Puyo M, Barber D. Exercise-induced anaphylactic reaction to grain flours. *Ann Allergy* 1990; **65**:149.
30. Casale TB, Sampson HA, Hanifin J, et al. Guide to physical urticarias. *J Allergy Clin Immunol* 1988; **82**:758-763.
31. Garofalo J, Kaplan AP. Histamine release and therapy of severe dermatographism. *J Allergy Clin Immunol* 1981; **68**:103.
32. Soter NA. Chronic urticaria. In: Lichtenstein LM, Fauci AS, editors. *Current therapy in allergy, immunology and rheumatology*. 3rd ed. Philadelphia: BC Decker, 1988:60-62.
33. Ramsay CA. Solar urticaria. *Int J Dermatol* 1980; **19**:233-236.
34. Sams WM, Epstein JH, Winkelmann RK. Solar urticaria. Investigation of pathogenetic mechanisms. *Arch Derm* 1969; **99**:390-397.
35. Frank MM, Gelfand JA, Atkinson JP. Hereditary angioedema: the clinical syndrome and its management. *Ann Int Med* 1976; **84**:580-593.
36. Alsenz J, Bork K, Loos M. Autoantibody-mediated acquired deficiency of C1 inhibitor. *N Engl J Med* 1987; **316**:1360-1366.
37. Alper CA, Abramson N, Johnston RB, Jandl JH, Rosen FS. Increased susceptibility to infection associated with abnormalities of complement-mediated functions and of the third component of complement (C3). *N Engl J Med* 1970; **282**:349-353.
38. Alper CA, Rosen FS, Lachmann PJ. Inactivator of the third component of complement as an inhibitor in the properdin pathway. *Proc Natl Acad Sci U S A* 1972; **69**:2910-2913.
39. Black JT. Amyloidosis, deafness, urticaria, and limb pains: a hereditary syndrome. *Ann Int Med* 1969; **70**:989-994.
40. Warin RP, Champion RH. Urticaria. In: Rook A, editor. *Philadelphia: WB Saunders*, 1974:113-119.
41. Goodman DL, McDonnell JT, Nelson HS, Vaughan TR, Weber RW. Chronic urticaria exacerbated by the antioxidant food preservatives, butylated hydroxyanisole (BHA) and butylated hydroxytoluene (BHT). *J Allergy Clin Immunol* 1990; **86**:570-575.
42. Fineman SM. Urticaria and angioedema. In: Lawlor GJ, Fischler TJ, editors. *Manual of allergy and immunology*. 2nd ed. Boston: Little, Brown and Company, 1988:214-224.
43. Atkins FM, Steinberg SS, Metcalfe DD. Evaluation of immediate adverse reactions to foods in adult patients. I. Correlation of demographic, laboratory, and prick skin test data with response to controlled oral food challenge. *J Allergy Clin Immunol* 1985; **75**:348-355.
44. Zimmerman B, Forsyth S, Gold M. Highly atopic children: formation of IgE antibody to food protein, especially peanut. *J Allergy Clin Immunol* 1989; **83**:764-770.
45. Fox RW, Lockey RF, Bukantz SC, Serbousek D. The treatment of mild to severe chronic idiopathic urticaria with astemizole: double-blind and open trials. *J Allergy Clin Immunol* 1986; **78**:1159-1166.
46. Honsinger RW, Thomsen RJ. Prolonged benefit in the treatment of chronic idiopathic urticaria with astemizole. *Ann Allergy* 1989; **65**:194-200.
47. Paul E, Bodekert RH. Comparative study of astemizole and terfenadine in the treatment of chronic idiopathic urticaria. A randomized double-blind study of 40 patients. *Ann Allergy* 1989; **62**:318-320.
48. McClean SP, Arreaza EE, Lett-Brown MA, Grant JA. Refractory cholinergic urticaria successfully treated with ketotifen. *J Allergy Clin Immunol* 1989; **83**:738-741.
49. Theoharides TC. Histamine<sub>2</sub> (H<sub>2</sub>)-receptor antagonists in the treatment of urticaria. *Drugs* 1989; **37**:345-355.
50. Goldsobel AB, Rohr AS, Siegel SC, et al. Efficacy of doxepin in the treatment of chronic idiopathic urticaria. *J Allergy Clin Immunol* 1986; **78**:867-873.
51. Soter NA. Urticaria: current therapy. *J Allergy Clin Immunol* 1990; **86**:1009-1014.
52. Bressler RB, Sowell K, Huston DP. Therapy of chronic idiopathic urticaria with nifedipine: demonstration of beneficial effect in a double-blinded, placebo-controlled, crossover trial. *J Allergy Clin Immunol* 1989; **83**:756-763.
53. Pigatto PD, Fumagalli M, Bigardi A, Altomare G, Finzi AF. Nimodipine versus terfenadine in the treatment of physical stimulus-induced urticaria. *Allergy* 1990; **45**:71-74.
54. Frigas E. Subspecialty clinics: allergy diseases. Angioedema with acquired deficiency of the C1 inhibitor: a constellation of syndromes. *Mayo Clin Proc* 1989; **64**:1269-1275.
55. Jaffe CJ, Atkinson JP, Gelfand JA, Frank MM. Hereditary angioedema. The use of fresh frozen plasma for prophylaxis in patients undergoing oral surgery. *J Allergy Clin Immunol* 1975; **55**:386-393.
56. Bork K, Witzke G. Long-term prophylaxis with C1-inhibitor (C1 INH) concentrate in patients with recurrent angioedema caused by hereditary and acquired C1-inhibitor deficiency. *J Allergy Clin Immunol* 1989; **83**:677-682.
57. Isenz J, Lambris JD, Bork K, Loos M. Acquired C1 inhibitor (C1-INH) deficiency type II: replacement therapy with C1-INH and analysis of patients C1-INH and anti-C1-INH autoantibodies. *J Clin Invest* 1989; **83**:1794.
58. Sheffer AL, Fearon DT, Austen KF. Hereditary angioedema: a decade of management with stanozolol. *J Allergy Clin Immunol* 1987; **80**:855-860.
59. Hosea SW, Santaella ML, Brown EJ, Berger M, Katusha K, Frank MM. Long-term therapy of hereditary angioedema with danazol. *Ann Int Med* 1980; **93**:809-812.