CLEVELAND CLINIC QUARTERLY
Volume 38, October 1971
Copyright © 1971 by The Cleveland Clinic Foundation
Printed in U.S.A.

Tattooing—history, technics, complications, removal

HENRY H. ROENIGK, JR., M.D.
Department of Dermatology

THE practice of tattooing is an ancient one and worldwide in its distribution. There is evidence of extensive use of painting and scarifying the human body in prehistoric times, but the earliest known tattooing was done in Egypt about 4000 B.C. Such marking was associated with fertility rites, ideas of heaven, and with social status. Moses, in Leviticus XIX:28, forbade tattooing as idolatry, and Arab tribes marked unmarried young girls with a small, blue-cross tattoo on their cheeks. The Romans and Greeks practiced tattooing extensively, as did some of their less civilized contemporaries. Early Christians forbade tattooing, and its popularity declined in the Dark and the Middle Ages. In the late 18th century, Captain Cook reintroduced it to Europe through his contact with Polynesia. One hundred years later, in the 1880's, tattooing enjoyed popularity among European nobility. Princes and kings of many nations, among them Czar Nicholas II, Kaiser Wilhelm II, King Edward VII and Prince George of Greece, elevated tattooing to the realm of high fashion. Even Lady Randolph Churchill had a snake tattooed around her arm.

Why does a person submit to the pain involved in defacing his own skin? Throughout the ages, tattoos have been indulged in as protection against danger, as love charms, to restore youth, to insure good health and long life, to implement fertility, to bring about the death of an enemy, to cure an illness, to divest a corpse of its malevolent powers, to insure a happy afterlife, to propitiate supernatural powers, and to acquire supernatural power.

Present-day tattooing has a different purpose, especially in the United States.[1] Bromberg[2] considered tattooing as being related to emotional immaturity. He believed that it was associated with neurotic behavior of two types of men; the clearly exhibitionist type, often a sailor, and the young man who seeks to counteract his feeling of inferiority by an identification with strong men. Perhaps many otherwise stable individuals permit themselves to be tattooed during an evening of alcoholic celebration early in their military service careers. In Honolulu, during World War II, it was estimated that each day from 300 to 500 men were tattooed.

Technics

The amateur tattoos are usually produced with pinpricks and India ink that sinks into the dermis. Professional tattoo artists employ a special

electric needle or battery of needles. The colors and the pigments most commonly used are as follows:

Colors	*Pigments*
Blue-black	Carbon
Red	Cinnabar (mercuric sulfide) Cadmium selenide Sienna
Light-blue	Cobaltous aluminate
Green	Chromic oxide or Chromium sesquioxide
Yellow	Cadmium sulfide and ochre
Brown	Ochre (iron oxide)
Flesh	Iron oxide plus impurities of ochre
Violet	Manganese
White (ranging from chalk to ivory)	Titanium dioxide

The puncturing of the skin usually is painful, but preoperative sedation by heavy alcohol intake helps to mask the pain. An inflammatory reaction develops and persists for from ten days to three weeks, being usually more severe from the metallic pigments.

The pigment particles, histologically, usually are in the dermis around blood vessels and are mainly extracellular. Most tattoo designs will persist for life, though some of the color will fade with time.

Complications

1. *Infection*

Pyogenic infection. The insanitary technics used by tattoo artists may cause various types of pyoderma, ranging from mild erythema to sepsis and gangrene leading to amputation.

Syphilis. Primary syphilis may appear in a tattoo in the form of a chancre due to direct transmission, via the tattooing needle, of the organisms from an open lesion in an infected tattoo artist. Secondary lesions of syphilis may localize in a tattoo. It was observed in 1906 by Lipschütz[3] that a syphilid would often involve the blue areas of the tattoo but spared the red areas, which were usually cinnabar, a mercurial compound, that suppressed the syphilid.

Tuberculosis. Only a few cases of tuberculosis in tattoos have been re-

ported. The unclean habit of using saliva in the process of coloring would often transmit tuberculosis from the artist to the person being tattooed. Primary inoculation tuberculosis in tattoos occurred after a boy with pulmonary tuberculosis tattooed his brothers and a friend.

Leprosy. Whether or not leprosy can be transmitted by inoculation from one human to another is still not proved. Porritt and Olsen[4] in 1947 reported two cases of leprosy believed to have been transmitted by tattooing. Two United States marines had been tattooed by the same man in Melbourne, Australia, in 1943. In both of the marines, cutaneous maculoanesthetic tuberculoid leprosy developed in their tattoos 2½ years later. The cases were confirmed by the United States Marine Hospital at Carville, Louisiana.

Vaccinia. Vaccination for smallpox can cause so severe an inflammatory reaction as to remove the pigment in the tattoo.

Infectious hepatitis. Smith[5] in 1950 noted that, while making rounds at a military hospital, the most "decorative" ward was the enlisted men's hepatitis section. He found 17 men in whom infectious hepatitis developed from 2 to 5 months after being tattooed at one tattoo parlor in Panama City. The technic of reusing the dye without sterilization was responsible for transmission of hepatitis from one customer to another.

2. *Locus minoris resistantiae*

This refers to the alteration of the area by the tattoo, so as to predispose it to localization of various skin diseases. Examples of this reaction include: discoid lupus erythematosus, psoriasis vulgaris, and lichen planus.

3. *Allergic reactions to pigments*

The most frequent complications of tattoos are the development of allergic hypersensitivity reactions to the chemicals used to produce the various colors in the tattoo. The most commonly seen reaction is in the red portion of the tattoo, which is usually produced by cinnabar, a mercurial compound (*Fig. 1*). The reaction often develops many months or even years after the tattooing, as irritation, swelling, and erythema in a portion of the tattoo.

Treatment with mercurial topical ointments or with diuretics has been postulated as precipitating allergic reactions to cinnabar; however, many reactions develop spontaneously. Skin biopsies often will show a sarcoid-like granuloma. Patch tests to bichloride of mercury, ammoniated mercury, and cinnabar do not give consistently positive reactions. This inconsistency had led some clinicians to conclude that the reaction is not due to cinnabar, but to a derivative compound.

The reaction in the tattoo may persist indefinitely and the patient may require excision of the affected area for relief of the pruritus. However, there may be spontaneous diminution of sensitivity with subsidence of the

reaction.[6] Widespread, exfoliative dermatitis may also occur from the localized reaction in the tattoo.

4. *Photosensitivity reactions to pigments*

Swelling of the yellow or red portions of the tattoo on exposure to sunlight is well known to sailors. Cadmium sulfide, a photosensitive substance used in the production of photoelectric cells, is used to produce the yellow in tattoos. Red tattoos are usually made of cinnabar (mercury sulfide) but also often contain trace amounts of cadmium selenide. Tattoos containing cadmium sulfide will swell when exposed to ultraviolet light in wavelength of 3,800, 4,000, and 4,500 Å.[7] Photopatch tests with cadmium sulfide are negative. The reaction is probably phototoxic.

5. *Miscellaneous reactions*

Verruca vulgaris, keloids, malignant melanoma, and reticulosarcoma have been known to develop at the sites of tattoo inoculation.

Fig. 1. Tattoo with allergic reaction to cinnabar in the red portion.

Methods of removal

Early methods used to remove tattoos included mechanical, chemical, or surgical procedures. The most common method of tattoo removal is simple excision, usually done in several stages, or excision and split-thickness skin grafts.[8, 9] The cosmetic results from these procedures are often unsatisfactory, besides the additional cost of hospitalization, anesthesia, and postoperative therapy.

In modern times, the laser beam has been used experimentally[10] to remove pigmented tattoos, but the rarity and expense of laser beams limit their use.

"Salabrasion" [11] or removal of tattoos by superficial abrasion with table salt is a new "home cookbook" way to remove tattoos.

Dermabrasion

Superficial abrasion of tattoos was described by Janson[12] in 1935. Rosenberg[13] treated an accidental tattoo by abrading it with sandpaper. Stra-

Fig. 2. Tattoo before dermabrasion.

kosch[14] and Loria[15] described their technics of dermabrasion for the removal of professional tattoos.

Dermabrasion into the corium while avoiding descent into the underlying fat tissue can remove most of the pigment without serious cutaneous destruction (*Fig. 2 and 3*). Much of that pigment left within will eventually slough off in the healing process. Other pigment will remain and in time be lost to sight beneath newly formed tissue.

In 1963, Boo-Chai[16] postulated that the superficial dermabrasion of a tattoo resulted in inflammation that caused the biological removal of the tattoo pigment. Clabaugh[17] demonstrated that the pigment was engulfed in macrophages and carried outward through the abraded surface. He thought the inflammatory reaction provoked by dermabrasion of tattoos enhanced phagocytosis of free pigment; the pigment-laden phagocytes then became mobile and migrated to the wound surface where they were deposited on the dressing.

The method of dermabrasion is as follows. The hair is shaved over the area to be dermabraded, and the skin is prepared by a five-minute scrubbing

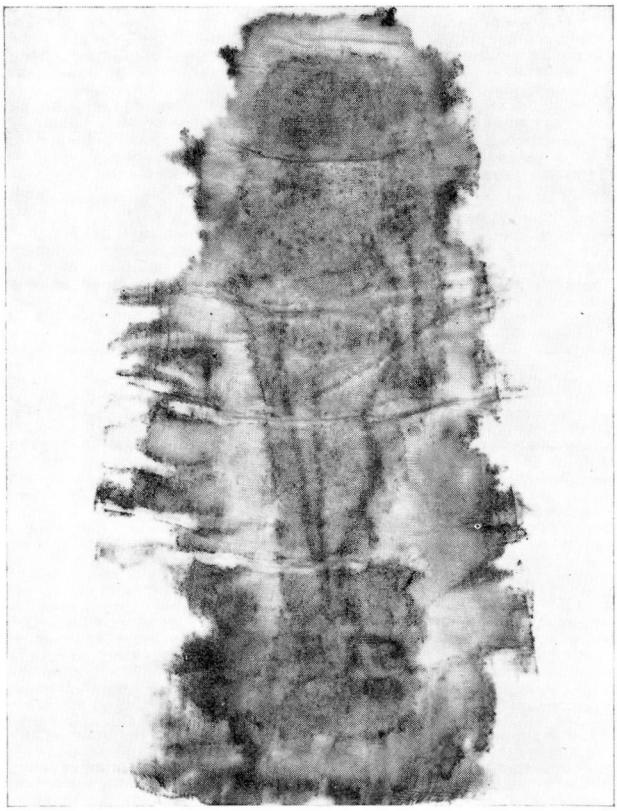

Fig. 3. Dressing removed 24 hours after dermabrasion. Notice how pigment has been absorbed into the dressing.

Fig. 4. One year after dermabrasion of tattoo.

with hexachlorophene soap (pHisoHex). The area of tattoo is anesthesized with 1 percent lidocaine (Xylocaine) subcutaneously injected locally, or frozen with skin refrigerant (Frigiderm), and then superficially dermabraded with a Stricker power unit and a diamond fraise. The dermabrasion is strictly superficial, and only the epidermis and a small amount of dermis are removed. The wound is cleaned and a Vaseline gauze dressing is applied and covered with sterile gauze squares and tape. The dressing is changed daily for about five days and then removed entirely; a crust is allowed to form. If at any time there is a sign of superficial infection, the daily dressings are discontinued. Zephiran chloride solution is used to clean the wound and an antibiotic is topically applied. No gentian violet is used during the preoperative or postoperative period. When pigment remains, the procedure is repeated in six weeks (*Fig. 4*).

Summary

The art of tattooing has been practiced throughout the world for centuries. Methods used by tattoo artists may cause various complications.

These may be local or systemic and are often of an infectious or allergic nature.

References

1. Parry, A.: Tattoo Secrets of a Strange Art as Practiced Among the Natives of the United States. New York, 1933.
2. Bromberg, W.: Psychologic motives in tattooing. Arch. Neurol. Psychiat. **33:** 228–232, 1948.
3. Lipschütz, B.: Verhandlungen der Wiener dermatologischen Gesellschaft. Arch. f. Derm. Syph. **78:** 381,1906.
4. Porritt, R. J., and Olsen, R. E.: Two simultaneous cases of leprosy developing in tattoos. Am. J. Pathol. **23:** 805-817, 1947.
5. Smith, B. F.: Occurrence of hepatitis in recently tattooed service personnel. J.A.M.A. **144:** 1074–1076, 1950.
6. Sulzberger, M. B.; Kanof, A., and Baer, R. L.: Complications following tattooing; sensitization and desensitization to mercury; report of a case. U.S. Nav. Med. Bull. **43:** 889–894, 1944.
7. Bjornberg, A.: Reactions to light in yellow tattoos from cadmium sulfide. Arch. Dermatol. **88:** 267–271, 1963.
8. Buncke, H. J., Jr., and Conway, H.: Surgery of decorative and traumatic tattoos. Plast. Reconstr. Surg. **20:** 67–77, 1957.
9. Bailey, B. N.: Treatment of tattoos. Plast. Reconstr. Surg. **40:** 361-371, 1967.
10. Goldman, L.; Rockwell, R. J., and Meyer, R.: Laser treatment of tattoos. J.A.M.A. **201:** 841–844, 1967.
11. Crittenden, F. M., Jr.: Salabrasion—removal of tattoos by superficial abrasion with table salt. Cutis **7:** 295–300, 1971.
12. Janson, P.: Eine Einfache Methode der Entefernung von Tätowierungen. Dermat. Wchnschr. **29:** 894–895, 1935.
13. Rosenberg, W. A.: Accidental tattooing of the face treated by abrasion with sandpaper. Arch Derm Syph. **65:** 466–470, 1952.
14. Strakosch, E. A.: Sandpaper—abrasion treatment of tattoos. Arch. Derm. Syph. **67:** 53–55, 1953.
15. Loria, P. R.: Dermabrasion: principles of planing. J. Louisiana Med. Soc. **112:** 401–405, 1960.
16. Boo-Chai, K.: The decorative tattoo: its removal by dermabrasion. Plast. Reconstr. Surg. **32:** 559–563, 1963.
17. Clabaugh, W.: Removal of tattoos by superficial dermabrasion. Arch. Dermatol. **98:** 515–521, 1968.