

## THE CLINICAL PICTURE

### YUE SHEN, MD, MS

Department of Internal Medicine,  
Bridgeport Hospital, Yale University,  
Bridgeport, CT

### PHILIP ONG, MD

Department of Internal Medicine,  
Bridgeport Hospital, Yale University,  
Bridgeport, CT

### NIEL GANDHI, BS

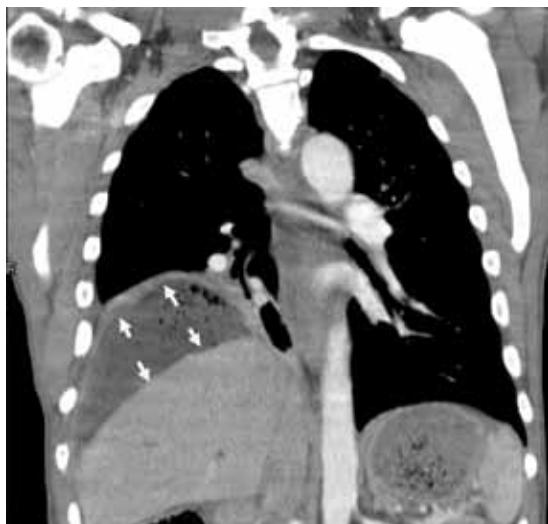
Department of Internal Medicine,  
Bridgeport Hospital, Yale University,  
Bridgeport, CT

### ANGELA DEGIROLAMO, MD

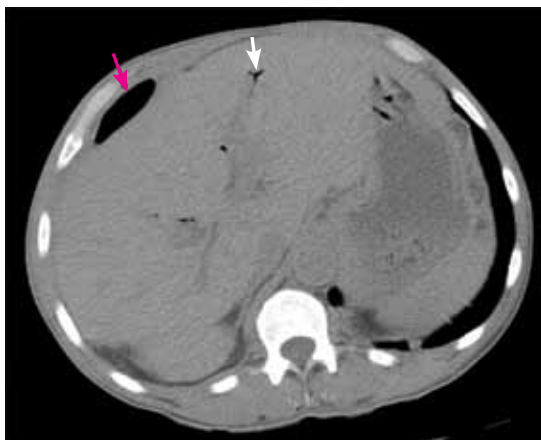
Department of Internal Medicine,  
Bridgeport Hospital, Yale University,  
Bridgeport, CT

# The Clinical Picture

## Subphrenic abscess from a perforated duodenal ulcer



**FIGURE 1.** Abdominal computed tomography (coronal view) shows a subphrenic abscess (arrows).



**FIGURE 2.** Pneumobilia (white arrow) and pneumoperitoneum (red arrow) are evident on this abdominal computed tomographic image (axial view).

**The methadone  
may have  
helped mask  
his abdominal  
symptoms**

**A** 55-YEAR-OLD MAN presented after 3 weeks of sharp epigastric pain radiating to the right upper quadrant, fever, and generalized weakness. He had a history of significant heroin and cocaine abuse and was currently in a methadone maintenance program. He was not taking any nonsteroidal anti-inflammatory drugs.

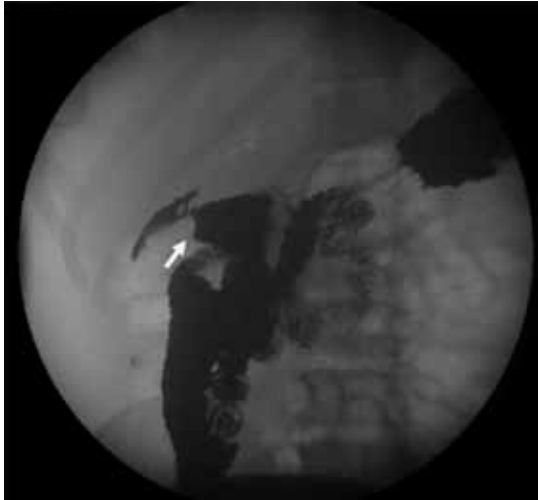His temperature was 38.7°C (101.7°F). He had tenderness in the right upper quadrant but no rebound tenderness.

Laboratory studies revealed an elevated white blood cell count of  $14.9 \times 10^9/L$  (reference range 4.5–11.0) with 13% band cells, a normal lipase level, and normal liver function

tests. Urine toxicology testing was positive for cocaine.

Computed tomography (CT) (FIGURE 1 AND FIGURE 2) showed a right subphrenic air-fluid collection (17 cm by 7 cm) and branching air lucencies within the liver and gallbladder fossa, signs of pneumobilia and pneumoperitoneum. The subphrenic fluid collection was drained percutaneously under fluoroscopic guidance, yielding 25 mL of purulent material. Culture of this material showed mixed flora. The percutaneous drainage catheter was left in place.

To investigate the cause of the abscess, we obtained an upper gastrointestinal radiographic series with oral contrast. This showed leaking of contrast from a perforated ulcer in the



**FIGURE 3.** Upper gastroduodenography with oral contrast shows contrast leaking through the perforated duodenal ulcer (arrow).

proximal duodenum (FIGURE 3).

We treated him with cefepime (Maxipime), metronidazole (Flagyl), fluconazole (Diflucan), a proton pump inhibitor, and octreotide (Sandostatin) intravenously. His condition stabilized, and 2 weeks later repeat CT showed no leakage, and the abscess had resolved. He was gradually returned to a normal diet and was discharged home with oral antibiotics.

■ **TREATING PERFORATED ULCER AND ITS COMPLICATIONS**

Perforated ulcers usually present with an acute abdomen and are life-threatening unless immediately recognized and treated. A more insidious presentation, as reported by Wong et al<sup>1</sup> and as seen in our patient, presents additional diagnostic challenges. Our patient's presentation may have been insidious and relatively benign because the perforation was not a free perforation (ie, the bowel contents were

■ **REFERENCES**

1. Wong CH, Chow PK, Ong HS, Chan WH, Khin LW, Soo KC. Posterior perforation of peptic ulcers: presentation and outcome of an uncommon surgical emergency. *Surgery* 2004; 135:321–325.
2. Berne TV, Donovan AJ. Nonoperative treatment of perforated duodenal ulcer. *Arch Surg* 1989; 124:830–832.
3. Flancabaum L, Noshier JL, Brolin RE. Percutaneous catheter

not freely spilling into the abdominal cavity), and because the spillage and inflammation were confined to an abscess cavity. Also, he was taking methadone 60 mg per day, which may have further masked the symptoms.

Perforated duodenal ulcers are usually treated surgically. Nonoperative management—ie, fluid resuscitation, nasogastric tube aspiration, and intravenous antibiotics—has been described,<sup>2</sup> but the hemodynamic status and abdominal findings need to be continually monitored to detect any deterioration in the patient's condition.

Initial management of the abscess with early percutaneous drainage and empiric intravenous antibiotics to cover enteric flora and anaerobes may suffice if there is no fistula.<sup>3</sup> Also, in a series of 62 patients with subphrenic abscess managed by percutaneous drainage, Mueller et al<sup>4</sup> found that this method was successful in most of the patients, noting that small-bowel perforation required the longest drainage period, generally more than 10 days.<sup>4</sup>

*Helicobacter pylori* infection and nonsteroidal anti-inflammatory drugs are responsible for the vast majority of duodenal ulcers. Serum *H pylori* antibody testing should be done, and if it is positive, treatment should be started. This patient did not have *H pylori* infection as an inpatient. He received metronidazole to cover the anaerobes and a proton pump inhibitor to treat the ulcer.

Although upper endoscopy was contraindicated in our patient because of his perforation, it was warranted for follow-up. Medical management with a proton pump inhibitor in high doses helped ulcer healing by reducing acid and gastric secretions. Octreotide had similar benefits, including reducing pancreatic and biliary secretion. This conservative management resulted in healing of the ulcer and early closure of the enteric fistula. ■

- drainage of abdominal abscesses associated with perforated viscus. *Am Surg* 1990; 56:52–56.
4. Mueller PR, Simeone JF, Butch RJ, et al. Percutaneous drainage of subphrenic abscess: a review of 62 patients. *AJR Am J Roentgenol* 1986; 147:1237–1240.

**ADDRESS:** Yue Shen, MD, MS, Internal Medicine, Bridgeport Hospital, 267 Grant Street, Bridgeport, CT 06610; e-mail judyshen@hotmail.com.

**Perforated ulcers usually present with an acute abdomen and are life-threatening**