CLEVELAND CLINIC QUARTERLY
Volume 37, July 1970
Copyright © 1970 by The Cleveland Clinic Foundation
Printed in U.S.A.

Intraneural lipoma of the median nerve

Report of two cases

THOMAS J. HAVERBUSH, M.D.*
JAMES I. KENDRICK, M.D.
CARL L. NELSON, M.D.
Department of Orthopaedic Surgery

INTRANEURAL lipoma of the median nerve occurs rarely and, when the nature of the lesion is not recognized, presents a problem of treatment. The intraneural lipoma is benign, affects an entire section of the nerve, and has a characteristic gross appearance. When this benign condition is recognized the appropriate treatment can be instituted. The description of intraneural lipoma or a discussion of the treatment is not included in most published series of nerve tumors, as there have been only 18 reported cases.[1-10] Our report is of two cases of intraneural lipoma, each with a characteristic gross appearance, and a discussion of the mode of treatment.

Report of cases

Case 1. A 22-year-old Caucasian man was examined because for six months he had been having numbness of the right hand. Seven months before examination, he noticed a mass in his right palm. The mass enlarged, and decreased sensation in the thumb, index, and middle fingers ensued five months before examination. He also noted that whenever pressure was placed on the palm, there was a burning, tingling sensation in the thumb, and in the index and the ring fingers. He had no history of other disease processes or masses elsewhere in the body.

Results of the general physical examination and laboratory tests were normal. The patient had full range of motion of the wrist and fingers. There was slight atrophy of the thenar eminence, and a palpable, firm, indurated, cystic mass, 2 cm in diameter, was present over the palm and thenar eminence. The mass could not be transilluminated and there were no bruits present. Pressure over the region caused pain in the palm and the fingers. There was decreased sensation to pinprick over the thumb, and the index, the middle and half of the ring fingers. There was fullness in the wrist and forearm, although a mass was not palpated. A roentgenogram of the wrist was normal.

A diagnosis of palmar lipoma was made. At surgery an S-shaped incision was made over the palmar aspect of the wrist and distal part of the forearm; the palmaris longus tendon was retracted and the median nerve exposed. It was large, elongated, lobular, and fatty in appearance (*Fig. 1*). A bulbous swelling was present proximal to the transverse carpal ligament, and the nerve filled the carpal tunnel. The transverse carpal ligament was sectioned and the elongated lobular mass welled-up from the carpal tunnel. The dissection was carried distally into the palm, and the nerves to the digits were exposed. The nerves were enlarged to the distal portion of the proximal flexion crease and then regained their normal size. A longitudinal excision biopsy was performed in the ulnar portion of the median nerve, and a strip of tissue, 5 mm by 2 cm, was excised. The wound was closed and a plaster splint applied, with the wrist in midposition. The biopsy specimen was

* *Fellow, Department of Orthopaedic Surgery.*

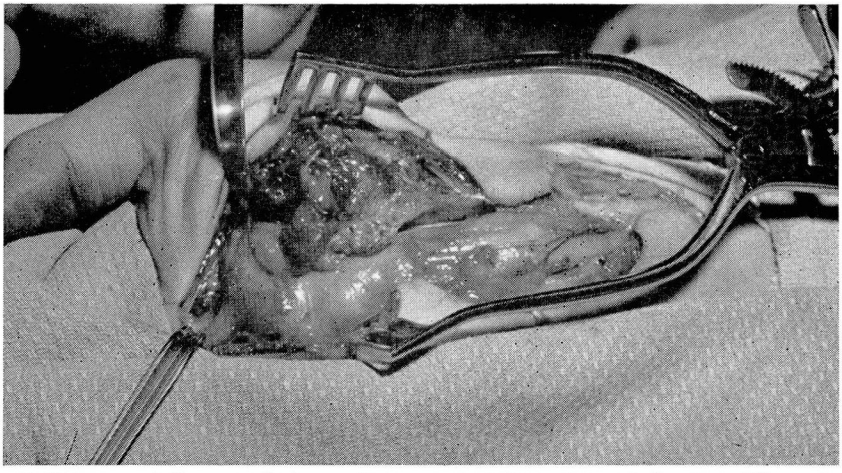

Fig. 1. Intraneural lipoma of the median nerve, right palm and forearm. The palmar aponeurosis and transverse carpal ligament have been divided. The thumb is at upper left.

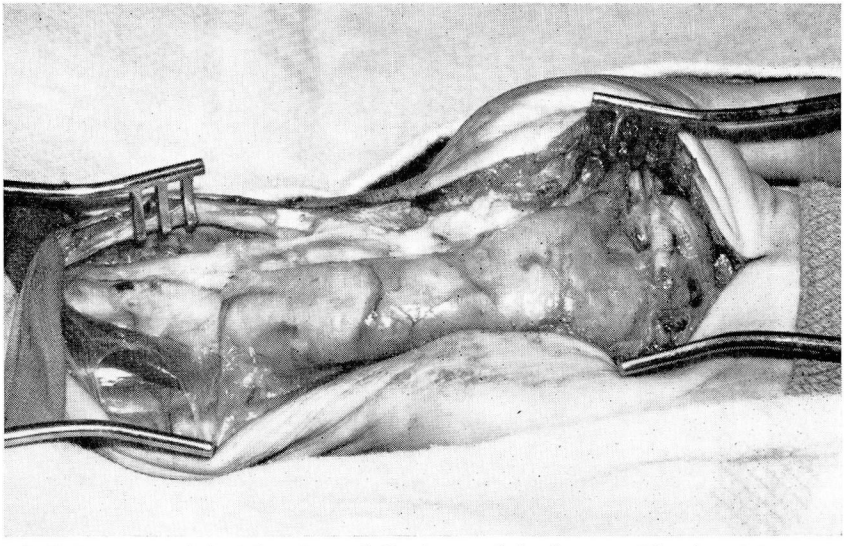

Fig. 2. Volar aspect of the left palm and distal part of the forearm. The thumb is at upper right. The enlarged median nerve is filling the palm and the forearm. Note enlarged digital branches at the distal aspect of the incision.

reported as fatty tissue. Two years postoperatively, the patient's sensation was normal. He had fullness in the palm and stated that when pressure was placed on the palm, he experienced paresthesia in the right middle and index fingers. The burning, tingling sensation in his hand had not recurred.

Case 2. A 27-year-old Causasian man was examined at the Cleveland Clinic in September 1969, because of swelling of the left palm, associated with intermittent dull pain for the last two months. His parents had noted the palmar mass in infancy. Until April 1969 the mass had been completely asymptomatic. Lifting objects with the left hand became un-

comfortable, and tools held in the hand felt cumbersome. There was no paresthesia, numbness, or decrease in sensation or strength in the hand.

Results of the physical examination were normal with the exception of the left hand. A soft nontender mass extended from the distal palmar crease to the wrist between the thenar and hypothenar regions. Barely perceptible swelling was present at the volar aspect of the wrist. Sensation and motor function in the hand were normal. Extension at the wrist was normal, but there was a slight limitation of flexion. Laboratory tests were normal. Roentgenograms showed a soft-tissue density in the palmar and thenar regions but otherwise were normal. The preoperative diagnosis was solitary palmar lipoma.

Surgical exploration of the left palm was performed. When the deep palmar fascia was incised, a lipomatous mass was seen. Further dissection revealed the mass to be a diffuse enlargement of the median nerve from the midforearm to the divisions into the common digital nerves (*Fig. 2*). The motor branch was also involved. The transverse diameter of the nerve was 3 cm in the palm. The lipoma was not encapsulated, but affected the nerve diffusely. Removal of the tumor was not possible without resection of the median nerve. Two small biopsy specimens were taken from the ulnar side of the mass in the palm. The carpal canal was decompressed by section of the transverse carpal ligament. The subcutaneous tissue and skin were closed and a bulky dressing was applied. The biopsy specimens were reported as fatty tissue; nerve elements were not seen. Postoperatively, the size of the mass was not appreciably changed; sensation and motor function were normal.

Discussion

The etiology of the intraneural lipoma of the median nerve is not known. Jenkins[11] believes that it may not be a true neoplasm, but rather a hamartoma with the tissues in improper proportion or distribution with an excess of fat tissue.[3, 12] Peripheral nerve tumors may arise from the neuraxon, sheath structures, specialized end organs, and connective tissue of the endoneurium, epineurium, or perineurium. Fat cells are found in the connective tissue of the epineurium.[13]

Trauma does not seem to be a relevant factor. Neither of the patients we treated had a history of significant injury to the hand. The rare occurrence and nature of the lesion would seem to be reason enough to dismiss consideration of everyday trauma to the palm as a causal agent.

The tumor reported in case 2 is of long duration. According to the patient's parents, it was present since infancy, and had enlarged, relatively, as the hand grew. In the majority of the reported cases, the tumors have been noticed initially in childhood, and, in two cases, a lesion was noted at birth.[7-10] Morley[6] reported the oldest age at onset of the tumor; the patient was 33 years old.

In our case 2, the lesion presented no signs or symptoms of median nerve compression because the tumor had been present since the patient's birth. Apparently the median nerve in the carpal tunnel had been able to accommodate this large mass without difficulty; whereas in our case 1, the relatively rapid enlargement of a previously undetected abnormality caused excess pressure in the carpal canal. There is no correlation between the age at onset and the development of motor or sensory symptoms.

Median nerve compression in the carpal tunnel is not uncommon, and usually is associated with inflammatory changes in the surrounding synovium. A variety of traumatic, metabolic, and inflammatory processes have

been shown to cause median nerve compression. An unusual condition causing median nerve compression in the carpal tunnel is an intraneural lipoma.

Friedlander, Rosenberg and Graubard[3] reviewed the published reports and found that of 12 cases of intraneural lipoma of the median nerve, in only four cases were there signs of nerve compression. In only one case of the two cases we report did the patient have signs and symptoms of median nerve compression.

Treatment

When the lesion is identified as an intraneural mass, it is necessary to biopsy the nerve to establish the diagnosis. The ulnar portion of the nerve contains the sensory fibers and is the suggested site of biopsy.

Sectioning of the transverse carpal ligament is indicated in cases with or without median nerve compression, as sectioning alleviates or prevents median nerve compression.

Summary and conclusions

Intraneural lipoma of the median nerve is a benign, unusual condition that can produce compression of the median nerve in the carpal tunnel. Two cases are reported. Removal of the lesion is contraindicated because of the resulting neurologic deficit, and the benign nature of the condition. Section of the transverse carpal ligament should be performed to alleviate or to prevent median nerve compression.

References

1. Callison, J. R.; Thomas, O. J., and White, W. L.: Fibro-fatty proliferation of the median nerve. Plast. Reconstr. Surg. **42:** 403–413, 1968.
2. Emmett, A. J.: Lipomatous hamartoma of the median nerve in the palm. Brit. J. Plast. Surg. **18:** 208–213, 1965.
3. Friedlander, H. L.; Rosenberg, N. J., and Graubard, D. J.: Intraneural lipoma of the median nerve; report of two cases and review of the literature. J. Bone Joint Surg. **51-A:** 352–362, 1969.
4. Johnson, R. J., and Bonfiglio, M.: Lipofibromatous hamartoma of the median nerve. J. Bone Joint Surg. **51-B:** 984–990, 1969.
5. Mikhail, I. K.: Median nerve lipoma in the hand. J. Bone Joint Surg. **46-B:** 726–730, 1964.
6. Morley, G. H.: Intraneural lipoma of the median nerve in the carpal tunnel; report of a case. J. Bone Joint Surg. **46:B:** 734–735, 1964.
7. Pulvertaft, R. G.: Unusual tumours of the median nerve; report of two cases. J. Bone Joint Surg. **46-B:** 731–733, 1964.
8. Rowland, S. A.: Lipofibroma of the median nerve in the palm. J. Bone Joint Surg. **49-A:** 1309–1313, 1967.
9. Watson-Jones, R.: Encapsuated lipoma of the median nerve at the wrist. J. Bone Joint Surg. **46-B:** 736, 1964.

10. Yeoman, P. M.: Fatty infiltration of the median nerve. J. Bone Joint Surg. **46-B:** 737–739, 1964.

11. Jenkins, S. A.: Solitary tumours of peripheral nerve trunks. J. Bone Joint Surg. **34-B:** 401–411, 1952.

12. Boyes, J. H.: Bunnell's Surgery of the Hand, **4th** ed. Philadelphia: J. B. Lippincott Co., 1964, 791 p.; p. 769.

13. Bloom, W., and Fawcett, D. W.: A Textbook of Histology, **8th** ed. Philadelphia: W. B. Saunders Co., 1962, p. 230.