



EDUCATIONAL OBJECTIVE: Readers will encourage their menopausal patients to practice good oral hygiene and to see their dentists regularly

MARIA CLARINDA A. BUENCAMINO, MD
Women's Health Institute, Cleveland Clinic

LEENA PALOMO, DDS, MSD^a
Assistant Professor of Periodontology, Director of Predoctoral Periodontics, Case Western Reserve University School of Dental Medicine, Cleveland, OH

HOLLY L. THACKER, MD, CDD^b
Director, Center for Specialized Women's Health, Women's Health Institute, Cleveland Clinic; Associate Professor, Cleveland Clinic Lerner College of Medicine of Case Western Reserve University, Cleveland, OH

How menopause affects oral health, and what we can do about it

ABSTRACT

After menopause, women become more susceptible to periodontal disease. We believe the problem is due in large part to estrogen deficiency with resulting bone loss and inflammatory processes. Osteoporosis and periodontal disease are best diagnosed early so that treatment can be started sooner and fractures and tooth loss can be prevented.

KEY POINTS

Physicians should be vigilant for dental problems and should encourage their patients to practice good oral hygiene and to seek regular dental care.

Available information suggests that hormone therapy and bisphosphonate drugs may be developed to protect against alveolar bone loss and perhaps slow the progression of periodontal disease.

Bisphosphonate-associated osteonecrosis of the jaw is rare, and most of the reported cases have been in cancer patients who received high doses of bisphosphonates intravenously and who had other risk factors for it.

MENOPAUSE CAN BRING oral health problems that physicians ought to keep in mind. The same processes that lead to loss of bone in the spine and hips can also lead to loss of the alveolar bone of the jaws, resulting in periodontal disease, loose teeth, and tooth loss. Although the mouth is traditionally the dentist's responsibility, patients may need encouragement from their physicians to practice good oral hygiene and to see their dentists, and should be referred to a periodontist at the first sign of periodontal disease.

Moreover, bisphosphonates, the class of drugs most often prescribed for osteoporosis, have been linked by case reports (unfairly, we believe) to osteonecrosis of the jaw. This low-evidence-level information, its far-reaching interpretation, and misinformation in the lay media about hormonal changes associated with menopause have led to confusion among women; for clarification and reliable information, they are driven to ask their physicians challenging questions related to oral health.

This article reviews the published studies of the association between menopause and periodontal disease, specifically, the effects of hormonal changes, osteoporosis, and bisphosphonate use on the periodontal status of postmenopausal women. We will highlight the interrelationship of dental health and postmenopausal health and underscore the need for cross-communication and patient referral between physicians and dentists.

GINGIVITIS CAN PROGRESS TO PERIODONTITIS

Gingivitis is a reversible inflammatory response to bacterial plaque buildup that is limited to the gingiva (FIGURE 1).

^aDr. Palomo has disclosed that she has received honoraria for speaking and teaching from Procter and Gamble.

^bDr. Thacker has disclosed that she has received honoraria for speaking and teaching from Bayer, Novartis, Procter and Gamble, Sanofi-Aventis, Ther-Rx, Upsher-Smith Laboratories, and Wyeth companies, and the Alliance for Better Bone Health.

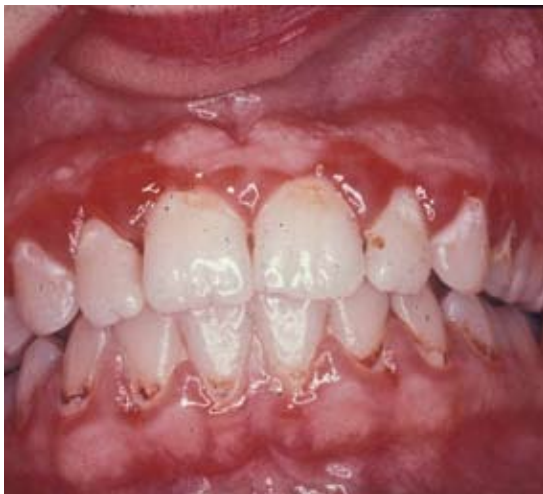

FIGURE 1. Red swollen gums of gingivitis.

If unchecked, gingivitis progresses to periodontitis, an inflammation of the supporting tissues of the teeth, including the gingiva, alveolar bone, and periodontal ligament (FIGURE 2). Periodontitis leads to progressive and irreversible loss of bone and periodontal ligament attachment, as inflammation extends from the gingiva into adjacent bone and ligament. Signs and symptoms of progressing periodontitis include red, swollen gums that may appear to have pulled away from the teeth, persistent bad breath, pus between the teeth and gums (FIGURE 3), loose or separating teeth, and the common complaint that “my teeth don’t fit together anymore.”

A common complaint in periodontitis: ‘My teeth don’t fit together anymore’

■ **AS ESTROGEN DECLINES, SO DO THE BONES AND, MAYBE, THE TEETH**

In menopause, estrogen levels decline rapidly, which can lead to systemic bone loss.¹

The rate of bone loss in postmenopausal women predicts tooth loss—for every 1%-per-year decrease in whole-body bone mineral density, the risk of tooth loss increases more than four times.² In fact, Kribbs³ found that women with severe osteoporosis were three times more likely than healthy, age-matched controls to be edentulous (ie, to have fewer teeth).

Although a number of studies have found that the density of the alveolar bone in the mandible correlated with the density of the bone in the rest of the skeleton and that generalized bone loss may render the jaw susceptible to accelerated alveolar bone resorption,³⁻¹¹

these findings are not universal. In a longitudinal study, Famili et al¹² found no association between systemic bone loss, periodontal disease, and edentulism. This shows that the relationship between alveolar bone loss and systemic bone loss is multifactorial and not yet fully understood.¹³

Nevertheless, the American Academy of Periodontology considers osteoporosis to be a risk factor for periodontal disease.¹⁰ In fact, alveolar bone loss has been related not only to osteoporosis but also to osteopenia.¹⁴

Bone mineral density has also been studied in relation to the loss of periodontal ligament—the collagenous attachment of tooth to bone. Klemetti et al¹⁵ found that healthy postmenopausal women with high bone mineral density seemed to retain teeth more readily than those with low bone density or those with osteoporosis, even if they had deep periodontal pockets (a sign of periodontal disease). These findings were reiterated when osteoporotic women were found to have significantly greater loss of attachment compared with nonosteoporotic women.⁷

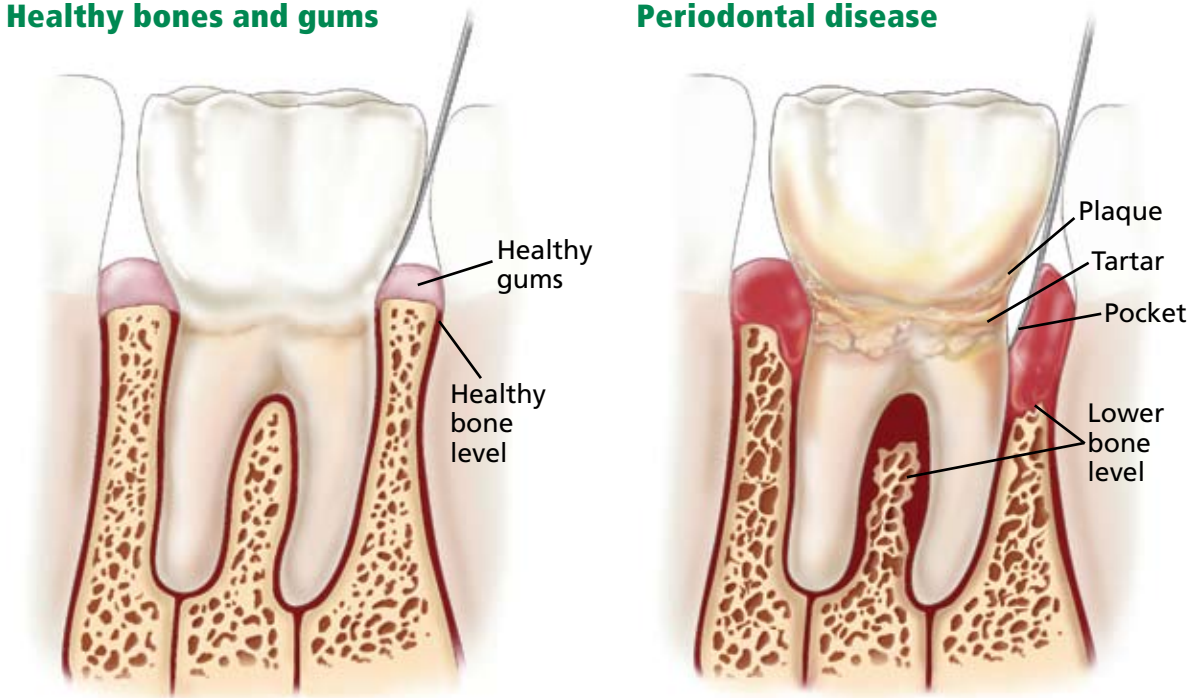However, Hildebolt¹⁶ reported that loss of tooth attachment correlated with tooth loss but not with the density of the vertebrae or the proximal femur. This study called into question the findings of the previous studies and provoked debate.

Tezal et al¹⁷ found that low bone mineral density was related to the loss of interproximal alveolar bone (the alveolar bone between adjacent teeth) and, to a lesser extent, ligamentous attachment loss. These data implicated osteoporosis as a possible risk indicator for periodontal disease in white women. (This study was limited to white women because of different demographics in the incidence of osteoporosis.)

Another study showed only a weak correlation between changes in alveolar bone height (in periodontal disease, bone height decreases) and attachment levels. Although a correlation might be present, the relationship was complex and required further examination. The authors found no clear association between clinical attachment levels and bone mineral density in the lumbar spine, but they recognized that attachment loss often precedes the loss of alveolar bone by a significant time period.¹³

Healthy bones and gums

Periodontal disease



CCF
Medical Illustrator: Beth Halasz ©2009

FIGURE 2. Healthy gums and bones (left) vs periodontal disease (right). Note the lower bone height and resulting deeper pockets in periodontal disease.

Several studies have found a possible relationship between the bone density in the jaw and the density in the rest of the skeleton. It appears that loss of bone mineral density in the hip, wrist, and lumbar areas is correlated with low density in the mandible. Taguchi et al¹⁸ reported that the density in the lumbar spine correlated with the density of the mandibular cortex in early menopause, and with the density of both the cortex and cancellous bone in later menopause.

But whatever the statistical measurement, the susceptibility to progressive periodontitis increases after menopause, and the primary cause is bacterial plaque. The best hedge against this increased susceptibility is regular dental care to remove bacterial plaque biofilm under the gum-line.

■ HORMONE THERAPY PRESERVES BONE IN THE JAW

Hormones have long been recognized as having some role in periodontal disease.

Payne et al¹⁹ reported that postmenopausal women who were estrogen-deficient had a higher frequency of sites with a net loss of

alveolar bone density at follow-up. Furthermore, estrogen-deficient women undergoing supportive periodontal therapy following treatment of moderate to severe periodontitis had three times as many sites losing more than 0.4 mm of interproximal alveolar bone height. Patients who had sufficient estrogen levels did not lose bone during 1 year of follow-up.²⁰

Estrogen replacement improves bone density in postmenopausal women. In a 3-year randomized trial in postmenopausal women with moderate or advanced periodontal disease, estrogen therapy significantly increased alveolar bone mass compared with placebo ($P = .04$), and it increased bone density in the femur but not the lumbar spine.²¹ Furthermore, women receiving hormonal therapy had significantly less gingival inflammation, lower plaque scores, and less loss of attachment.

On the other hand, a report by Albandar and Kingman²² suggested that women who comply with hormonal therapy also comply with oral hygiene instructions. This compliance could explain the lower gingival inflammation scores, lower plaque scores, and lesser loss of attachment.

The American Academy of Periodontology considers osteoporosis to be a risk factor for periodontal disease

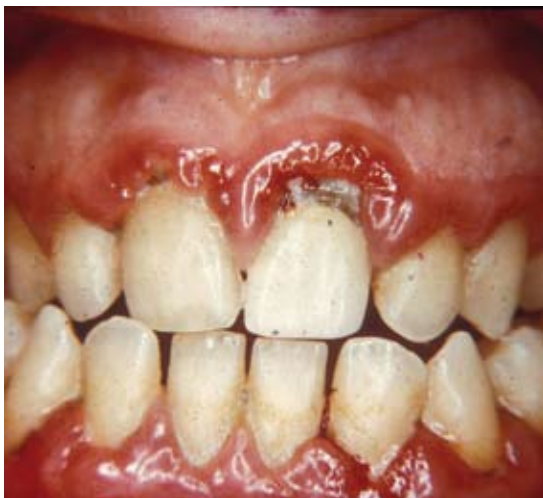

FIGURE 3. Red swollen gums with pus in periodontitis.

Norderyd et al,²³ in a cross-sectional study, found less periodontal disease in postmenopausal women who were on estrogen therapy than in those who were not, although the difference was not statistically significant.

In a 5-year longitudinal study of 69 postmenopausal women receiving estrogen, a moderate but significant relationship was found between bone mineral density of the lumbar spine and the mandible, and estrogen replacement therapy had a positive effect on the mandibular bone mass.²⁴

In a longitudinal study of 24 postmenopausal women, estrogen-deficient women had a mean net loss of alveolar bone density over time, while estrogen-sufficient women had a mean net gain, suggesting that estrogen deficiency may be a risk factor for alveolar bone loss.²⁰ More-recent studies had similar findings. A cross-sectional study by Meisel et al²⁵ found that hormone therapy significantly reduced the extent of clinical attachment loss and, hence, periodontal disease.

The findings of these studies are generally consistent, suggesting that estrogen builds up mandibular bone mass and attenuates the severity of periodontal disease in postmenopausal women.²⁶

■ DOES ESTROGEN THERAPY PROTECT THE TEETH?

Studies of the Leisure World,²⁷ Framingham,²⁸ and Nurses Health Study²⁹ cohorts suggest

that hormone therapy protects against tooth loss in postmenopausal women.

On the other hand, Taguchi et al³⁰ evaluated more than 300 postmenopausal Japanese women and found no significant difference in the total number of teeth between estrogen users and nonusers. The population in this study was younger than in the other studies mentioned above,²⁷⁻²⁹ which may explain the negative finding. However, the duration of estrogen use was significantly associated with the total number of teeth remaining, independent of age.³⁰ Meisel et al²⁵ reported that women receiving hormonal therapy had more teeth, though the difference was not significant.

■ CYTOKINES, PERIODONTITIS, AND SKELETAL BONE LOSS

Studies suggest that low estrogen production after menopause is associated with increased production of interleukin 1 (IL-1), IL-6, IL-8, IL-10, tumor necrosis factor alpha, granulocyte colony-stimulating factor, and granulocyte-macrophage colony-stimulating factor, which stimulate mature osteoclasts, modulate bone cell proliferation, and induce resorption of both skeletal and alveolar bone.³¹⁻³⁴

Genco and Grossi²⁶ have proposed a model for estrogen deficiency as a risk factor for periodontal disease (FIGURE 4). In this model, estrogen deficiency leads to more production of bone-resorbing cytokines produced by immune cells (monocytes and macrophages) and osteoblasts. When challenged by products related to periodontal bacterial plaque biofilm, by bone-resorbing factors such as lipopolysaccharides, and by toxins, the host immune system produces more inflammatory cytokines that activate osteoclasts, which reabsorb bone. The buildup of bacterial plaque biofilm made up of periopathogenic bacteria³⁵ seems to be necessary for an estrogen-deficient woman to actually show changes such as loss of tooth attachment and alveolar bone. The host's inflammatory response to this biofilm starts the inflammation cascade and may lead to constant activation of tissue proteinases and degradative enzymes, leading to connective tissue destruction, alveolar bone resorption, and ultimately tooth loss, which can explain the increased risk

Osteoporosis and periodontitis seem to be mediated by common cytokines

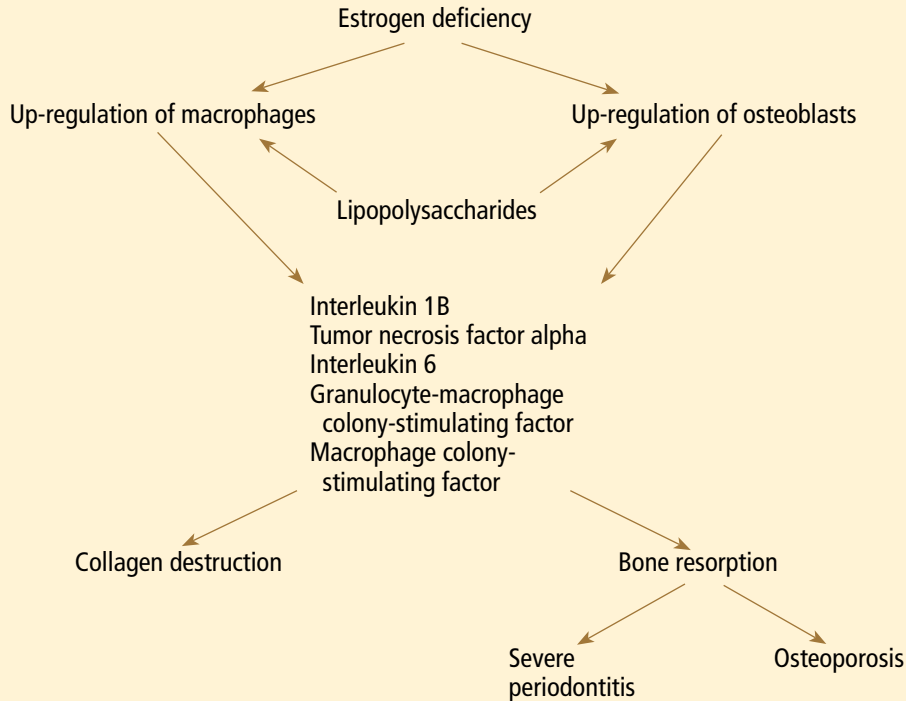


FIGURE 4. Proposed model for how estrogen deficiency contributes to severe periodontal disease.

BASED ON GENCO RJ, GROSSI SG. IS ESTROGEN DEFICIENCY A RISK FACTOR FOR PERIODONTAL DISEASE? COMPEND CONTIN EDUC DENT SUPPL 1998; 22:S23-S29.

No cause-and-effect relationship between osteonecrosis of the jaw and bisphosphonate use has been established

of periodontal disease in postmenopausal women.^{26,3}

In this regard, osteoporosis and periodontitis appear to be mediated by common cytokines. Managing osteoporosis, removing bacterial plaque biofilm with good oral hygiene, and regular dental visits are important in avoiding periodontitis in susceptible women.

■ BISPHOSPHONATES PROTECT BONE

In the skeleton

Bisphosphonates, the most commonly prescribed therapy for osteoporosis, inhibit systemic bone resorption and reduce the incidence of vertebral and nonvertebral fractures. Among the bisphosphonates, alendronate (Fosamax), risedronate (Actonel), and intravenous zoledronic acid (Reclast) have been shown to reduce the risk of both hip and vertebral fractures, whereas ibandronate (Boniva) has only been shown to

decrease the risk of vertebral fracture.³⁶ Specific findings:

- In the Fracture Intervention Trial,³⁷ alendronate reduced the risk of vertebral fracture by 47% and hip fracture by 51% in women with low bone mineral density and previous vertebral fractures.
- In the Hip Intervention Program,³⁸ risedronate decreased the risk of hip fracture by 40% in postmenopausal women 70 to 79 years old with osteoporosis, but not in those 80 years and older, who are at high risk of falls. Risedronate also reduced vertebral fracture risk by 49% after 3 years of treatment.³⁹
- In the Health Outcomes and Reduced Incidence With Zoledronic Acid Once Yearly Recurrent Fracture Trial,⁴⁰ annual infusion of zoledronic acid after a hip fracture reduced the rates of new clinical vertebral and nonvertebral fractures and death from all causes.

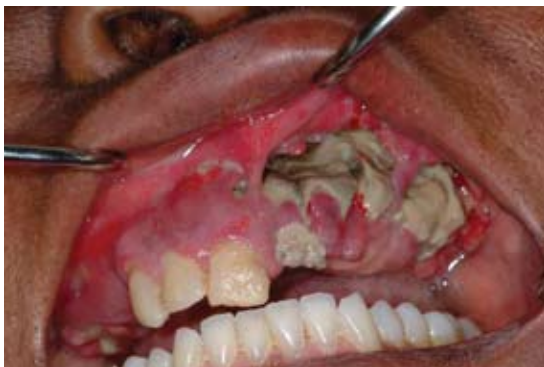

FIGURE 5. Osteonecrosis of the jaw.

REPRODUCED FROM RUGGIERO SL, MEHROTRA H, ROSENBERG TJ, ENGROFF SL. OSTEONECROSIS OF THE JAWS ASSOCIATED WITH THE USE OF BISPHOSPHONATES: A REVIEW OF 63 CASES. J ORAL MAXILLOFACIAL SURG 2004; 62:527-534, WITH PERMISSION FROM ELSEVIER. WWW.SCIENCEDIRECT.COM/SCIENCE/JOURNAL/02782391.

In the jaw

Not surprisingly, recent studies suggest that bisphosphonates slow the resorption of alveolar bone of the maxilla and mandible as well. Alendronate and risedronate, in particular, have been noted to improve periodontal status.⁴¹⁻⁴³ Findings:

- In a cross-sectional study by Palomo et al,⁴¹ postmenopausal women with low bone density using risedronate for at least 3 months showed significantly less plaque accumulation, less gingival inflammation, lower probing-depth measurements, less periodontal attachment loss, and greater alveolar bone levels.
- In a double-blind, controlled, prospective study by Rocha et al,⁴² 6 months of alendronate therapy significantly improved periodontal disease as assessed radiographically and clinically in 40 postmenopausal women with established periodontal disease.
- Jeffcoat et al⁴³ reported that 2 years of alendronate treatment significantly reduced alveolar bone loss relative to placebo in patients with low mandibular bone mineral density at baseline but not in those with normal baseline mandibular bone mineral density.

■ DO BISPHOSPHONATES CAUSE OSTEONECROSIS OF THE JAW?

Despite these benefits, there has been much concern about bisphosphonate-associated osteonecrosis of the jaw (FIGURE 5). Osteonecrosis

of the jaw is a rare disorder characterized by exposure and loss of bone in the maxillofacial complex that is resistant or refractory to conventional therapy (reviewed by Carey and Palomo⁴⁴). Most of the information on an association with bisphosphonates comes from case reports involving cancer patients who received high intravenous doses and who had other risk factors for jaw disease.⁴⁵⁻⁴⁸

The intravenous bisphosphonates most commonly used to treat hypercalcemia of malignancy, multiple myeloma, or metastatic bone disease are⁴⁷:

- Pamidronate (Aredia) 90 mg infused over 2 to 24 hours every 3 to 4 weeks
- Zoledronic acid (Zometa) 4 mg infused over 15 minutes monthly.

The doses of bisphosphonates indicated for the treatment of osteoporosis are much lower,¹ eg:

- Alendronate 70 mg by mouth once a week
- Risedronate 35 mg by mouth once a week or 150 mg once a month
- Ibandronate 150 mg by mouth once a month
- Ibandronate 3 mg intravenously every 3 months
- Zoledronic acid 5 mg intravenously once a year.

Moreover, less than 1% of an oral dose is absorbed by the gastrointestinal tract,⁴⁹ whereas more than 50% of the dose of bisphosphonates given intravenously is bioavailable,⁵⁰ which may account for the lower incidence of jaw osteonecrosis with oral agents.

Osteonecrosis of the jaw can occur spontaneously but is more often associated with dental procedures that traumatize bone, such as tooth extraction.⁵¹ In a systematic review,⁴⁵ patients with multiple myeloma and metastatic cancer to the bone who were receiving intravenous bisphosphonates accounted for 94% of published cases. Sixty percent of cases were preceded by dental surgical procedures, and in 39% of cases that occurred spontaneously the lesions were located on bony exostoses, a possible source of trauma. Of 63 cases reported by Ruggiero et al,⁴⁷ 56 patients were receiving intravenous bisphosphonates and 7 were receiving oral bisphosphonates. Older age (> 65 years), chronic systemic steroid use, periodontitis, and prolonged use of bispho-

Bisphosphonate doses are much lower for osteoporosis than for cancer

TABLE 1

Risk factors for bisphosphonate-associated osteonecrosis of the jaw

Drug-related risk factors

Potency of bisphosphonates: zoledronic acid (Zometa) > pamidronate (Aredia) > oral bisphosphonates

The intravenous route results in a greater drug exposure than the oral route

Duration of therapy: longer duration appears to be associated with increased risk

Local risk factors

Dentoalveolar surgery, including but not limited to:

- Tooth extraction
- Dental implant placement
- Periapical surgery
- Periodontal surgery
- Periodontal surgery involving osseous injury

Local anatomy

- Mandible: lingual tori, mylohyoid ridge
- Maxilla: palatal tori

Concomitant oral disease: inflammatory dental disease, ie, periodontal and dental abscesses

Demographic and systemic factors

Age: With each decade, the risk of bisphosphonate-associated osteonecrosis of the jaw increases 9% in patients with multiple myeloma treated with intravenous bisphosphonates

White race

Cancer diagnosis: risk is greater for multiple myeloma patients than for breast cancer patients; and those with breast cancer have a greater risk than those with other cancers

Osteopenia or osteoporosis diagnosis concurrent with cancer diagnosis

Others thought to be risk factors

- Corticosteroid therapy
- Diabetes
- Smoking
- Alcohol use
- Poor oral hygiene
- Chemotherapeutic drugs

ADAPTED FROM AMERICAN ASSOCIATION OF ORAL AND MAXILLOFACIAL SURGEONS POSITION PAPER ON BISPHOSPHONATE-RELATED OSTEONECROSIS OF THE JAWS. J ORAL MAXILLOFACIAL SURG 2007; 65:369-376, WITH PERMISSION FROM ELSEVIER. WWW.SCIENCEDIRECT.COM/SCIENCE/JOURNAL/02782391.

sphosphonates have also been associated with a higher risk of osteonecrosis of the jaw.⁵¹

The risk of developing osteonecrosis of the jaw in people taking bisphosphonates in doses recommended by the US Food and Drug Administration for treating osteoporosis is very low (the incidence is calculated at 0.7 per 100,000 person-years of exposure to alendronate).^{51,52} In a 3-year prospective study in more than 7,000 women with postmenopausal osteoporosis, the incidence of osteonecrosis of the jaw was no different in

those treated with zoledronic acid 5 mg intravenously than in those receiving placebo.⁵³ In a randomized, placebo-controlled study of the effect of 2 years of alendronate treatment on alveolar bone loss involving 335 patients with periodontal disease, no cases of osteonecrosis of the jaw were reported.⁴³

The American Dental Association (ADA) released a statement noting that osteonecrosis of the jaw can occur with or without bisphosphonate use.⁵¹ To date, a true cause-and-effect relationship between osteonecro-

sis of the jaw and bisphosphonate use has not been established. Further studies are needed to fully explore this relationship. Our group is currently exploring novel periodontal assessments comparing the oral health of postmenopausal women with osteoporosis who are on no bone therapy vs postmenopausal women with osteoporosis treated with bisphosphonates for 2 or more years.

While we await further studies exploring this relationship, clinicians in direct care of patients who are or will be taking bisphosphonates should carefully assess risk factors before starting treatment and during treatment. In 2007, the American Association of Oral and Maxillofacial Surgeons released a position paper on bisphosphonate-associated osteonecrosis of the jaw,⁵² listing potential risk factors (TABLE 1) for its development, as well as management strategies for patients treated with bisphosphonates. To prevent this possible complication, they recommended a thorough oral examination before treatment with an intravenous bisphosphonate, and that “any unsalvageable teeth should be removed, all invasive dental procedures should be completed, and optimal periodontal health should be achieved.”⁵² They also proposed that “discontinuation of oral bisphosphonate for a period of 3 months prior to and 3 months after elective invasive dental surgery may lower the risk.”⁵² This should, however, be done in consultation with the treating physician and the patient.

Discussion of treatment for bisphosphonate-associated osteonecrosis of the jaw is beyond the scope of this article.

REGULAR DENTAL CARE IS ESSENTIAL

Regardless of whether the patient is receiving a bisphosphonate drug, physicians caring for postmenopausal women should be vigilant and encourage their patients to seek regular dental evaluation for prevention and early management of oral disorders. Conversely, dentists should be aware of the potential effects of menopause and its treatments on bone and dental health.

Questions from postmenopausal women can be managed, in part, by returning to the basics suggested by the ADA:

- Regular dental examinations; regular professional cleaning to remove bacterial plaque biofilm under the gum-line where a toothbrush will not reach
- Daily oral hygiene practices to remove biofilm at and above the gum-line including brushing twice daily with an ADA-accepted toothpaste
- Replacing the toothbrush every 3 to 4 months (or sooner if the bristles begin to look frayed)
- Cleaning interproximally (between teeth) with floss or interdental cleaner
- Maintaining a balanced diet
- No smoking.

REFERENCES

1. **North American Menopause Society.** Menopause Practice: A Clinician's Guide. 3rd ed; 2007.
2. **Krall EA, Garcia RI, Dawson-Hughes B.** Increased risk of tooth loss is related to bone loss at the whole body, hip and spine. *Calcif Tissue Int* 1996; 59:433-437.
3. **Kribbs PJ.** Comparison of mandibular bone in normal and osteoporotic women. *J Prosthet Dent* 1990; 63:218-222.
4. **Kribbs PJ, Chesnut CH 3rd, Ott SM, Kilcoyne RF.** Relationship between mandibular and skeletal bone in an osteoporotic population. *J Prosthet Dent* 1989; 62:703-707.
5. **Kribbs PJ, Chestnut CH 3rd, Ott SM, Kilcoyne RE.** Relationship between mandibular and skeletal bone in a population of normal women. *J Prosthet Dent* 1990; 63:86-89.
6. **Kribbs PJ, Smith DE, Chestnut CH 3rd.** Oral findings in osteoporosis. Part II: relationship between residual ridge and alveolar bone resorption and generalized skeletal osteopenia. *J Prosthet Dent* 1983; 50:719-724.
7. **von Wowern N, Klausen B, Kollerup G.** Osteoporosis: a risk factor in periodontal disease. *J Periodontol* 1994; 65:1134-1138.
8. **Wactawski-Wende J, Grossi SG, Trevisan M, et al.** The role of osteopenia in oral bone loss and periodontal disease. *J Periodontol* 1996; 67(suppl 10):1076-1084.
9. **Ronderos M, Jacobs DR, Himes JH, Pihlstrom BL.** Associations of periodontal disease with femoral bone mineral density and estrogen replacement therapy: cross-sectional evaluation of US adults from the NHANES III. *J Clin Periodontol* 2000; 27:778-86.
10. **American Dental Association Council on Access, Prevention and Interprofessional Relations.** Women's Oral Health Issues. November 2006.
11. **Jeffcoat MK, Lewis CE, Reddy MS, Wang CY, Redford M.** Post-menopausal bone loss and its relationship to oral bone loss. *Periodontol* 2000 2000; 23:94-102.
12. **Famili P, Cauley J, Suzuki JB, Weyant R.** Longitudinal study of periodontal disease and edentulism with rates of bone loss in older women. *J Periodontol* 2005; 76:11-15.
13. **Pilgram TK, Hildebolt CF, Yokoyama N, et al.** Relationships between longitudinal changes in radiographic alveolar bone height and probing depth measurements: data from postmenopausal women. *J Periodontol* 1999; 70:829-833.
14. **Jeffcoat MK, Lewis CE, Reddy MS, et al.** Oral bone loss and systemic osteopenia, osteoporosis. In Marcus R, Feldman D, Kelsey J, editors. *Osteoporosis*. New York Academic Press 1996:969-990.
15. **Klemetti E, Collin HL, Forss H, Markkanen H, Lassila V.** Mineral status of skeletal and advanced periodontal disease. *J Clin Periodontol* 1994; 21:184-188.
16. **Hildebolt CF.** Osteoporosis and oral bone loss. *Dentomaxillofac*

- Radiol 1997; 26:3–15.
17. **Tezal M, Wactawski-Wende J, Grossi SG, Ho AW, Dunford R, Genco RJ.** The relationship between bone mineral density and periodontitis in postmenopausal women. *J Periodontol* 2000; 71:1492–1498.
 18. **Taguchi A, Tanimoto K, Suei Y, Ohama K, Wada T.** Relationship between the mandibular and lumbar vertebral bone mineral density at different postmenopausal stages. *Dentomaxillofac Radiol* 1996; 25:130–135.
 19. **Payne JB, Reinhardt RA, Nummikoski PV, Patil KD.** Longitudinal alveolar bone loss in postmenopausal osteoporotic/osteopenic women. *Osteoporos Int* 1999; 10:34–40.
 20. **Payne JB, Zachs NR, Reinhardt RA, Nummikoski PV, Patil K.** The association between estrogen status and alveolar bone density changes in postmenopausal women with a history of periodontitis. *J Periodontol* 1997; 68:24–31.
 21. **Civitelli R, Pilgram TK, Dotson M, et al.** Alveolar and postcranial bone density in postmenopausal women receiving hormone/estrogen replacement: a randomized, double blind, placebo-controlled trial. *Arch Intern Med* 2002; 162:1409–1415.
 22. **Albandar JM, Kingman A.** Gingival recession, gingival bleeding, and dental calculus in adults 30 years of age and older in the United States, 1988–1994. *J Periodontol* 1999; 70:30–43.
 23. **Norderyd OM, Grossi SG, Machtel EE, et al.** Periodontal status of women taking postmenopausal estrogen supplementation. *J Periodontol* 1993; 64:957–962.
 24. **Jacobs R, Ghyselen J, Koninckx P, van Steenberghe D.** Long-term bone mass evaluation of mandible and lumbar spine in a group of women receiving hormone replacement therapy. *Eur J Oral Sci* 1996; 104:10–16.
 25. **Meisel P, Reifenberger J, Haase R, Nauck M, Bandt C, Kocher T.** Women are periodontally healthier than men, but why don't they have more teeth than men? *Menopause* 2008; 15:270–275.
 26. **Genco RJ, Grossi SG.** Is estrogen deficiency a risk factor for periodontal disease? *Compend Contin Educ Dent Suppl* 1998; 22:S23–S29.
 27. **Paganini-Hill A.** The benefits of estrogen replacement therapy on oral health. The Leisure World cohort. *Arch Intern Med* 1995; 155:2325–2329.
 28. **Krall EA, Dawson-Hughes B, Hannan MT, Wilson PW, Kiel DP.** Postmenopausal estrogen replacement and tooth retention. *Am J Med* 1997; 102:536–542.
 29. **Grodstein F, Colditz GA, Stampfer MJ.** Postmenopausal hormone use and tooth loss: a prospective study. *J Am Dent Assoc* 1996; 127:370–377.
 30. **Taguchi A, Sanada M, Suei Y, et al.** Effect of estrogen use on tooth retention, oral bone height, and oral bone porosity in Japanese postmenopausal women. *Menopause* 2004; 11:556–562.
 31. **Pacifici R.** Estrogen, cytokines and pathogenesis of postmenopausal osteoporosis. *J Bone Miner Res* 1996; 11:1043–1051.
 32. **Pacifici R.** Is there a causal role for IL-1 in postmenopausal bone loss? *Calcif Tissue Int* 1992; 50:295–299.
 33. **Girasole G, Jilka RL, Passeri G, et al.** 17 beta-estradiol inhibits interleukin-6 production by bone marrow-derived stromal cells and osteoblasts in vitro: a potential mechanism for the antiosteoporotic effect of estrogens. *J Clin Invest* 1992; 89:883–891.
 34. **Pacifici R, Brown C, Pusheck E, et al.** Effect of surgical menopause and estrogen replacement on cytokine release from human blood mononuclear cells. *Proc Natl Acad Sci USA* 1991; 88:5134–5138.
 35. **Brennan RM, Genco RJ, Wilding GE, Hovey KM, Trevisan M, Wactawski-Wende J.** Bacterial species in subgingival plaque and oral bone loss in postmenopausal women. *J Periodontol* 2007; 78:1051–1061.
 36. **Chestnut CH, Skag A, Christiansen C, et al.** Effects of oral ibandronate administered daily or intermittently on fracture risk in postmenopausal osteoporosis. *J Bone Miner Res* 2004; 19:1241–1249.
 37. **Black DM, Cummings SR, Karpf DB, et al.** Randomized trial of effect of alendronate on risk of fracture in women with existing vertebral fractures: Fracture Intervention Trial Research Group. *Lancet* 1996; 348:1535–1541.
 38. **McClung MR, Geusen P, Miller PD, et al.** Effect of risedronate on the risk of hip fracture in elderly women. *Hip Intervention Program Study Group. N Engl J Med* 2001; 344:333–340.
 39. **Reginster JY, Minne HW, Sorensen OH, et al.** Randomized trial of effects of risedronate on vertebral fractures in women with established postmenopausal osteoporosis. *Vertebral Efficacy with Risedronate Therapy (VERT) Study Group. Osteoporos Int* 2000; 11:83–91.
 40. **Lyles KW, Colon-Emeric CS, Magaziner JS, et al.** Zoledronic acid and clinical fractures and mortality after hip fracture. *N Engl J Med* 2007; 357:1799–1809.
 41. **Palomo L, Bissada N, Liu J.** Periodontal assessment of postmenopausal women receiving risedronate. *Menopause* 2005; 12:685–690.
 42. **Rocha ML, Malacara JM, Sánchez-Marin FJ, Vazquez de la Torre CJ, Fajardo ME.** Effect of alendronate on periodontal disease in postmenopausal women: a randomized placebo-controlled trial. *J Periodontol* 2004; 75:1579–1585.
 43. **Jeffcoat MK, Cizza G, Shih WJ, Genco R, Lombardi A.** Efficacy of bisphosphonates for the control of alveolar bone loss in periodontitis. *J Int Acad Periodontol* 2007; 9:70–76.
 44. **Carey JJ, Palomo L.** Bisphosphonates and osteonecrosis of the jaw: innocent association or significant risk? *Cleve Clin J Med* 2008; 75:871–879.
 45. **Woo SB, Hellstein JW, Kalamare JR.** Narrative [corrected] review: bisphosphonates and osteonecrosis of the jaws. *Ann Intern Med* 2006; 144:753–761.
 46. **Dodson TB, Raje NS, Caruso PA, Rosenberg AE.** Case records of the Massachusetts General Hospital. Case 9-2008. A 65-year-old woman with a nonhealing ulcer of the jaw. *N Engl J Med* 2008; 358:1283–1291.
 47. **Ruggiero SL, Mehrotra B, Rosenberg TJ, Engroff SL.** Osteonecrosis of the jaws associated with the use of bisphosphonates: a review of 63 cases. *J Oral Maxillofacial Surg* 2004; 62:527–534.
 48. **Palomo L, Liu J, Bissada NF.** Skeletal bone diseases impact the periodontium: a review of bisphosphonate therapy. *Expert Opin Pharmacother* 2007; 8:309–315.
 49. **Ezra A, Golomb G.** Administration routes and delivery systems of bisphosphonates for the treatment of bone resorption. *Adv Drug Deliv Rev* 2000; 42:175–195.
 50. **Berenson JR, Rosen L, Vescio R, et al.** Pharmacokinetics of pamidronate disodium in patients with cancer with normal or impaired renal function. *J Clin Pharmacol* 1997; 37:285–290.
 51. **American Dental Association Council on Scientific Affairs.** Dental management of patients receiving oral bisphosphonate therapy: expert panel recommendations. *J Am Dent Assoc* 2006; 137:1144–1150.
 52. **Advisory Task Force on Bisphosphonate-Related Osteonecrosis of the Jaws.** American Association of Oral and Maxillofacial Surgeons position paper on bisphosphonate-related osteonecrosis of the jaws. *J Oral Maxillofacial Surg* 2007; 65:369–376.
 53. **Grbic JT, Landesberg R, Lin SQ, et al; Health Outcomes and Reduced Incidence with Zoledronic Acid Once Yearly Pivotal Fracture Trial Research Group.** Incidence of osteonecrosis of the jaw in women with postmenopausal osteoporosis in the Health Outcomes and Reduced Incidence with Zoledronic Acid Once Yearly Pivotal Fracture Trial. *J Am Dent Assoc* 2008; 139:32–40.

ADDRESS: Maria Clarinda A. Buencamino, MD, Internal Diagnostic Department, E13, Cleveland Clinic, 9500 Euclid Avenue, Cleveland, OH 44195; e-mail buen-cam@ccf.org.