

GEORGEANNE BOTEK, DPM

 Medical Director, Diabetic Foot Center,
 Department of Orthopaedic Surgery,
 Orthopaedic and Rheumatologic Institute,
 Cleveland Clinic

MARTHA A. ANDERSON, DPM

The Toledo Clinic, Toledo, OH

RYAN TAYLOR, DPM

 Timpanogos Foot and Ankle LLC,
 Heber City, UT

Charcot neuroarthropathy: An often overlooked complication of diabetes

ABSTRACT

In patients with long-standing, poorly controlled diabetes and peripheral neuropathy, a red, hot, swollen foot without open ulceration should raise the suspicion of Charcot neuroarthropathy, an often-overlooked diabetic foot complication. The authors discuss key diagnostic features and how to differentiate this condition from cellulitis, osteomyelitis, and other conditions. They review key elements of the workup and emphasize the importance of early diagnosis and prompt treatment to preserve a functioning foot.

KEY POINTS

One must pay particular attention to the history in diabetic patients and assess the risk of diabetic foot complications.

Without the presence or history of an open ulceration, infection is rare.

Paramount to the treatment of this condition are the avoidance of weight-bearing and the immediate referral to a foot and ankle specialist. Prevention, suspicion, early diagnosis, and protection of the involved foot preserve the ability to walk and quality of life.

SEVERAL WEEKS BEFORE coming to our orthopedic surgery clinic, a 53-year-old man presented to an emergency department because of pain, swelling, and redness in his right foot, which began 3 days before. He recalled no overt trauma, but he was jogging when he first noticed the pain, which he described as a constant aching and rated as high as 8 on a scale of 10.

At that time, he had no fever, chills, or night sweats, no cough, and no shortness of breath. About 10 years ago he was diagnosed with diabetes mellitus, for which he currently takes rosiglitazone (Avandia) 2 mg/day and metformin (Glucophage XR) 500 mg four tablets daily. He also takes ramipril (Altace) 10 mg/day for hypertension, as well as a daily multivitamin. He has a history of hyperlipidemia and a family history of diabetes mellitus and Parkinson disease. He has never been hospitalized and has never undergone surgery.

The emergency room evaluation showed that his blood pressure was 160/90 mm Hg, pulse 104, temperature 100.4°F (38°C), weight 104 kg (229 lb), and height 6 feet 1 inch. His heart rate and rhythm were normal, with normal S1 and S2 and no murmurs. His lungs were clear to auscultation. His left foot appeared normal, but his right foot was swollen, hot, and red as far up as the lower leg, and it was hard, especially on the dorsal side; there were small patches of ecchymosis around the second and third toes (FIGURE 1). However, his capillary refill was good bilaterally, and no skin lesions or abrasions were noted.

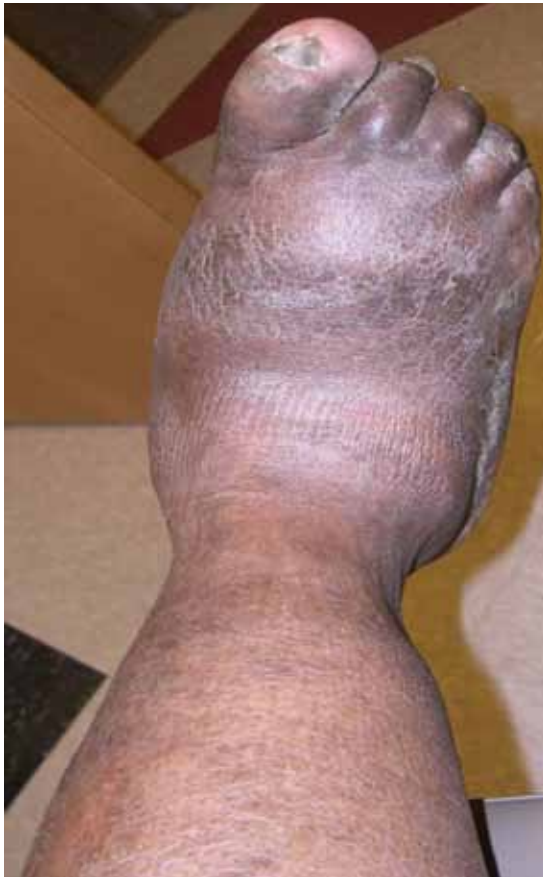

FIGURE 1. The patient's right foot at presentation.

He is 53 years old, with poorly controlled diabetes and peripheral neuropathy

His blood glucose level was 239 mg/dL (normal 70–110), hemoglobin A_{1c} 9.7% (normal 4%–6%), and white blood cell count $13.41 \times 10^9/L$ (normal 4.5–11.0).

Based on that evaluation, the patient was admitted to the hospital with a diagnosis of cellulitis. He received intravenous antibiotics for 3 days and then was discharged with a prescription for oral antibiotics. He visited his primary care physician several times over the next 2 to 4 weeks and then was referred to our orthopedic surgery clinic for further evaluation. A neurologic evaluation in our clinic revealed a loss of protective sensation, contraction of the toes, and dryness, consistent with peripheral neuropathy. Given what we know so far, which is the most likely diagnosis?

■ DIFFERENTIAL DIAGNOSIS

While cellulitis may seem to be the likely diagnosis, if a patient with long-standing

diabetes, a history of poor glycemic control, and peripheral neuropathy presents with a red, hot, swollen foot with no history of open ulceration, then Charcot neuroarthropathy should be at the top of the list in the differential diagnosis. Other possibilities include osteomyelitis, acute gout, cellulitis, abscess, neuropathic fracture, and deep venous thrombosis. However, if the patient has no open ulceration or history of an open wound, infection is probably not the culprit. Most diabetic foot infections begin with a direct inoculation through an opening in the skin, such as a diabetic neuropathic foot ulcer.

Further, in the case of cellulitis or deep venous thrombosis, the predominating feature would be asymmetric edema of the leg. Also, the location of the edema and ecchymosis in our patient—namely, the midfoot—leads to suspicion of an acute musculoskeletal injury, particularly Charcot neuroarthropathy of the midfoot and neuropathic fractures in the region of the ecchymotic second and third digits. Acute gout could be discounted because gout pain is severe, with rapid onset, and slowly improves even without treatment.

■ A COMPLICATION OF DIABETES

Charcot neuroarthropathy presents as a warm, swollen, erythematous foot and ankle, a picture that may be indistinguishable from that of infection. Most patients are in their 50s or 60s, and most present on an emergency basis; they often present late in the process, ie, 2 to 3 months after the initial symptoms, because the symptoms often are not painful.

This condition has been reported to occur with leprosy, syringomyelia, toxic exposure, poliomyelitis, rheumatoid arthritis, multiple sclerosis, congenital neuropathy, traumatic injury, and tertiary syphilis.^{1–4} Other conditions that reportedly trigger it include cellulitis, osteomyelitis, synovitis, surgery of the foot, and renal transplant surgery.^{5–7} However, today, the most common cause is diabetes mellitus.^{4,8}

Other names for this condition are diabetic neuropathic osteoarthropathy and neuropathic arthropathy.

Current estimates of its prevalence range from 0.08% in the general diabetic population to 13% in high-risk diabetic patients.⁹

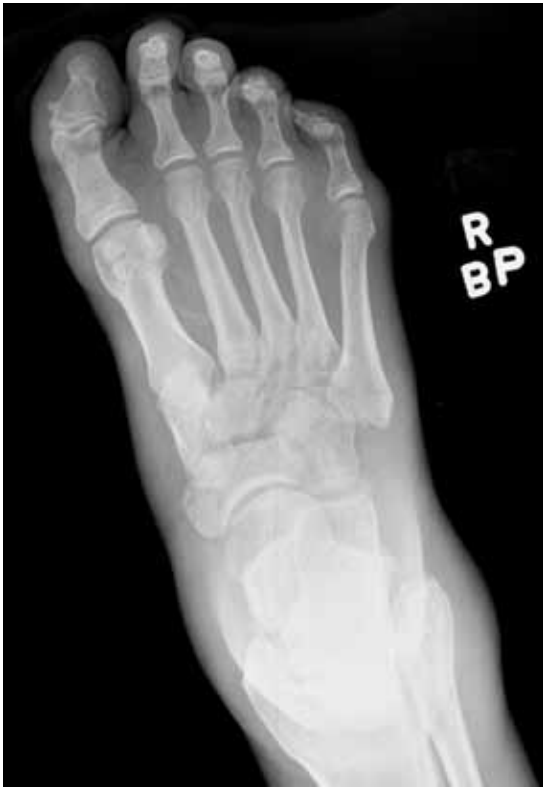

FIGURE 2. Stage 0. A plain anteroposterior radiograph taken in the emergency department shows no osseous abnormalities.

■ CHARCOT NEUROARTHROPATHY BEGINS WITH PERIPHERAL NEUROPATHY

The pathophysiologic mechanism of Charcot neuroarthropathy is not completely known, but it is thought to begin with peripheral neuropathy. Being insensitive to pain, patients may subject the joints of the foot (most commonly in the midfoot) to stress injuries that lead to the active Charcot process.¹⁰⁻¹² About half of Charcot patients present with pain, as did our patient.

Although our patient remembered no trauma, he was physically active at the time he first noticed the symptoms.

Four stages of Charcot neuroarthropathy are recognized¹¹⁻¹⁵:

Stage 0 (inflammation), also called Charcot in situ or pre-stage 1, is characterized by erythema, edema, and heat but no structural changes.^{11,12,14,15}

A radiograph in our patient (**FIGURE 2**) taken during his initial emergency department visit

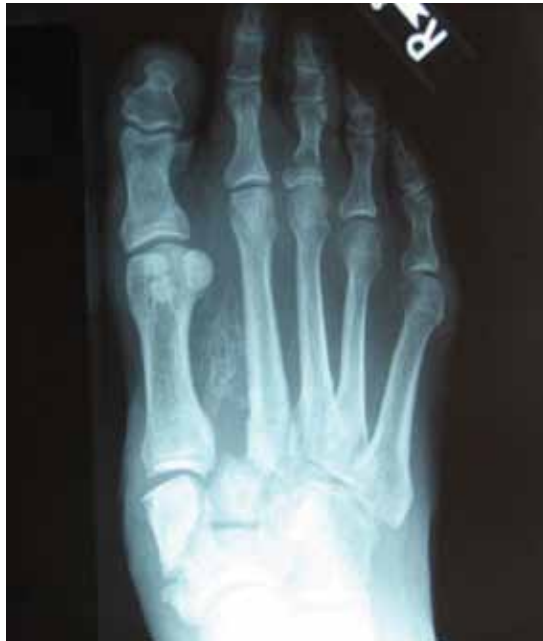

FIGURE 3. In this radiograph taken 3 to 4 months after the initial presentation, Charcot neuroarthropathy has progressed to stage 2 after delayed immobilization.

showed no bony abnormalities. However, if instability, weight-bearing, and inflammation persist, stage 0 can progress to the next stage.

Stage 1 (development) is characterized by bone resorption, bone fragmentation, and joint dislocation. The swelling, warmth, and redness persist, but there are also radiographic changes such as evidence of debris formation at the articular margins, osseous fragmentation, and joint disruption.

Stage 2 (coalescence) involves bony consolidation, osteosclerosis, and fusion after bony destruction. Absorption of small bone fragments, fusion of joints, and sclerosis of the bone are noticeable.

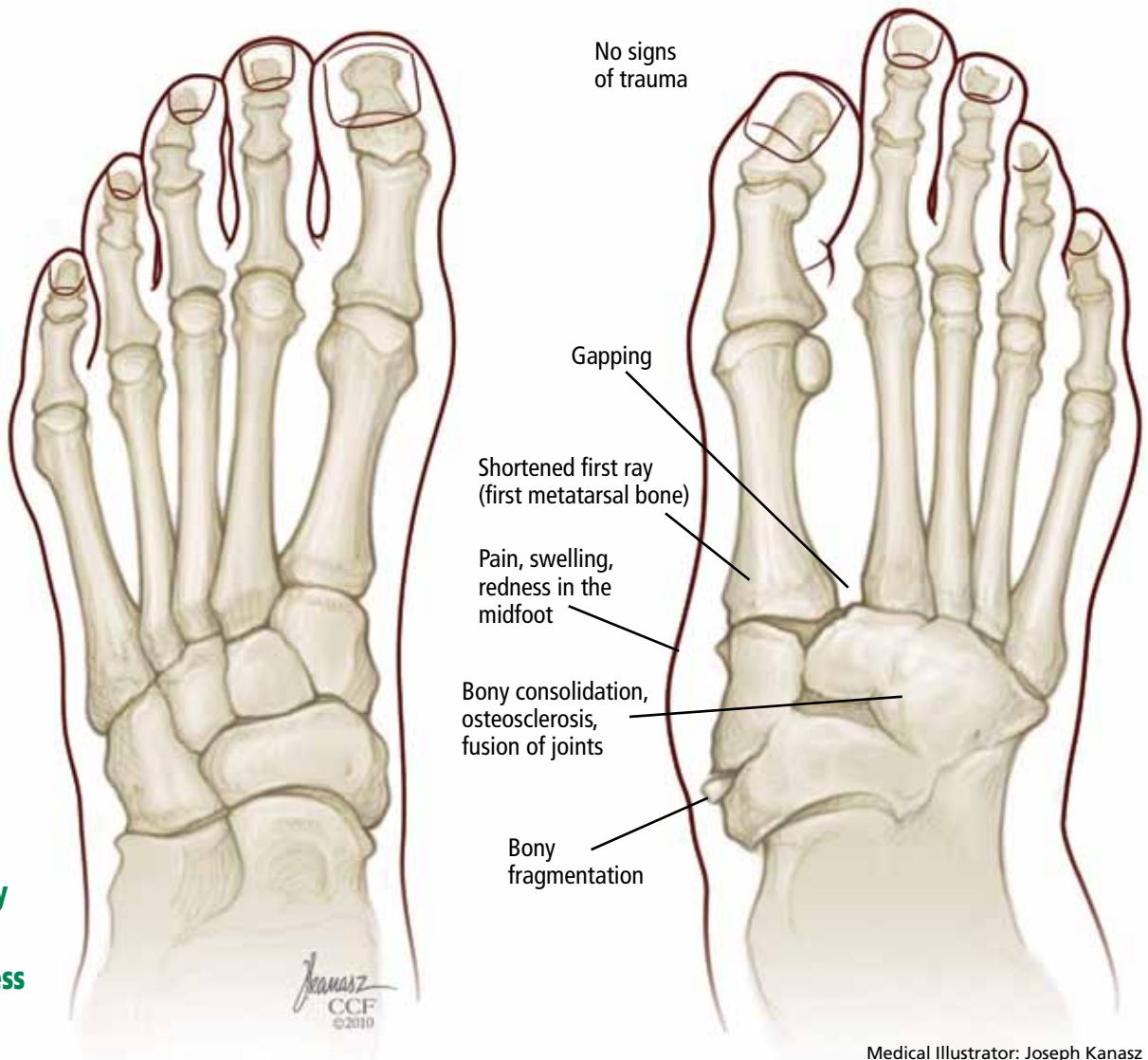
A radiograph in our patient taken 3 to 4 months after presentation (**FIGURE 3**), after treatment had been delayed, showed that his condition had progressed to stage 2.

Stage 3 (reconstruction) is characterized by osteogenesis, decreased osteosclerosis, and progressive fusion.¹³ Healing and new bone formation occur. Decreased sclerosis and bony remodeling signify that the deformity (for example, subluxation, incongruity, and dislocation) is permanent.⁴

Most diabetic foot infections begin with a direct inoculation through an opening in the skin

Normal

Charcot neuroarthropathy



Patients insensitive to pain may subject the foot to stress injuries

Medical Illustrator: Joseph Kanasz

FIGURE 4. Some of the key features of Charcot neuroarthropathy, a complication of diabetes mellitus. The presentation and the course are different in each patient.

■ MISDIAGNOSIS IS COMMON

Charcot neuroarthropathy is an often overlooked complication in diabetic patients with peripheral neuropathy. A group of experts reported that 25% of patients referred to their facility who had Charcot neuroarthropathy had not received a correct diagnosis at the referring institution.¹⁶ The incorrect diagnoses included infection, gout, arthritis, fracture, venous insufficiency, and tumor.

The diagnosis is usually made radiographically or by clinical signs such as erythema,

warmth, or change in foot shape in a neuropathic foot in the absence of a skin wound. However, even if there is no radiographic evidence of overt osseous dislocation or fracture fragmentation, the condition should still be suspected so that treatment, if indicated, can be started promptly. A careful medical history is most helpful in arriving at the diagnosis. Keep in mind that a patient with neuropathy may be unaware of injury to the foot. Also keep in mind that although certain changes are characteristic of Charcot neuroarthropa-

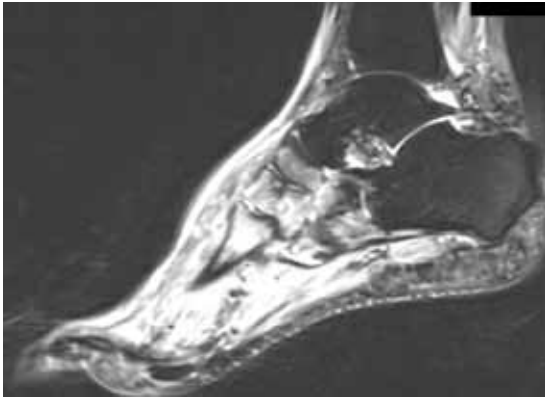


FIGURE 5. Magnetic resonance imaging 4 to 6 weeks after presentation shows areas of significant bone marrow edema of the navicular, medial, middle, and lateral cuneiform bones, and at the bases of several metatarsal bones.

thy, the condition may be different in every patient. **FIGURE 4** illustrates some of the typical changes that can occur at various stages of Charcot neuroarthropathy.

Laboratory tests can narrow the differential diagnosis

There are no laboratory criteria for the diagnosis of Charcot neuroarthropathy and no hematologic markers, but laboratory testing can help narrow the differential diagnosis. Leukocytosis, an elevated C-reactive protein and erythrocyte sedimentation rate, and recent unexplained hyperglycemia suggest infection.¹⁷ However, unremarkable results on clinical tests in this population may not comprehensively exclude infection.

Our patient's elevated white blood cell count confused the diagnosis. Further, when he was treated with antibiotics, he reported having less pain, although the edema and erythema continued.

Imaging studies

Although advanced imaging may help confirm the diagnosis of Charcot neuropathy in some patients, it is not always necessary.

Radiography. Radiographic findings are important in diagnosing Charcot neuroarthropathy, although they are less helpful in patients with stage 0 disease, such as our patient, in whom the condition has not yet progressed to fracture or dislocation. All foot

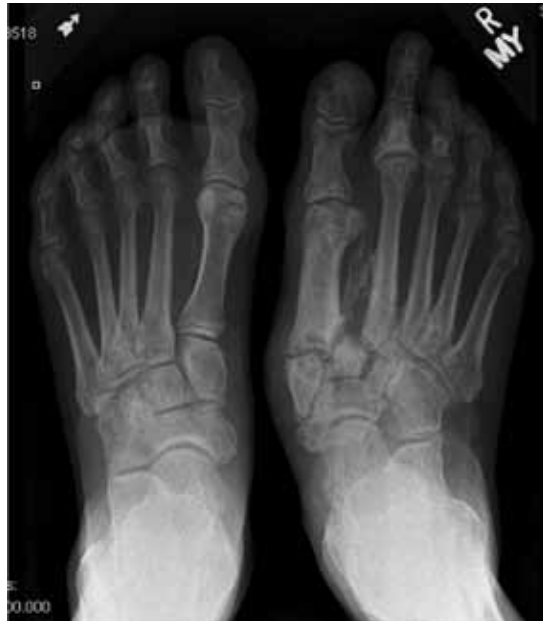

FIGURE 6. Stage 3. This plain radiograph shows the reconstruction stage with resolved edema, absence of osteosclerosis, and relative osteopenia. Also seen is healing of the fractures of the second and third proximal phalanges, the site of the ecchymosis on plain films in **FIGURE 2**.

and ankle radiographs should be taken in the weight-bearing position. Subtle changes may be missed if non-weight-bearing images are taken.

Magnetic resonance imaging (MRI) can show changes in stage 0, thus enabling treatment to be started sooner,¹⁸ and it is increasingly being recommended for diagnosing Charcot neuroarthropathy, especially in the early stages.³ Although bone scintigraphy and white blood cell scans have been traditionally advocated, MRI offers the highest diagnostic accuracy.¹⁹ Signs on MRI consistent with Charcot neuroarthropathy include ligamentous disruption, concomitant joint deformity, and the center of signal enhancement within joints and subchondral bone.²⁰

MRI can also differentiate Charcot neuroarthropathy from transient regional osteoporosis. The latter has a different anatomic location and does not cause fractures and dislocations, and patients do not have a clinical history of pain.

Another condition MRI can identify is complex regional pain syndrome. In this con-

In these patients, all foot and ankle radiographs should be taken in the weight-bearing position

dition, patients have no radiographic abnormalities except for periarticular osteopenia, but they may have severe pain out of proportion with the clinical appearance, and they may develop soft-tissue deformity in the late stages, which is not seen in Charcot neuroarthropathy.

MRI findings in our patient 4 to 6 weeks after the initial presentation were characteristic of Charcot neuroarthropathy (FIGURE 5).

Positron emission tomography (PET) with fluorine-18 fluorodeoxyglucose is also gaining support,²¹ especially when combined with computed tomography (CT). This PET-CT hybrid has better anatomic localization than PET alone.

PET-CT is very reliable for differentiating Charcot neuroarthropathy from osteomyelitis, a distinction that can be difficult to make when Charcot neuroarthropathy is complicated by adjacent loss of skin integrity. The sensitivity of PET-CT in this situation has been reported as 100%, and its sensitivity 93.8%.²²

Patients with Charcot neuroarthropathy demonstrate a low-intensity diffuse uptake that is easily distinguishable from normal joints on visual examination of the images. In addition, the maximum standardized uptake value, a quantitative measurement, is low to intermediate in Charcot neuroarthropathy but significantly higher in osteomyelitis. In one study,²² the mean standardized uptake values were 0.42 in normal feet, 1.3 in Charcot neuroarthropathy, and 4.38 in osteomyelitis.

■ TREATMENT: IMMOBILIZATION, BISPHOSPHONATES, SURGERY

The goals of treatment for acute or quiescent Charcot neuroarthropathy should be to maintain or achieve structural stability of the foot and ankle, to prevent skin ulceration, and to preserve the plantigrade shape of the foot so that prescription footwear can be used.

In stages 0 and 1, the initial treatment is immediate immobilization and avoidance of weight-bearing. Elevated skin temperature and persistent edema at the involved site sug-

gest that the condition has not yet progressed to stage 2. If the problem is diagnosed early and treatment is started promptly, the probability of preserving the bony pedal architecture is much better. If the diagnosis is delayed or if treatment is not adhered to, significant deformity can result (FIGURE 6).

Patient and family education is important for compliance with the regimen, particularly because patients with diabetic neuropathy lack the protective pain response.

Immobilization. A total-contact cast is worn until the redness, swelling, and heat subside, generally 8 to 12 weeks, after which the patient should use removable braces or a Charcot restraint orthotic walker for a total of 4 to 6 months of treatment.²³ The cast is typically changed every 1 to 2 weeks as the swelling subsides to minimize irritation to the insensate limb.

Many physicians also recommend elastic stockings (eg, Stockinette) or an elastic tubular bandage (eg, Tubigrip) to reduce edema under the cast.

Bisphosphonates. Some clinicians also prescribe bisphosphonates in the early stages of treatment, as the bone mineral density of the affected foot is low.²⁴ Unfortunately, while these drugs can significantly reduce the levels of bone turnover markers, temperature, and pain, evidence of clinical benefit such as an earlier return to ambulation or radiographic improvement is weak at best.

Surgery is reserved for severe ankle and midfoot deformities that are susceptible to skin ulcerations and that make braces and orthotic devices difficult to use.

■ TREATMENT OUTCOME

The patient's condition resolved, with eventual multiplanar deformity and with widening of the midfoot and increased pressure points, particularly to the first ray. He is able to wear an extra-depth shoe, with a custom total-contact inlay. He continues his profession as an attorney and goes about his normal daily activities; however, he is no longer able to golf and must limit his walking. He subsequently developed ulcerations to both feet, but they resolved with conservative wound care and surgical care. He is seen in the diabetic foot clinic every 6 to 8 weeks. ■

Prevention, heightened suspicion, early diagnosis, and protection of the foot preserve ambulation and improve quality of life

REFERENCES

1. **Gupta R.** A short history of neuropathic arthropathy. *Clin Orthop Relat Res* 1993; 296:43–49.
2. **Johnson JT.** Neuropathic fractures and joint injuries. Pathogenesis and rationale of prevention and treatment. *J Bone Joint Surg Am* 1967; 49:1–30.
3. **Sanders LJ, Frykberg RG.** The Charcot Foot (Pied de Charcot). In: Bowker JH, Pfeifer MA, editors. *Levin and O'Neal's The Diabetic Foot*. 7th ed. Philadelphia, PA: Mosby Elsevier; 2008:257–283.
4. **Wukich DK, Sung W.** Charcot arthropathy of the foot and ankle: modern concepts and management review. *J Diabetes Complications* 2009; 23:409–426.
5. **Armstrong DG, Todd WF, Lavery LA, Harkless LB, Bushman TR.** The natural history of acute Charcot's arthropathy in a diabetic foot specialty clinic. *J Am Podiatr Med Assoc* 1997; 87:272–278.
6. **Jeffcoate WJ.** Theories concerning the pathogenesis of the acute Charcot foot suggest future therapy. *Curr Diab Rep* 2005; 5:430–435.
7. **Matricali GA, Bammens B, Kuypers D, Flour M, Mathieu C.** High rate of Charcot foot attacks early after simultaneous pancreas-kidney transplantation. *Transplantation* 2007; 83:245–246.
8. **Miller DS, Lichtman WF.** Diabetic neuropathic arthropathy of feet; summary report of seventeen cases. *AMA Arch Surg* 1955; 70:513–518.
9. **Frykberg RG, Belczyk R.** Epidemiology of the Charcot foot. *Clin Podiatr Med Surg* 2008; 25:17–28.
10. **Chantelau E.** The perils of procrastination: effects of early vs delayed detection and treatment of incipient Charcot fracture. *Diabet Med* 2005; 22:1707–1712.
11. **Schon LC, Marks RM.** The management of neuropathic fracture-dislocations in the diabetic patient. *Orthop Clin North Am* 1995; 26:375–392.
12. **Sella EJ, Barrette C.** Staging of Charcot neuroarthropathy along the medial column of the foot in the diabetic patient. *J Foot Ankle Surg* 1999; 38:34–40.
13. **Eichenholtz SN.** *Charcot Joints*. Springfield, IL: CC Thomas; 1966.
14. **Shibata T, Tada K, Hashizume C.** The results of arthrodesis of the ankle for leprotic neuroarthropathy. *J Bone Joint Surg Am* 1990; 72:749–756.
15. **Yu GV, Hudson JR.** Evaluation and treatment of stage 0 Charcot's neuroarthropathy of the foot and ankle. *J Am Podiatr Med Assoc* 2002; 92:210–220.
16. **Myerson MS, Henderson MR, Saxby T, Short KW.** Management of midfoot diabetic neuroarthropathy. *Foot Ankle Int* 1994; 15:233–241.
17. **Judge MS.** Using serologic screening to identify and monitor at-risk Charcot patients. *Podiatry Today Magazine* 2004; 17:75–82.
18. **Chantelau E, Poll LW.** Evaluation of the diabetic Charcot foot by MR imaging or plain radiography—an observational study. *Exp Clin Endocrinol Diabetes* 2006; 114:428–431.
19. **Tan PL, Teh J.** MRI of the diabetic foot: differentiation of infection from neuropathic change. *Br J Radiol* 2007; 80:939–948.
20. **Ledermann HP, Morrison WB.** Differential diagnosis of pedal osteomyelitis and diabetic neuroarthropathy: MR Imaging. *Semin Musculoskelet Radiol* 2005; 9:272–283.
21. **Höpfner S, Krolak C, Kessler S, et al.** Preoperative imaging of Charcot neuroarthropathy in diabetic patients: comparison of ring PET, hybrid PET, and magnetic resonance imaging. *Foot Ankle Int* 2004; 25:890–895.
22. **Basu S, Chryssikos T, Houseni M, et al.** Potential role of FDG PET in the setting of diabetic neuro-osteopathy: can it differentiate uncomplicated Charcot's neuroarthropathy from osteomyelitis and soft-tissue infection? *Nucl Med Commun* 2007; 28:465–472.
23. **Frykberg RG, Zgonis T, Armstrong DG, et al; American College of Foot and Ankle Surgeons.** Diabetic foot disorders. A clinical practice guideline (2006 revision). *J Foot Ankle Surg* 2006; 45(suppl 5):S1–S66.
24. **Young MJ, Marshall A, Adams JE, Selby PL, Boulton AJ.** Osteopenia, neurological dysfunction, and the development of Charcot neuroarthropathy. *Diabetes Care* 1995; 18:34–38.

ADDRESS: *Georgianne Botek, DPM, Department of Orthopaedic Surgery, Orthopaedic and Rheumatologic Institute, A40, Cleveland Clinic, 9500 Euclid Avenue, Cleveland, OH 44195; e-mail botekg@ccf.org.*

Cleveland Clinic
Endocrinology & Metabolism Institute

In conjunction with
American Association of Clinical Endocrinologists
American College of Endocrinology

13th Annual
Endocrinology & Metabolism Board Review 2010

October 15 – 17, 2010

InterContinental Hotel & Bank of America Conference Center
Cleveland, Ohio

This activity has been approved for *AMA PRA Category 1 Credit™*.

Register Today!
www.ccfcm.org/endoreview10