

INTESTINAL ANGINA

Report of Four Cases

JACOB FINKELSTEIN, M.D.*

Department of Medicine

THE syndrome of intestinal angina is characterized by cramping abdominal pain that usually develops in from 15 to 30 minutes after eating, and persists for from one to three hours. The severity and duration depend upon the amount of food ingested: the larger the amount of food ingested, the greater is the intensity and the longer is the duration of the pain. Initially, the pain may occur only after the largest meal. As weeks or months elapse, there is progressive, steady increase in the severity of symptoms. Nausea, vomiting, or diarrhea may occur. The "food-pain" sequence is the dominant feature, and soon leads to a reluctance to eat; loss in weight inevitably follows.¹

Intestinal angina may be difficult to diagnose. Findings on physical examination, even in the presence of pain, are not diagnostic. Loss in weight is always evident, and mild abdominal distention may be present. In some patients a systolic bruit is audible in the upper part of the abdomen.² When symptoms are mild and vague, the condition often is diagnosed as functional indigestion or the irritable bowel syndrome, especially after complete gastrointestinal roentgenograms show evidence of normal function. A diagnosis of disease more serious than functional indigestion, such as pancreatic carcinoma or pancreatitis, may be considered when symptoms are severe, and an exploratory abdominal operation may be advised. The true diagnosis may not be determined until postmortem studies reveal a gangrenous bowel.

The pathologic process producing intestinal angina is known to be the arteriosclerotic narrowing and obliteration of the ostia of the gastrointestinal branches of the abdominal aorta. When this occurs in the superior mesenteric artery it is usually limited to the ostium or to the first 2 or 3 cm. of this vessel. The occlusion may be due primarily to aortic atherosclerosis that envelops the orifice of the superior mesenteric artery; it may consist primarily of intimal proliferation of the first few centimeters of this artery itself; or a combination of the two mechanisms may exist.²

It is the purpose of this paper to report four cases of intestinal angina which illustrate the difficulties of diagnosis, and to review some features of the syndrome.

Report of Cases

Case 1. A 56-year-old man who had two previous episodes of myocardial infarction was admitted to the Cleveland Clinic Hospital because of constant severe midabdominal cramping of four days' duration. The intense pain had been relieved only by injections of narcotics. There

**Clinical Associate in the Department of Medicine.*

was nausea without vomiting. Bowel habits were normal and there had been no melena.

For about four years, the patient had intermittent abdominal distress consisting of cramplike pain in the midabdomen, occurring from 30 minutes to one hour postprandially; function, according to gastrointestinal roentgenograms at that time, was normal. About one year before examination here, the patient noted that he "felt full" after eating only small amounts of food. This had resulted in a loss in weight of approximately 50 pounds.

Examination of the abdomen revealed generalized tenderness, with rebound tenderness in the right lower quadrant. No organs or masses were palpable. Bowel sounds were absent. The white blood cell count was 19,800 per cubic millimeter, with 93 percent neutrophils, 5 percent lymphocytes, and 2 percent monocytes. Exploratory laparotomy was performed. At operation, thrombosis of the superior mesenteric artery and a gangrenous small bowel were found. Resection of the small bowel was performed with an end-to-end jejunioileostomy (Hofmeister technic). One week after operation the patient died, and postmortem examination revealed extensive atheromatous disease of the superior mesenteric artery. Ulcerated patches were scattered throughout the colon. At the cecal portion of the colon near the site of the anastomosis the greenish-blue to black mucosa was ulcerated.

Case 2. A 48-year-old man had cramping in the lower abdomen occurring about 30 minutes after each meal for five months before admission to the Cleveland Clinic Hospital. Two weeks before admission, the distress became constant and so intense that relief was obtained only with narcotics. The pain was accompanied by nausea but not by vomiting. There was long-standing difficulty with bowel movement which necessitated use of laxatives; however, for the two weeks before admission to the hospital, bowel function was normal.

Pertinent physical findings were localized to the abdomen and the peripheral blood vessels. The abdomen was distended and extremely tender; no organs or masses were palpable; bowel sounds were absent; and no pulse below the right common iliac artery was palpable. The right foot was colder than the left foot. The white blood cell count was 33,000 per cubic millimeter, with 92 percent neutrophils and 8 percent lymphocytes. Roentgenograms of the abdomen showed evidence of obstruction of the small bowel.

The patient's condition rapidly worsened within 24 hours, and he died shortly thereafter. At postmortem examination the celiac artery and the superior mesenteric artery were occluded for a distance of 2 cm. and 3 cm., respectively, by a mass of firm yellow-gray material with a well-organized thrombus. There was massive gangrene of the entire small bowel. The lumen of the right common iliac artery was occluded with a recent thrombus that was in part cellular, but fibrin and fibrous tissue were within the substance of the clot. Extensive arteriosclerotic changes were present with complete destruction of the elastic tissue layer.

Case 3. A 69-year-old woman was admitted to the Cleveland Clinic Hospital because of intermittent lower abdominal cramping of one year's duration. The cramping sometimes had been associated with nausea but there had been no vomiting. Diarrhea was occasionally present, consisting of loose feces with no blood, pus, mucus, or melena. About six months previously, the pains increased in severity, occurring in from 10 to 30 minutes after eating even small amounts of food. She was hospitalized elsewhere, but roentgenographic studies of the gastrointestinal tract showed normal function. The food-pain sequence drastically limited the food intake, and resulted in the loss of 30 pounds in weight in the six-month period.

On admission to the hospital here, her physical appearance showed obvious loss of weight. The abdomen was soft, with some minimal tenderness in the lower quadrants; there were no palpable organs or masses, no bruits were heard, and bowel sounds were normal. A grade 2 bruit was audible over the right carotid artery and the innominate artery. The posterior tibial and dorsalis pedis pulses were absent in the right and greatly diminished in the left lower extremities.

INTESTINAL ANGINA

The white blood cell count was 15,400 per cubic millimeter, with 74 percent segmented, 16 percent nonsegmented, 4 percent lymphocytes, and 6 percent monocytes. On the following evening, severe tachycardia, acute abdominal distention, and severe lower abdominal pains suddenly developed. The white blood cell count at that time was 22,000 per cubic millimeter, with 60 percent segmented, 34 percent nonsegmented, 3 percent lymphocytes, and 3 percent monocytes. Exploratory laparotomy was performed; the superior mesenteric artery was found to be occluded, and there was gangrene of the entire small bowel. The small bowel was resected from the ligament of Treitz to within four inches of the cecum with an end-to-end anastomosis of the remaining small bowel. The patient died two weeks after operation. Postmortem examination revealed severe generalized arteriosclerosis involving the carotid arteries, aorta, the renal, mesenteric, iliac, and coronary arteries. Microscopic examination of the superior mesenteric artery disclosed severe arteriosclerosis with large plaques. Much of the remaining intestinal tract was friable, discolored (greenish tan), and inseparable from the other organs and the mesentery.

Case 4. A 65-year-old man was admitted to the Cleveland Clinic Hospital because of constant "gnawing" in the epigastrium, for from six months' to one year's duration. The distress was worse in from 5 to 30 minutes after meals, with tenderness just above the navel. The pain was accompanied by nausea but no vomiting. Bowel movements were normal; however, the patient stated he passed black feces on a few occasions in the last two years. There was no history of weight loss.

Pertinent physical findings were localized to the abdomen, where there was slight tenderness in the epigastric region. The liver was palpable from 1 to 2 cm. below the right costal margin. There was no splenomegaly. A coarse musical bruit was heard just below the xiphoid and left costal region. There was no abdominal aortic enlargement. The white blood cell count was 5,500 per cubic millimeter, with a normal differential count. *Fecal determinations for blood on several occasions revealed one plus guaiac.* An electrocardiogram showed right bundle branch block.

Roentgenograms of the kidney, ureter, and bladder, in the anteroposterior and lateral projections did not show calcification in the aorta. Roentgenograms of the esophagus, stomach, and duodenum showed normal structures. A small-bowel series of roentgenograms showed normal structures. An aortogram was performed using 70% Urokon injected into the abdominal aorta via the translumbar approach at the level of the second lumbar vertebra. At the level of the first lumbar vertebra, a single vessel was seen to arise from the anterior wall of the abdominal aorta (*Fig. 1, 2*), and which probably represented the superior mesenteric artery. There was slight irregularity and possible constriction of its orifice in the first two centimeters. Repair of this defect was advised, and at operation an atherosclerotic plaque at the branching of the superior mesenteric artery was causing approximately 50 percent of the stenosis of this vessel. The aorta at the region of the celiac axis was involved in a moderate amount of atherosclerotic disease, and this process seemed to produce a cuff around the origin of the celiac axis.

An arterotomy of the superior mesenteric artery, and an anterior and a posterior arterotomy of the celiac axis were performed with a Dacron patch of the anterior arterotomy of the celiac axis; also endarterectomies both of the superior mesenteric and the celiac axis were performed. The patient had a stormy postoperative course complicated by staphylococcal enteritis. Despite measures to combat this complication, he died five days after surgery. There was no postmortem examination.

Comment

In the four patients having arteriosclerotic involvement of the abdominal arteries, multiple presumptive diagnoses were made, including pancreatitis, chole-

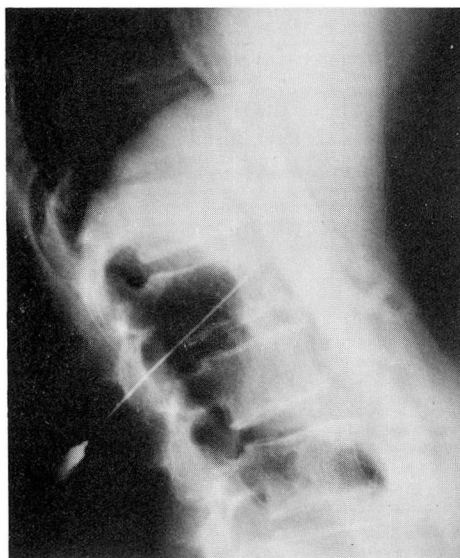


Fig. 1. Case 4. Aortogram in the lateral projection showing a portion of the abdominal aorta, celiac axis, and superior mesenteric artery, with evidence of arteriosclerotic disease in these vessels.

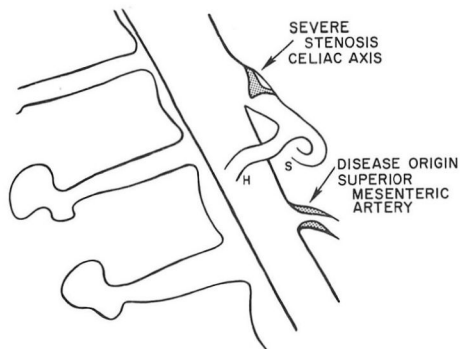


Fig. 2. Case 4. Diagram of the vessels and lesions demonstrated in *Figure 1*: H, hepatic artery; S, splenic artery.

cystitis (acute or chronic), diverticulitis with perforation, dissecting aneurysm of the aorta, mesenteric thrombosis, pancreatic neoplasm, appendicitis with perforation, functional indigestion, gastroenteritis, and peptic ulcer. It is apparent from this array of diagnoses that intestinal angina can mimic many diseases.

Although the clinical diagnosis is based on the exclusion of other causes of postcibal pain, there appear to be two characteristics of intestinal angina that may be helpful in differential diagnosis. Firstly, the distinctive food-pain sequence in the patient is a factor that has been noted often¹⁻¹³ as well as in the cases reported

INTESTINAL ANGINA

here. Mikkelsen and Berne² point out that it would be unusual to encounter an entity other than *intestinal angina* in which so distinct a food-pain sequence is not accompanied by at least one positive finding in the physical, laboratory, or roentgen examinations. Secondly, the arteriosclerotic disease frequently is present in other vessels in these patients; this may be in the form of coronary artery or peripheral artery disease.^{1, 4, 7, 9, 11}

Although the findings on roentgenograms of the gastrointestinal tract usually are normal in persons having *intestinal angina*, roentgenography can be an important asset in the diagnosis of this disease: visualization of arteriosclerotic occlusive disease in the abdominal vessels is possible by means of aortography. Even arteriographic studies frequently fail to demonstrate the lesions because during standard aortography performed in the posteroanterior projection the celiac and superior mesenteric arteries, which arise anteriorly, are obscured by the aorta. When, however, the exposure is made in the lateral position, an occlusive process either in the celiac or in the superior mesenteric arteries is readily visualized.⁸

The elective surgical revascularization of the superior mesenteric artery, of the celiac axis, or of both vessels, is the only rational therapeutic approach to the syndrome of *intestinal angina*. Various revascularization technics are employed for restoration of normal blood flow to the abdominal viscera, including endarterectomy, resection, replacement with a graft, and bypass with a graft.

A considerable number of patients with *intestinal angina* eventually die as the result of the development of occlusion of the mesenteric artery and gangrene of the bowel. It is believed that *intestinal angina*, in fact, should be considered prodromal of occlusion of the mesenteric artery.

Summary

Four cases of *intestinal angina* due to arteriosclerotic occlusion of the superior mesenteric and celiac arteries are reviewed in order to emphasize further this syndrome. Diagnosis of *intestinal angina* is difficult to establish. Physical findings are not invariably diagnostic, and complete gastrointestinal roentgenograms show normal function. However, there is a distinctive food-pain sequence, and frequently arteriosclerotic disease in other vessels—two factors that may be correlated in order to make the clinician aware of the entity of *intestinal angina*.

Acknowledgment

The author wishes to thank Dr. Victor G. deWolfe and Dr. Jess R. Young, of the Department of Peripheral Vascular Disease, for their encouragement and advice in the preparation of this manuscript.

References

1. Mikkelsen, W. P., and Zaro, J. A., Jr.: *Intestinal angina*; report of case with preoperative

- diagnosis and surgical relief. *New England J. Med.* **260**: 912-914, 1959.
2. Mikkelsen, W. P., and Berne, C. J.: Intestinal angina. *S. Clin. North America* **42**: 1321-1328, 1962.
 3. Berman, L. G., and Russo, F. R.: Abdominal angina. *New England J. Med.* **242**: 611-613, 1950.
 4. Case records of Massachusetts General Hospital; case 44332; presentation of case. *New England J. Med.* **259**: 347-351, 1958.
 5. Derrick, J. R.; Pollard, H. S., and Moore, R. M.: Pattern of arteriosclerotic narrowing of celiac and superior mesenteric arteries. *Ann. Surg.* **149**: 684-689, 1959.
 6. Dunphy, J. E.: Abdominal pain of vascular origin. *Am. J. M. Sc.* **192**: 109-113, 1936.
 7. Mandell, H. N.: Abdominal angina; report of case and review of literature. *New England J. Med.* **257**: 1035-1036, 1957.
 8. Morris, G. C., Jr., and DeBakey, M. E.: Abdominal angina—diagnosis and surgical treatment. *J.A.M.A.* **176**: 89-92, 1961.
 9. Morris, G. C., Jr.; Crawford, E. S.; Cooley, D. A., and DeBakey, M. E.: Revascularization of celiac and superior mesenteric arteries. *Arch. Surg.* **84**: 95-107, 1962.
 10. Sedlacek, R. A., and Bean, W. B.: Abdominal "angina": syndrome of intermittent ischemia of mesenteric arteries. *Ann. Int. Med.* **46**: 148-152, 1957.
 11. Shaw, R. S., and Maynard, E. P., III: Acute and chronic thrombosis of mesenteric arteries associated with malabsorption; report of two cases successfully treated by thromboendarterectomy. *New England J. Med.* **258**: 874-878, 1958.
 12. Young, J. R.; Britton, R. C.; deWolfe, V. G., and Humphries, A. W.: Intestinal ischemic necrosis following abdominal aortic surgery. *Surg. Gynec. & Obst.* **115**: 615-620, 1962.
 13. Masson, N. L., and Stayman, J. W., Jr.: Intestinal angina. *Am. J. Surg.* **104**: 500-505, 1962.