CLEVELAND CLINIC QUARTERLY
Volume 38, October 1971
Copyright © 1971 by The Cleveland Clinic Foundation
Printed in U.S.A.

Renal changes in progressive systemic sclerosis

Report of five cases

DONALD G. VIDT, M.D.
Department of Hypertension and Nephrology

ABEL L. ROBERTSON, JR., M.D., PH.D.
Division of Research

SHARAD D. DEODHAR, M.D., PH.D.
Division of Laboratory Medicine

IT IS well recognized that in patients with progressive systemic sclerosis (PSS) rapidly progressive renal failure may develop at any time during the course of the disease in association with severe hypertension, and result in death from uremia.[1-5] The kidneys in those patients usually are described as having undergone two characteristic histologic changes: (1) intimal proliferation of interlobular arteries having a mucoid appearance, and (2) fibrinoid deposition in the intima or media of more distal interlobular arteries and afferent arterioles. These lesions comprise what is termed the "true scleroderma kidney." Other changes that affect the glomeruli have received but limited interest. Our report presents five cases of PSS that demonstrated a variable clinical course and a spectrum of anatomic changes involving excretory as well as vascular structures of the renal cortex.

Specimens of renal tissue were obtained either by percutaneous needle biopsy with a modified Vim-Silvermann needle, under local anesthesia, or at autopsy. Specimens for light microscopy were divided into matched samples, half of which were fixed in Zenker's solution, dehydrated, and embedded in paraffin. Six-micron-thick sections were stained with hematoxylin-eosin, Masson's trichrome, PAS-alcian blue for mucopolysaccharides, Verhoeff's stain for elastica, and Bowie's stain for juxtaglomerular granules. The other half of the matched samples was sectioned in a cryostat after having been fixed in 4 percent phosphate buffered formalin and stained with Sudan IV or oil red O stains for lipids. For immunofluorescent studies, the renal tissue was frozen and sectioned (4 to 6 microns thick) on a cryostat. The sections were stained with fluorescent antihuman γ-globulin (IgG), anti-IgM and anticomplement (C'3 component), and were examined in a Zeiss fluorescent microscope.

Electron microscopic studies were performed on specimens fixed in 1 percent phosphate buffered gluteraldehyde at 4 C for 30 min, followed by rinsing in phosphate buffer and postfixation in 1 percent buffered osmium tetroxide, dehydrated in ascending concentrations of ethanol and embedded in Epon

resin. One-micron thick sections were stained with toluidine blue or silver nitrate for orientation. Thin sections were made in an LKB ultratome, were stained with uranyl acetate-lead citrate, and examined in a Siemens Elmiskop 1-electron microscope.

Report of cases

Case 1. A 53-year-old man was first examined at the Cleveland Clinic in April 1965. Two years previously he had migratory arthralgias, and the skin of the hands became progressively tighter and somewhat painful with motion. In October 1964, at another institution, the diagnosis of scleroderma was established from skin biopsy. Dysphagia and progressive weight loss occurred during the six months before the initial evaluation. On physical examination, the blood pressure was 164/100 mm Hg. The skin over the hands, arms, face, and chest was tightly bound down; skin over the lower extremities also was bound tightly to underlying tissues, and scattered telangiectasias were present. Results of urinalysis were normal.

In February 1966, blood pressures ranging from 170/100 to 182/128 mm Hg were controlled with a combination of methyldopa and hydralazine. A creatinine clearance was 35 ml per minute, the blood urea nitrogen was 27 mg per 100 ml, and ranged as high as 55 mg per 100 ml. Quantitative urine protein excretion was 580 mg per 24 hr. During the next two weeks the serum creatinine concentration increased from 1.6 mg to 4.1 mg per 100 ml, with a further reduction in the creatinine clearance to 24 ml per minute. A renal biopsy was performed at that time.

The patient was admitted to the Cleveland Clinic Hospital for the last time in March 1966 because of somnolence, nausea, and vomiting. The blood urea nitrogen was 91 mg per 100 ml, and the serum creatinine 8.1 mg per 100 ml. Blood pressure was 200/105 mm Hg despite antipressor therapy. Renal function continued to deteriorate and the patient died on March 20, 1966.

Renal findings. The anatomic changes at biopsy and autopsy were quite similar, being those of malignant nephrosclerosis compatible with those described as occurring in PSS. These changes included intimal proliferation of interlobular arteries with hyalinization and onion skin changes and severe narrowing of vascular lumens (*Fig. 1A*). Focal fibrinoid deposits were noted in small arteries. Immunofluorescent studies demonstrated significant deposition of γ-globulin and complement in the walls of small arteries.

Ultrastructural studies (*Fig. 1B*) showed severe intimal hyperplasia and thickening of internal elastic and collagen fibers in the media of interlobular arteries (*Fig. 1B*). There was extensive thickening of basement membranes in glomerular tufts, with increased numbers of mesangial cells. Irregular endothelial cells with organelles were noted. The glomeruli had amorphous basement membranes with scattered subendothelial hyaline deposits with a periodicity of 90 to 120 Å units. Some smooth muscle cells contained lipofuchsin granules.

Case 2. A 41-year-old woman was first examined at the Cleveland Clinic in June 1966. Three years previously she had recurrent myalgias followed by the onset of typical symptoms of Raynaud's phenomenon in the fingers. During the 18 months before evaluation, she had anorexia, dysphagia, diarrhea (15 to 20 foul-smelling stools per day), and lost 50 pounds.

On initial examination, the patient's blood pressure was 110/80 mm Hg, and she weighed 99 pounds. The optic fundi were normal. The skin revealed the typical changes of scleroderma over the arms and lower extremities with notable depigmentation in the axillae. There was generalized abdominal tenderness and no peripheral edema. Serum creatinine concentration was 0.8 mg per 100 ml; the blood urea nitrogen was 7 mg per 100 ml; the serum carotene value was decreased to 20 mg per 100 ml. Examination of the stool revealed increased fat content and the D-xylose absorption was 3.4 g in 5 hr. Urine protein excretion ranged from 13.2 to 17.5 g per 24 hr. The roentgenograms of the esophagus showed lack of motility consistent with scleroderma, and the small-bowel showed evidence of distention and thickening of mucosal folds. Skin and renal biopsies were performed; the former disclosed sclerodermatous changes. Pulmonary function studies showed a greatly reduced diffusing capacity for carbon monoxide compatible with an alveolar capillary block. There was mild hypoxemia but no carbon dioxide retention.

At the last progress examination in October 1966, the patient was extremely weak, she had

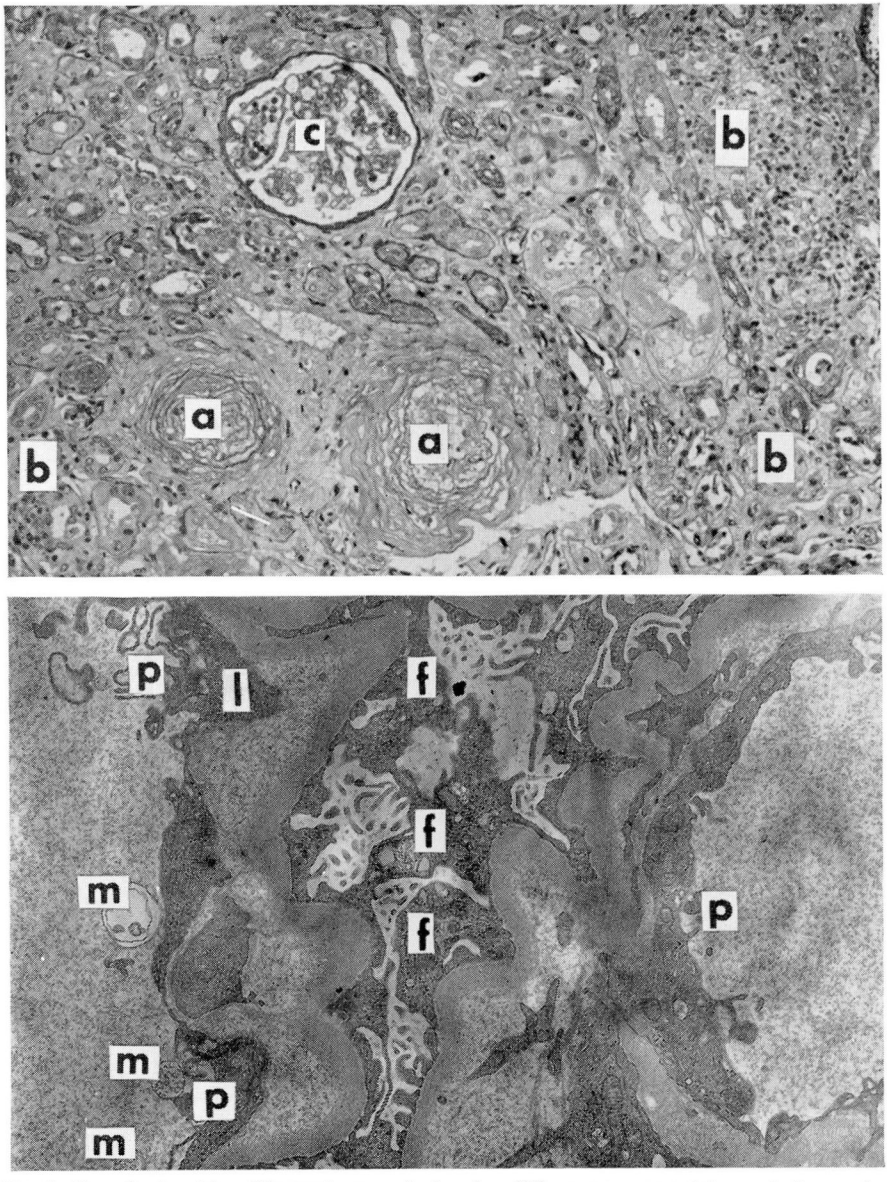

Fig. 1. Case 1. A, *upper,* Photomicrograph showing diffuse severe arteriolar and glomerular changes compatible with chronic malignant nephrosclerosis and PSS. Note reduplication of elastic fibers in interlobular arterioles (a), diffuse tubular changes (b), and vacuolization and dilatation of capillaries in glomerular tuft (c). PAS-Alcian blue stains; magnification × 272. B, *lower,* Electron micrograph of glomerular tuft showing thickening of basement membrane under endothelial cells containing many organelles and a lipid droplet (l). Note abundance of cytoplasmic prolongations into the vascular lumen (p) with some membrane ghosts (m). The epithelial cells show irregular foot processes (f), and cytoplasmic vacuoles. Uranyl acetate–lead citrate stains magnification × 6,800.

severe diarrhea, and results of laboratory studies again were consistent with malabsorption syndrome. Renal excretory function was normal as was the blood pressure, although heavy proteinuria persisted.

Renal findings. The renal changes included a slight membranous change, slight arterial and arteriolar sclerosis and focal tubular atrophy (*Fig. 2A*). Immunofluorescent studies showed some focal granular glomerular deposition of γ-globulin. The overall light microscopic changes were minimal.

Ultrastructural studies disclosed fibrinoid deposits in the intima of interlobular arteries, no striking glomerular changes, and lipid granules in distal convoluted tubules (*Fig. 2B*).

Case 3. A 52-year-old woman had been first examined at the Cleveland Clinic in 1943, at which time her blood pressure was 122/78 mm Hg. In 1956 she again was examined because of recurrent arthralgias; her blood pressure was 150/82 mm Hg. In 1963, the blood pressure was 150/100 mm Hg; results of urinalysis were normal, and the possible diagnosis of scleroderma was made.

In July 1964, symptoms of Raynaud's phenomenon were noted, followed by the onset of multiple arthralgias, fatigue, and frequent headaches. The blood pressure was 196/120 mm Hg, and the optic fundi revealed arteriolar spasm, hemorrhages, and exudates. A skin biopsy showed sclerodermatous changes; the blood urea nitrogen was 17 mg per 100 ml; serum creatinine was 1.4 mg per 100 ml; and urinary protein excretion was normal. The blood pressure was adequately controlled with antipressor medication. A selective renal angiogram showed areas of patchy nonopacification. The patient was given collagenase intravenously, and symptomatic improvement ensued.

In August 1966, blood pressures ranged from 140/96 to 160/110 mm Hg. The blood urea nitrogen was 23 mg per 100 ml, serum creatinine 1.3 mg per 100 ml, and urine protein excretion approximated 1.1 g per 24 hr. Renal biopsy was performed, and a selective renal angiogram showed tortuosity of the peripheral renal vascular pattern. The nephrogram was again abnormal, showing loss of functional renal parenchyma, and a decreased renal mass bilaterally.

In February 1967, the blood urea nitrogen was 25 mg per 100 ml, and the blood pressure was well controlled with oral diuretics. Results of pulmonary function studies were normal, but signs of cardiac decompensation were noted and administration of digitalis was begun. From this time, symptoms of cardiac decompensation progressed until the final admission to the hospital in November 1968. At that time the blood urea nitrogen was 28 mg per 100 ml, the serum creatinine 1.8 mg per 100 ml, and the creatinine clearance was 25 ml per minute. Despite severe congestive heart failure, urine protein excretion approximated only 160 mg per 24 hr. The patient died from refractory congestive heart failure on November 17, 1968.

Renal findings. Renal changes included mild and focal membrano-proliferative changes in glomeruli with focal arteriosclerosis (*Fig. 3A*). On immunofluorescence no deposition of γ-globulin, fibrinogen, or complement was seen in vessels or glomeruli. Ultrastructural studies revealed severe glomerular changes consisting of thickened glomerular basement membranes and widening of epithelial foot processes (*Fig. 3B*). Vascular alterations, consistent with scleroderma, included fibrinoid deposits in the intima of the distal portions of interlobular arteries above the internal elastic membrane; there was no hyperplasia of mesangial cells.

Case 4. A 54-year-old woman was first examined at the Cleveland Clinic in May 1967. Five months previously she noted the onset and progression of tightness and hardening of the skin over the dorsum of the hands and ulnar aspects of both forearms. Her history included porphyrinuria.

Initial evaluation revealed a blood pressure of 120/78 mm Hg. The skin appeared diffusely tanned. In addition to the tightness of the skin, there was a slight purplish hue to the skin of the fingers and dorsum of the hands. There were no skin ulcerations. Serum creatinine was 0.9 mg per 100 ml, and results of urinalysis were normal. The urinary excretion of coproporphyrins and uroporphyrins was increased. A skin biopsy was consistent with sclerodermatous changes. A renal biopsy was performed at this time.

By April 1968, the cutaneous sclerodermatous changes had worsened, with increased tightness and stiffness about the shoulders, elbows, wrists, and knees. Darkening of the skin had increased, and the hands now could not be closed completely because of the tightness of the skin. There had been progressive weakness and the onset of dysphagia. Blood pressure was 120/80 mm Hg; blood urea nitrogen was 13 mg per 100 ml; serum creatinine was 0.8 mg per 100 ml; and quantitative urine protein excretion was within normal limits.

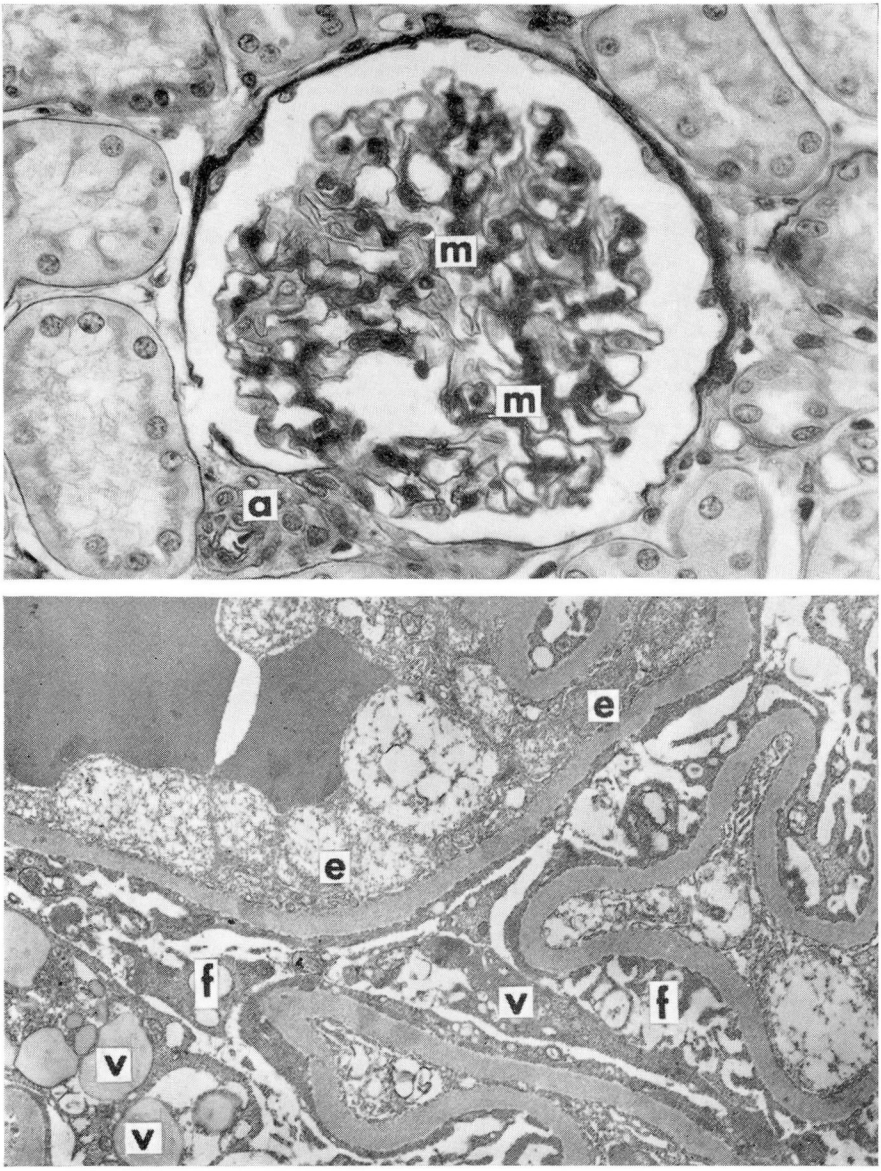

Fig. 2. Case 2. A, *upper,* Photomicrograph showing irregular and thickened glomerular basement membrane (m) with prominent juxtaglomerular apparatus surrounding cross section of afferent arteriole (a). PAS-Alcian blue stains; magnification × 680. B, *lower,* Electron micrograph showing a fairly regular basement membrane underlying swollen endothelial cells (e), and poorly preserved epithelial components with irregular and vacuolated foot processes (f). Electron-dense cytoplasmic vacuoles (v) are common, but other cytoplasmic organelles such as mitochondria are rare. Uranyl acetate–lead citrate stains; magnification × 5,400.

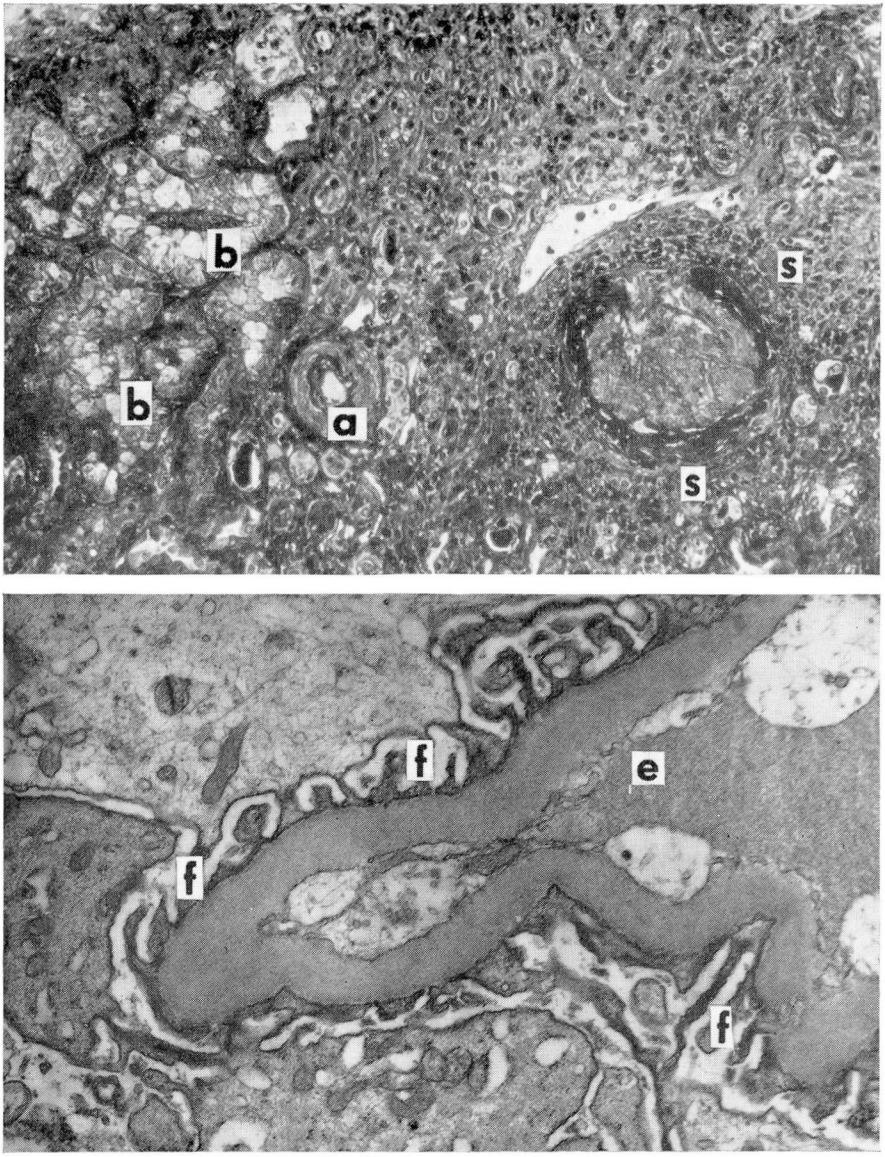

Fig. 3. Case 3. A, *upper,* Photomicrograph showing extensive proliferative cortical lesion. Note thickening of arteriolar medial layer (a), diffuse swelling of epithelial cells of tubules (b), and loss of glomerular urinary space with periglomerular scarring (s). Toludine blue stain-Epon-embedded section; magnification × 272. B, *lower,* Electron micrograph of patchy glomerular basement membrane showing irregular and often vacuolated foot processes (f) on epithelial cells and swollen endothelial elements (e). Uranyl acetate–lead citrate stains; magnification × 10,900.

Renal findings. Light microscopy (*Fig. 4A*) only showed localized glomerular changes. Immunofluorescent studies showed no deposition of γ-globulin or complement in vessels or glomeruli. The local nature of the lesions was further confirmed by ultrastructural studies. In some glomeruli, localized thickening of basement membrane (*Fig. 4B and C*) was accompanied by hyperplasia of mesangial cells and of the juxtaglomerular apparatus. Occasional subendothelial deposits of fibrinoid were present in longitudinal sections of some interlobular arterioles.

Case 5. A 49-year-old man was first examined at the Cleveland Clinic in February 1956. His general health appeared to be good at that time, the only pertinent symptom being nocturia, once nightly, of many years' duration.

The patient was next examined in October 1964, because of typical angina pectoris and blood pressures that ranged from 208/114 to 188/110 mm Hg. An intravenous urogram and the roentgenogram of the chest were normal. Optic fundi revealed grade I hypertensive retinopathy; and a short, grade III systolic ejection murmur was noted in the aortic region. Urinalysis revealed a specific gravity of 1.020, 1+ proteinuria, and a rare red cell and an occasional white cell on examination of sediment.

In August 1966, the patient had aching discomfort in the lower thighs and calves, which was diagnosed as fibrositis. His blood pressure was 150/100 mm Hg.

In January 1967, he was admitted to the Cleveland Clinic Hospital because of a three-month history of loss of weight, dysphagia, and anorexia. The skin over the arms was somewhat tight, and hypopigmentation was noted over the abdominal wall. A history suggestive of Raynaud's phenomenon was obtained. Urinalysis showed 2+ protein, from 2 to 4 red cells and, from 15 to 20 white cells per highpower field. A quantitative urine protein excretion was 1.3 g per 24 hr. Serum creatinine was 5.9 mg per 100 ml, and the creatinine clearance was 16 ml per min. The blood urea nitrogen was 47 mg per 100 ml. A skin biopsy was compatible with scleroderma. Renal biopsy was performed on February 22, 1967.

Renal findings. The renal changes included severe arterial and arteriolar sclerosis (*Fig. 5A*), and tubular atrophy with interstitial fibrosis and slight thickening of glomerular basement membranes. Immunofluorescent studies showed slight focal deposition of γ-globulin in the glomeruli. Ultrastructural studies showed severe changes in interlobular afferent arterioles with subintimal deposition of fibrinoid material, thickening of endothelial basement membranes and a striking reduction of vascular lumen (*Fig. 5B*). Considerable hyperplasia of smooth muscle cells and media was noted, but no perivascular inflammatory process. Glomerular changes also were prominent and consisted of hyperplasia of mesangial cells and thickening and reduplication of basement membranes of glomerular tufts, with irregular widening and vacuolization of foot processes. Three glomeruli showed severe hyperplasia of juxtaglomerular apparatus with abundant granules in juxtaglomerular cells, many of which contained myofilaments.

Discussion

The term progressive systemic sclerosis (PSS) has replaced the former term scleroderma, since the dermal sclerosis represents only the cutaneous manifestation of a multisystem syndrome. The reported incidence of renal changes in PSS varies according to the criteria used to denote its presence. The late onset of severe to malignant hypertension with progressive renal failure occurs rarely in the course of the disease. In a clinical study of 727 cases of PSS, Tuffanelli and Winkelmann[6] reported that 109 patients had proteinuria, yet only 19 had heavy proteinuria and azotemia. Renal failure was considered to be the cause of death of only 15 of the 727 patients. Conversely, in a clincopathologic review of 31 cases, Piper and Helwig[7] found renal changes in 21 patients, in seven of whom death was associated with renal failure and/or hypertension.

The gross appearance of the kidney often shows the degree of vascular involvement in this disease. Although the kidneys often are large, some show a slight or moderate reduction in size, and depressed irregular scars on the sur-

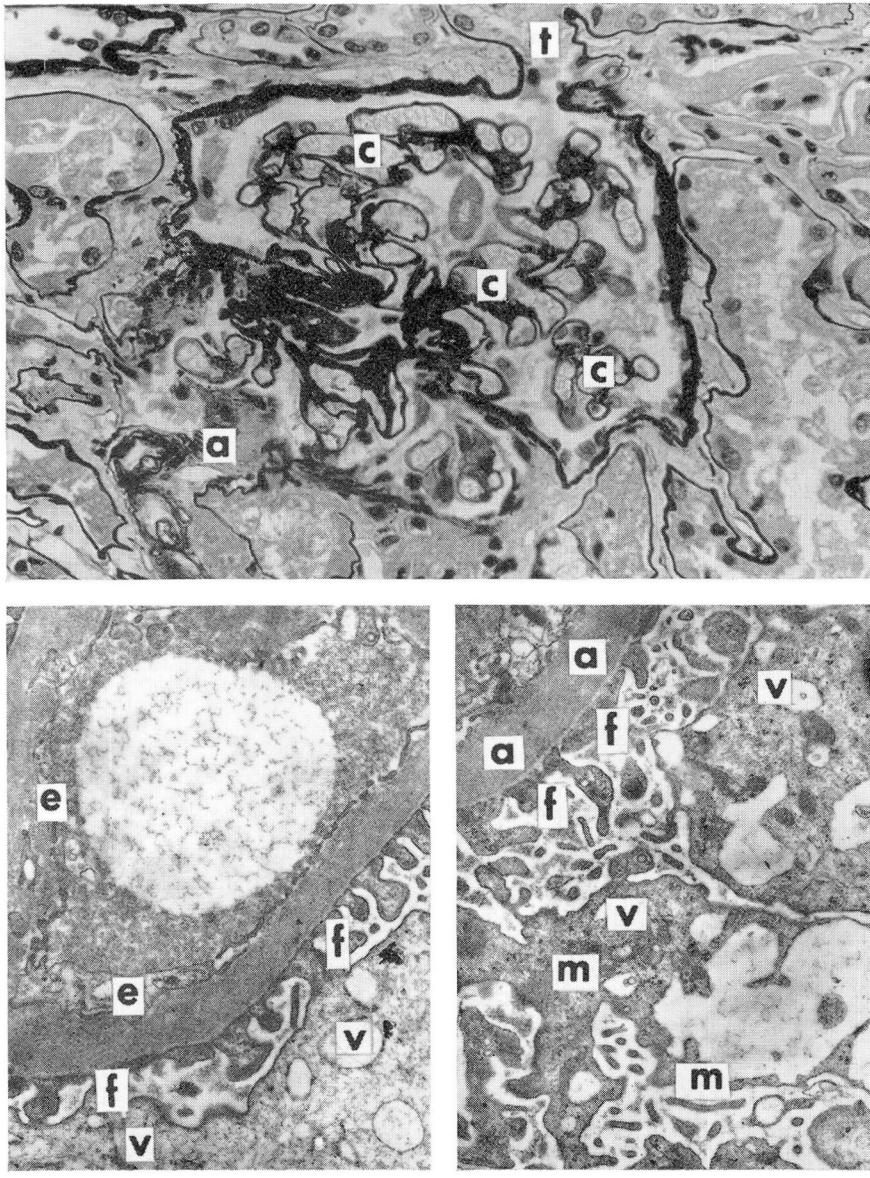

Fig. 4. Case 4. A, *upper,* Photomicrograph showing irregular and dilated capillary loops of glomerular tuft containing blood cells (c), reduplication of elastic fibers in afferent arteriole (a), and poorly preserved epithelial cells in a proximal tubule (t). Silver nitrate stain–Epon-embedded section; magnification × 680. B, *lower left,* Electron micrograph showing glomerular basement membrane with thin endothelial lining (e), regular distribution of foot processes (f), and vacuolated cytoplasm of epithelial cell (v). Uranyl acetate–lead citrate stains; magnification × 9,600. C, *lower right,* Electron micrograph, in contrast to (B), showing focal irregularities of foot processes (f), with scattered epithelial cell organelles (m), and vacuoles (v), of various densities. Some areas of basement membrane (a), are more electron dense than are surrounding structures. Uranyl acetate–lead citrate stains; magnification ×9,600.

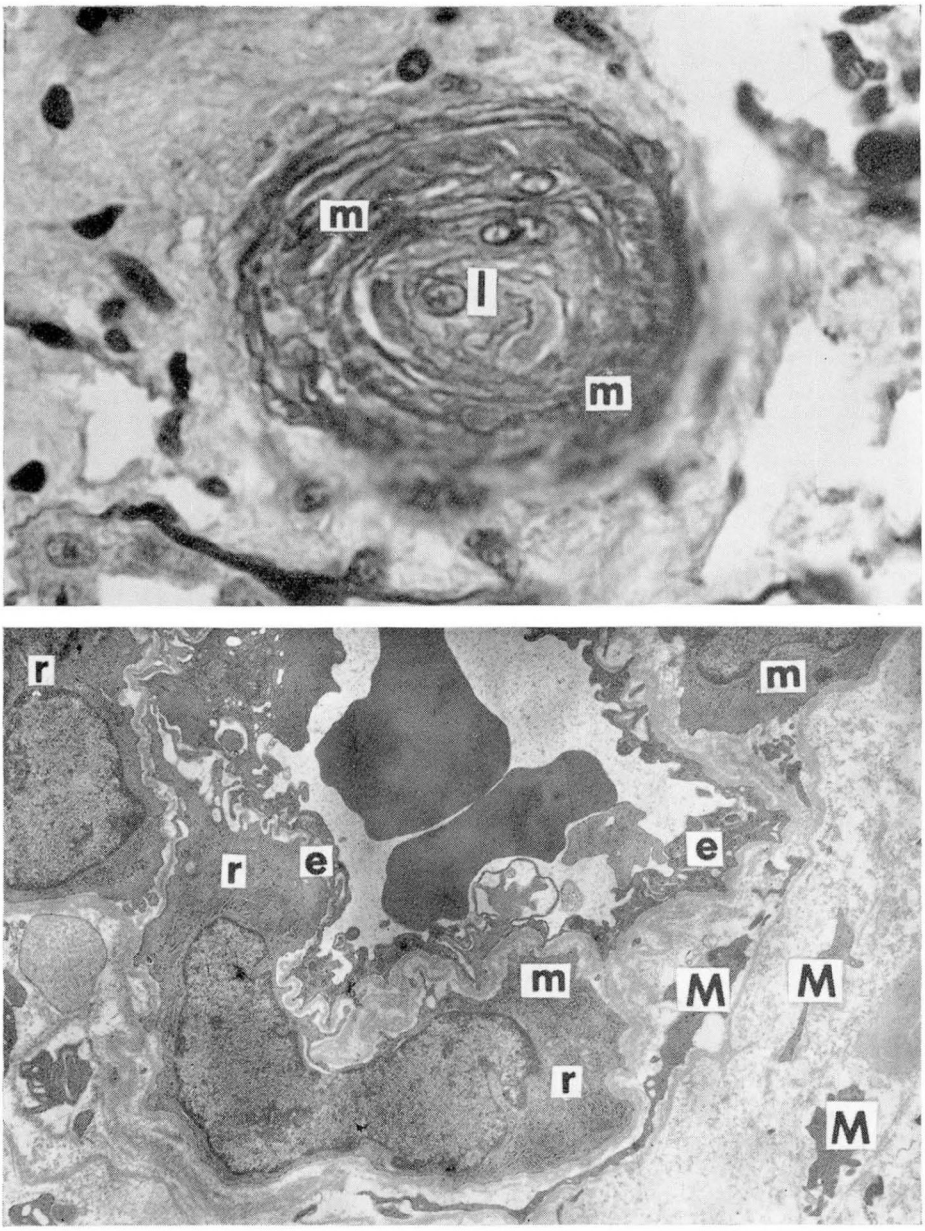

Fig. 5. Case 5. A, *upper,* Photomicrograph showing characteristic arteriolar changes consisting of hyperplasia of medial smooth muscle cells (m), and reduplication of elastic elements resulting in severe stenosis of vascular lumen (l). PAS-Alcian blue stains; magnification × 1,392. B, *lower,* Electron micrograph showing ultrastructural arteriolar changes with vacuolization and increased cytoplasmic density of endothelial cells (e). Prominent binucleated subendothelial elements have conspicuous cisternae of rough endoplasmic reticulum (r), and abundant mitochondria (m), in a loose matrix containing few recognizable smooth muscle cells (M). Uranyl acetate–lead citrate stains; magnification × 4,200.

face are the result of preexisting infarctions. The subcapsular surface may show petechial hemorrhages and infarctions, usually smaller than those found in active arteriolar nephrosclerosis. The vascular lesions are quite characteristic, resulting from hyperplasia and deposition of mucoid material in the intima of intralobular arteries. These lesions may develop late and lead to ischemic infarction of that part of the cortex receiving its blood supply from the affected artery. Secondly, fibrinoid alteration of the distal portion of intralobular arteries and afferent arterioles occurs, although less commonly than the mucoid and proliferative intimal lesions seen in the intralobular arteries.

Immunohistochemical studies of the renal changes found in PSS and malignant hypertension have shown that many of these findings result from deposition of fibrinogen-like material in the vessels.[8] Pardo and associates[9] showed that electron microscopic studies revealed qualitatively comparable granular arteriolar deposits, corresponding to so-called hyalinosis disclosed by light microscopy. The ferritin-like material in these deposits is suggestive of hematogenous derivation. The authors believed that the absence of specific vascular alterations in PSS was evidence against the concept that renal changes in this disease are unique. The fibrinoid changes most commonly seen in the arterial and arteriolar wall usually occur in the intima immediately above the internal elastic membrane in a manner resembling a dissection, usually leaving blank spaces on hematoxylin and eosin stained sections. The fibrinoid material is usually periodic-acid Schiff positive. This deposition of fibrinoid-like material immediately above the internal elastic membrane is pathognomonic of PSS. The vascular changes most commonly seen in PSS are indistinguishable from those found in malignant nephrosclerosis: they usually are associated with necrotic cell debris, and the vessel lumen is often thrombosed. Acute inflammation usually is absent, and periarteritis is absent. The absence of periarteritis in PSS allows differential diagnosis of these fibrinoid changes from those seen in polyarteritis nodosa, in which periarterial inflammation usually is present. These severe arteriolar changes result in acute ischemic alteration of renal cortical tissue, with multiple cortical infarcts and, finally, necrosis or damage of convoluted tubules and clinical renal failure.

The glomerular lesions present in PSS have received only limited attention. They may be focal with localized or diffuse thickening of basement membranes, and sometimes there are wireloop lesions. In advanced stages, granular eosinophilic masses may develop in the lumen of glomerular capillaries, and capillary walls appear to be replaced by fibrinoid material. Proximal and distal tubules may show flattening, and there may be hyperchromasia of epithelial cells and hyaline deposition. It has been suggested that vascular alterations represent a primary manifestation of PSS and are in turn responsible for the development of hypertension and renal failure. It should be emphasized that, with the exception of the so-called subintimal fibrinoid alteration immediately above the internal elastic membrane, all other changes at glomerular, tubular and/or vascular levels are similar to those alterations found in malignant nephrosclerosis.

The mucoid material in the interlobular arteries in both diseases is an acid mucopolysaccharide, possibly hyaluronic acid.

The relation of renal involvement in PSS to terminal malignant hypertension occasionally associated with this disease is not clearly understood. Although severe hypertension may be associated with oliguric renal failure, renal lesions in PSS may occur in the absence of hypertension. The hypertension in terminal stages of PSS is the result of progressive ischemic renal vascular involvement akin to the vascular ischemia occurring in other peripheral vessels and manifested by Raynaud's phenomena. The hypertension then might be secondary to the visceral arterial and arteriolar lesions rather than being an important etiologic factor in the development of the characteristic renal vascular changes.

Immunofluorescent methods have demonstrated variable deposition of γ-globulin and/or complement both in the glomeruli and in the walls of small arteries.[8] The demonstration of various autoantibodies in patients with PSS is consistent with some loss of normal immunologic tolerance to nuclear and serum proteins.[10] Although the nature of the antibody in the immunoglobulin IgG deposits in the walls of small arteries and in the glomeruli is not known at the present time, it is entirely possible that these deposits represent immune complexes of nuclear proteins and antinuclear antibodies. In our experience, circulating antinuclear antibodies are present in about 50 percent of the patients with PSS.[11]

Our observations on renal biopsies of five patients with clinical diagnoses of PSS seem to emphasize the heterogeneity of renal involvement in this disease. Many glomeruli appear to be histologically normal, and only ultrastructural alterations of the basement membrane may be present. Vascular involvement also may be spotty and only affect occasional interlobular and afferent arterioles. Arteries of arcuate size or larger may be normal or show nonspecific intimal fibrous thickening compatible with the patient's age and arteriosclerotic changes elsewhere in the body. Because of the focalization of these changes it is possible that repeated needle biopsies may show a constellation of histologic and ultrastructural changes from severe to minimal in the same patient (cases 2 and 4). The localized nature of these microscopic changes also may help to provide an explanation of individual variations in symptoms, in degrees of renal impairment, and in protracted courses of PSS.

Summary

The characteristic vascular changes which comprise the "true scleroderma kidney" are well recognized while other pathologic changes affecting the glomeruli have received but limited interest. The present report reviews five cases of progressive systemic sclerosis demonstrating variable clinical courses and spectrum of anatomic changes.

The five cases presented emphasize the heterogeneity of renal involvement in PSS and the localized nature of microscopic changes may help explain the

individual variations in symptoms, degrees of renal impairment, and the protracted course of PSS in some patients.

References

1. Moore, H. C., and Sheehan, H. L.: The kidney of scleroderma. Lancet **1:** 68–70, 1952.
2. Calvert, R. J., and Owen, T. K.: True scleroderma kidney. Lancet **2:** 19–22, 1956.
3. Rodnan, G. P.; Schreiner, G. E., and Black, R. L.: Renal involvement in progressive systemic sclerosis (generalized scleroderma). Am. J. Med. **23:** 445–462, 1957.
4. Fred, H. L., and Rambo, O. N.: Acute renal failure due to scleroderma kidney disease. Arch. Intern. Med. **100:** 813–818, 1957.
5. Hannigan, C. A.; Hannigan, M. H., and Scott, E. L.: Scleroderma of the kidneys. Am. J. Med. **20:** 793–797, 1956.
6. Tuffanelli, D. L., and Winkelmann, R. K.: Systemic scleroderma. A clinical study of 727 cases. Arch. Dermatol. **84:** 359–371, 1961.
7. Piper, W. N., and Helwig, E. B.: Progressive systemic sclerosis. Arch. Dermatol. **72:** 535–546, 1955.
8. Fennell, R. H.; Reddy, C. R., and Vazquez, J. J.: Progressive systemic sclerosis and malignant hypertension. Immunohistochemical study of renal lesions. Arch. Pathol. **72:** 209–215, 1961.
9. Pardo, V.; Fisher, E. R.; Perez-Stable, E., and Rodnan, G. P.: Ultrastructural studies in hypertension. II. Renal vascular changes in progressive systemic sclerosis. Lab. Invest. **15:** 1434–1441, 1966.
10. McGiven, A. R.; de Boer, W. G.; Barnett, A. J., and Coventry, D. A.: Autoantibodies in scleroderma. Med. J. Aust. **2:** 533–536, 1968.
11. Garewal, G. S., and Deodhar, S. D.: Antinuclear factor (ANF) test—its diagnostic value. Cleve. Clin. Q. **36:** 53–58, 1969.