

## THE CLINICAL PICTURE

**JOSÉ LUIS VALLEJO-GARCÍA, MD**

Department of Ophthalmology, Hospital Universitario La Paz, Madrid, Spain

**SERGIO VAÑÓ-GALVÁN, MD**

Department of Dermatology, Ramón y Cajal Hospital, University of Alcalá, Madrid, Spain

**OMAR RAYWARD, MD**

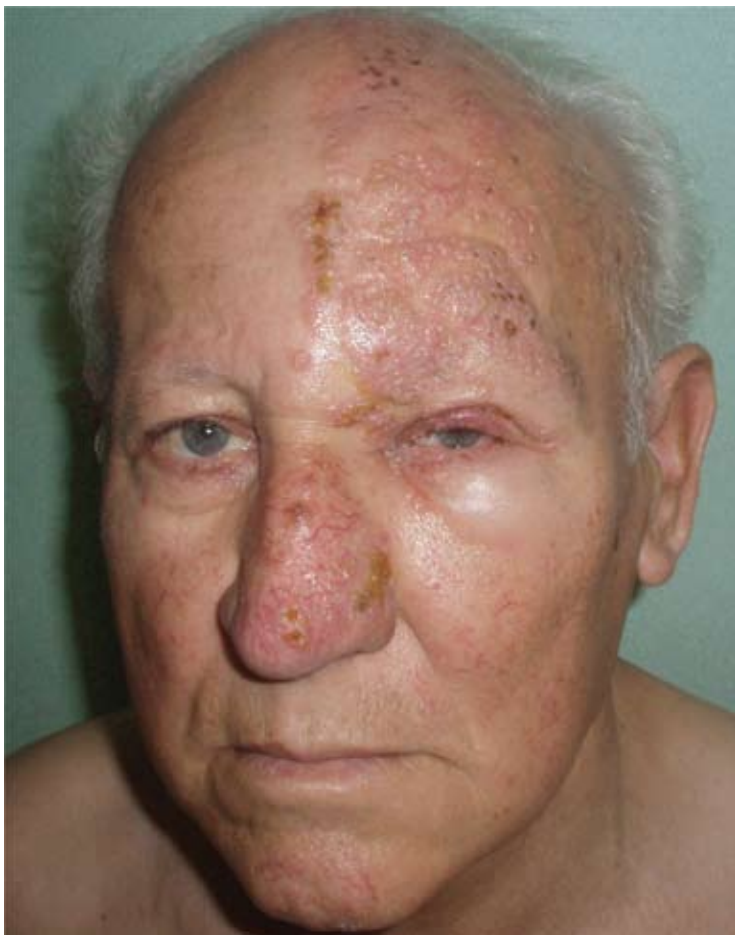Department of Ophthalmology, Hospital Universitario Clínico San Carlos, Madrid, Spain

**PAULA MORENO-MARTIN, MD**

Department of Ophthalmology, La Princesa University Hospital, Madrid, Spain

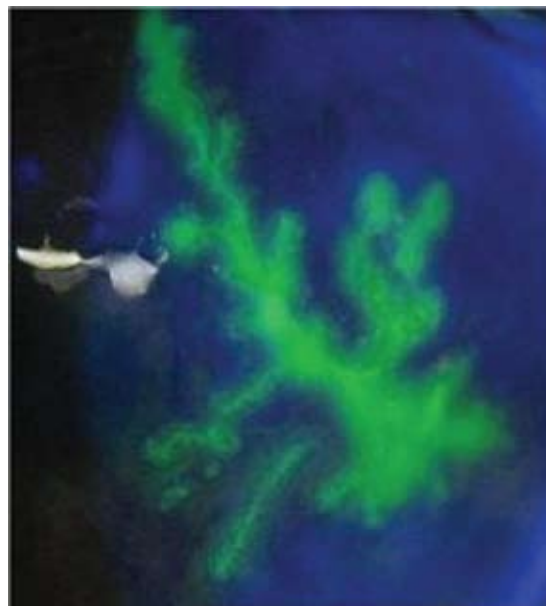
# The Clinical Picture

## Painful eye with a facial rash



**FIGURE 1.** Typical vesicular rash affects the first trigeminal branch dermatome without trespassing the midline.

**A** 75-YEAR-OLD MAN PRESENTS 4 days after a painful cutaneous lesions appeared on the left side of his face, associated with severe ocular pain. Two days before the eruption, he had had an intense headache, which was diagnosed as a tension headache and was treated



**FIGURE 2.** Typical corneal fluorescein stain of dendritic keratitis under cobalt blue light.

with oral acetaminophen (Tylenol), but with no improvement.

He has a history of hypertension and hyperuricemia. No recent changes have been made in his medications. Physical examination shows grouped herpetiform vesicles on an erythematous base confined to the cutaneous surface and innervated by the left first trigeminal branch (FIGURE 1). Palpation detects regional preauricular and submaxillary lymphadenopathies.

Ophthalmologic examination with fluorescein stain shows moderate perilimbal injection and dendritic keratitis (FIGURE 2).

The remainder of his physical examination is normal. Laboratory tests, including red and

doi:10.3949/ccjm.76a.08083

white blood cell counts, hemoglobin, and basic metabolic and coagulation tests reveal no abnormalities.

**Q:** What is your diagnosis?

- Allergic contact dermatitis
- Herpes simplex
- Varicella
- Ramsay-Hunt syndrome
- Herpes zoster ophthalmicus and herpetic keratitis

**A:** Herpes zoster ophthalmicus is the correct diagnosis. It represents a reactivation of the varicella zoster virus.<sup>1</sup>

Varicella zoster virus, like others of the herpes family, has developed a complex control of virus-host interactions to ensure its survival in humans. It lies dormant in the sensory ganglia and, when reactivated, moves down the neurons and satellite cells along the sensory axons to the skin.<sup>1</sup> The reactivation is related to diminished cell-mediated immunity, which occurs as a physiologic part of aging, which is why the elderly tend to be the most often affected.<sup>2</sup> The incidence of herpes zoster varies from 2.2 to 3.4 per 1,000 people per year.<sup>3</sup> Its incidence in people over age 80 is about 10 per 1,000 people per year.<sup>3</sup>

**■ CLINICAL PRESENTATION**

Herpes zoster typically presents as a dermatome-grouped vesicular eruption over an erythematous base, accompanied or preceded by local pain. It has two main complications, postherpetic neuralgia and ocular involvement. Postherpetic neuralgia is neuropathic pain that persists or develops after the dermatomal rash has healed.<sup>4</sup> Independent predictors of postherpetic neuralgia are older age, severe acute pain, severe rash, a shorter duration of rash before consultation, and ocular involvement.<sup>5</sup> It occurs in 36.6% of patients over age 60, and in 47.5% over 70.<sup>6</sup> Persistent postherpetic neuralgia has been linked to suicide in patients over 70.<sup>7</sup>

Ocular infection occurs with involvement of the ophthalmic division of the fifth cranial nerve. Before the antiviral era, it was seen in as many as 50% of patients.<sup>8</sup> Hutchinson's sign is skin lesions on the tip, side, or root of the

nose and is an important predictor of ocular involvement.<sup>1</sup> Lesions may include folliculopapillar conjunctivitis, episcleritis, scleritis, keratitis (dendritic, pseudodendritic, and interstitial), uveitis, and necrotizing retinitis.

**■ DIAGNOSIS**

The diagnosis of herpes zoster is usually based on clinical observation of the characteristic rash, although viral culture and molecular techniques are available when definitive diagnosis is required. When ophthalmic division is affected and Hutchinson's sign, unexplained ocular redness with pain, or complaints of visual problems are present, the patient should be referred promptly to an ophthalmologist, because serious visual impairment can occur. The fluorescein dye may show no staining or the typical dendritic keratitis (**FIGURE 2**).

**■ TREATMENT**

Oral antiviral drugs have made the treatment of zoster possible when, effectively, no treatment existed before. Ideally, an antiviral should be given within 72 hours of symptom onset. Starting treatment as early as possible—especially within 72 hours of onset—has been shown to be effective in alleviating acute pain and in preventing or limiting the duration and severity of postherpetic neuralgia.<sup>3</sup>

Acyclovir (Zovirax) 800 mg five times a day for 7 days or one of its derivatives—eg, famciclovir (Famvir), penciclovir (Denavir), or valacyclovir (Valtrex)—has been shown to be safe and effective in the treatment of active disease, as well as in preventing or shortening the duration of postherpetic neuralgia.<sup>3</sup> It has also been shown to reduce the rate of eye involvement from 50% to 20% or 30%.<sup>9</sup> This is why all patients with this dermatomal involvement must be treated.

**Second-generation antivirals**

Valacyclovir 1,000 mg three times a day and famciclovir 500 mg three times a day seem to be as effective as acyclovir in reducing zoster-associated pain, but their efficacy in reducing eye involvement has not been studied. In clinical practice, however, these second-generation antivirals may be more effective than

**Oral antivirals have made treatment of zoster possible—effectively, none existed before**

## PAINFUL EYE

acyclovir because patients are more likely to comply with the treatment regimen of three rather than five daily doses.

### Other considerations

In patients with kidney failure, the non-nephrotoxic antiviral brivudine is preferred, but it is not available in the United States. Therefore, one must use acyclovir or one of the other drugs, carefully adjusting the dose according to the creatinine clearance and making sure the patient is well hydrated.

The efficacy of antiviral treatment that is started more than 72 hours after the onset of skin rash has never been confirmed.

Although the additional effectiveness of acyclovir eye ointment has never been established, topical acyclovir can be considered in cases of dendritic or pseudodendritic keratitis.

### REFERENCES

1. **Liesegang TJ.** Herpes zoster ophthalmicus: natural history, risk factors, clinical presentation, and morbidity. *Ophthalmology* 2008; 115(suppl 2):S3–S12.
2. **Opstelten W, Eekhof J, Neven AK, Verheij T.** Treatment of herpes zoster. *Can Fam Physician* 2008; 54:373–377.
3. **Opstelten W, Zaal MJ.** Managing ophthalmic herpes zoster in primary care. *BMJ* 2005; 331:147–151.
4. **Donahue JG, Choo PW, Manson JE, Platt R.** The incidence of herpes zoster. *Arch Intern Med* 1995; 155:1605–1609.
5. **Opstelten W, Zuihoff NP, van Essen GA, et al.** Predicting postherpetic neuralgia in elderly primary care patients with herpes zoster: prospective prognostic study. *Pain* 2007; 132(suppl 1):S52–S59.
6. **De Morgas JM, Kierland RR.** The outcome of patients with herpes zoster. *AMA Arch Derm* 1957; 75:193–196.
7. **Hess TM, Lutz LJ, Nauss LA, Lamer TJ.** Treatment of acute herpetic neuralgia. A case report and review of the literature. *Minn Med* 1990; 73:37–40.
8. **Harding SP, Lipton JR, Wells JC.** Natural history of herpes zoster ophthalmicus: predictors of postherpetic neuralgia and ocular involvement. *Br J Ophthalmol* 1987; 71:353–358.
9. **Cobo LM, Foulks GN, Liesegang T, et al.** Oral acyclovir in the treatment of acute herpes zoster ophthalmicus. *Ophthalmology* 1986; 93:763–770.

**ADDRESS:** José Luis Vallejo-García, MD, Paseo de la Castellana Nº 261, 28046 Madrid, Spain; e-mail [jvallejogarcia@gmail.com](mailto:jvallejogarcia@gmail.com).

Visit our web site at  
<http://www.ccmj.org>

Contact us by e-mail at  
[ccjm@ccf.org](mailto:ccjm@ccf.org)

 Cleveland Clinic

 Joslin Diabetes Center

# DIABETES and the HEART:

A Clinical Summit  
on Critically  
Challenging Patients

August 6 & 7, 2009

InterContinental Hotel &  
Bank of America Conference Center  
Cleveland, Ohio

This activity has been approved for  
AMA PRA Category 1 Credit™.

Register Online:

[www.ccfmc.org/DiabetesHeart09](http://www.ccfmc.org/DiabetesHeart09)

