

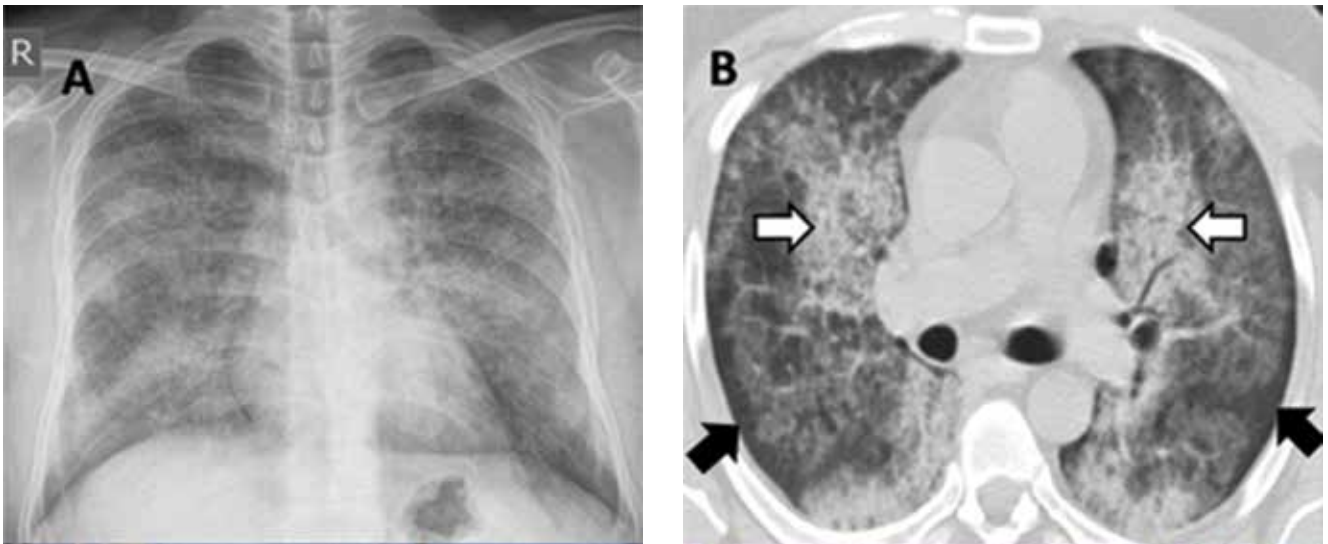
## THE CLINICAL PICTURE

**MOHAMMED H. ALSHATI, MD**

Division of Respiriology and Sleep Medicine,  
Department of Internal Medicine, Al-Adan  
Hospital, Ahmadi, Kuwait

# The Clinical Picture

## Alveolar proteinosis: A slow drowning in mud



**FIGURE 1.** Left, plain posteroanterior chest radiography showed diffuse bilateral alveolar and interstitial infiltrates without cardiomegaly, Kerley B lines, or pleural effusion. Right, axial computed tomography of the chest viewed in the lung window showed patchy ground-glass opacification with superimposed interseptal thickening (the "crazy-paving" pattern) (white arrows) admixed with diffuse bilateral airspace disease. Subpleural sparing was also evident (black arrows).

**A** 30-YEAR-OLD MAN presented with progressive dyspnea and dry cough, which had developed over the last 6 months. His oxygen saturation was 88% on room air, and he had diffuse bilateral crackles on auscultation. Imaging showed a mixture of diffuse airspace and interstitial abnormalities (FIGURE 1).

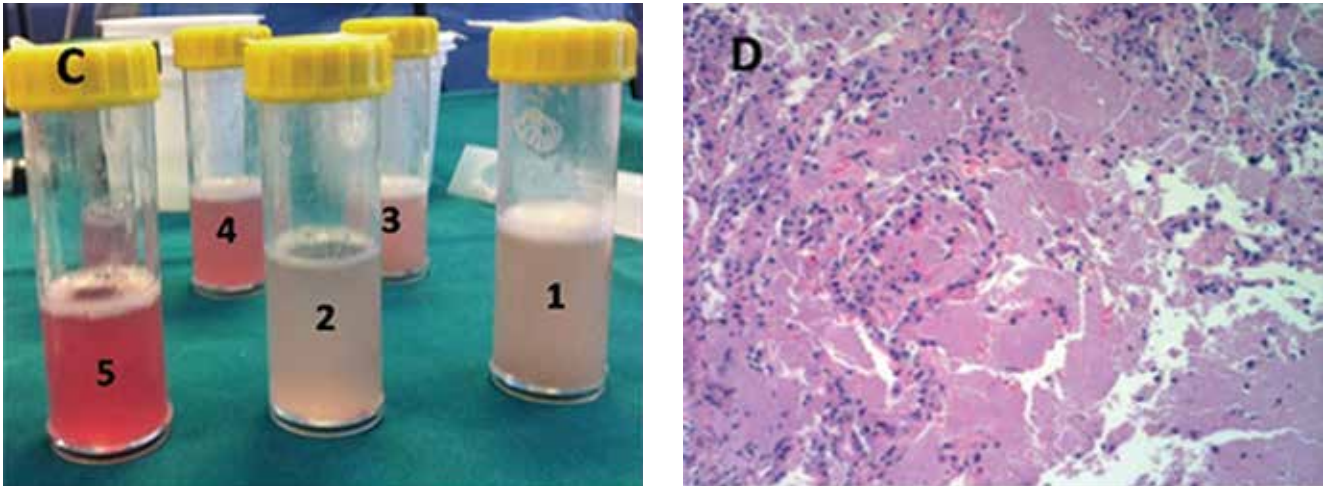
He underwent bronchoscopy. The bronchoalveolar lavage fluid had a turbid appearance that gradually cleared with successive aliquots. Transbronchial biopsy studies confirmed the diagnosis of pulmonary alveolar proteinosis (FIGURE 2). Sequential whole-lung lavage recovered significant amounts of thick,

proteinaceous effluent that slowly cleared. After the procedure, the patient's symptoms, oxygen saturation, and chest radiographic appearance (FIGURE 3) improved markedly, with no recurrence at 1 year of follow-up.

### ■ ALVEOLAR PROTEINOSIS

Pulmonary alveolar proteinosis is a rare disease characterized by the accumulation of lipoproteinaceous material in the alveolar space secondary to alveolar macrophage dysfunction. The condition can be congenital, secondary, or acquired. Patients typically present with progressive exertional dyspnea, nonproductive cough, variable restrictive ventilatory defects, and diffusion limitation on pulmonary function testing.

doi:10.3949/ccjm.81a.13085



**FIGURE 2.** Left, in serial bronchoalveolar lavage aliquots obtained by fiberoptic bronchoscopy, the fluid looked turbid initially but gradually cleared upon successive aliquots from the same subsegment. Right, transbronchial biopsy study showed alveolar filling with amorphous eosinophilic material, characteristic of alveolar proteinosis, and minimal cellular infiltration or collagen deposition in the interstitium (hematoxylin and eosin,  $\times 10$ ).

Plain chest radiographs usually resemble those seen in pulmonary edema but without features of heart failure, ie, cardiomegaly, Kerley B lines, and effusion.

A “crazy-paving” pattern on computed tomography—a combination of geographic ground-glass appearance and interseptal thickening—suggests alveolar proteinosis, but is not specific for it. Other differential diagnoses for the crazy-paving pattern include *Pneumocystis jirovecii* infection, invasive mucinous adenocarcinoma, cardiogenic pulmonary edema, alveolar hemorrhage, sarcoidosis, cryptogenic organizing pneumonia, exogenous lipid pneumonia, drug-induced lung disease, acute radiation pneumonitis, and nonspecific interstitial pneumonia.<sup>1</sup>

Laboratory testing is not very helpful in the diagnosis, although the serum lactate dehydrogenase level may be mildly elevated. Circulating antibodies to granulocyte macrophage colony-stimulating factor may support the diagnosis, but they are only present in the acquired form. Communication with a research laboratory is usually needed to test for these antibodies.

The bronchoalveolar lavage fluid typically has an opaque, milky, or muddy appearance. The diagnosis is confirmed by demonstration of alveolar filling with material that is periodic acid-Schiff-positive and that is amorphous, eosinophilic, and granular.

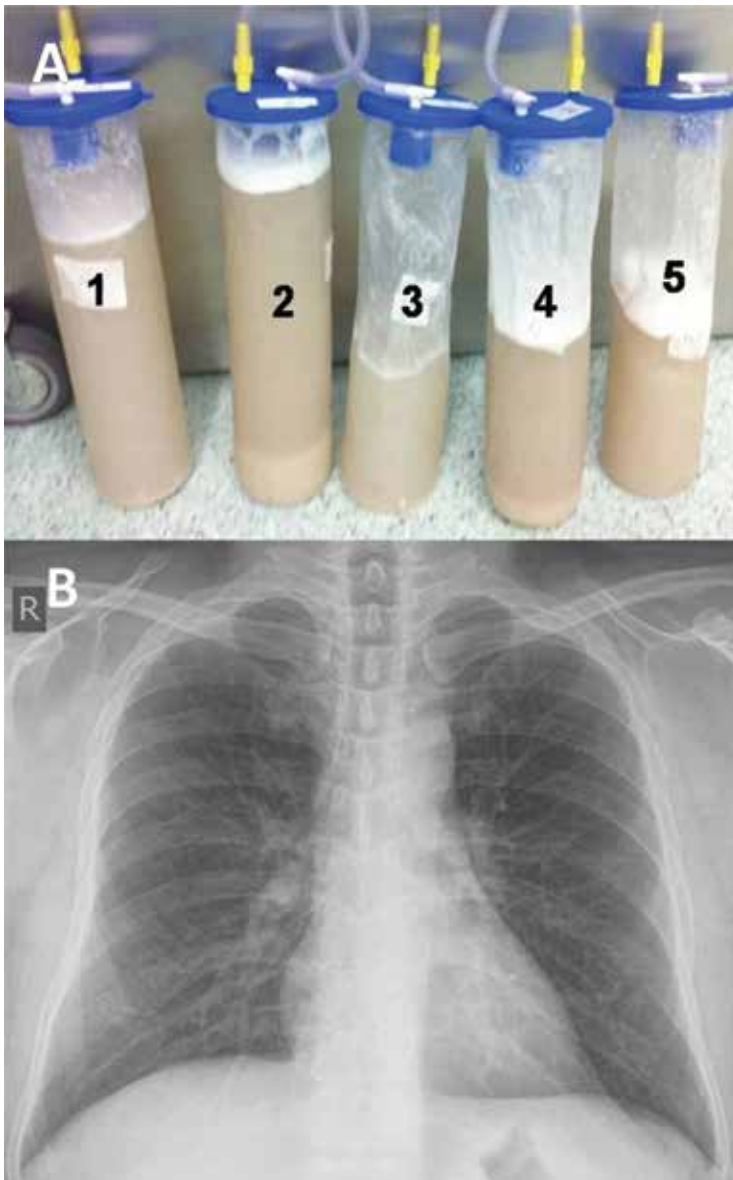
Whole-lung lavage<sup>2</sup> is the physical removal of surfactant by repeated flooding of the lungs with warmed saline, done under general anesthesia with single-lung ventilation. It remains the standard of care and is indicated in patients with the confirmed diagnosis and one of the following: severe dyspnea, resting hypoxemia ( $P_{aO_2} < 60$  mm Hg at sea level), alveolar-arterial gradient  $> 40$  mm Hg, or a shunt fraction of more than 10%. Successful bronchoscopic lavage has also been reported.<sup>3</sup>

Other treatments include granulocyte-macrophage colony-stimulating factor, rituximab (Rituxan, an anti-CD20 monoclonal antibody), plasmapheresis, and lung transplantation. Systemic corticosteroids are usually ineffective unless indicated for secondary types of alveolar proteinosis.

Inhalation rather than subcutaneous administration of granulocyte-macrophage colony-stimulating factor seems preferred as it ensures a high concentration in the target organ, avoids systemic complications (injection-site edema, erythema, neutropenia, malaise, and shortness of breath) and achieves lower levels of autoantibodies in bronchoalveolar lavage fluid, which correlates with disease activity.

Data are sparse as to the recurrence of autoimmune pulmonary alveolar proteinosis after whole-lung lavage, yet about 40% of patients require a repeat procedure within 18

**Plain chest radiography usually resembles that in pulmonary edema, but without features of heart failure**



**FIGURE 3.** Top, samples of the initial effluent obtained during whole-lung lavage showed thick, proteinaceous, mud-like fluid with sediment. Bottom, after whole-lung lavage, chest radiography showed remarkable improvement.

months. Recurrence has also been reported after double-lung transplantation.<sup>4</sup>

Adjuvant therapy with rituximab or, to a lesser extent, with inhaled granulocyte-macrophage colony-stimulating factor has recently been shown to diminish the need for repeated lavage.<sup>5</sup> These treatments can also be used when whole-lung lavage cannot be performed or proves to be ineffective.<sup>5</sup>

**ACKNOWLEDGMENT:** I would like to thank Dr. Kamelia Velikova for providing the pathology image.

### REFERENCES

1. Rossi SE, Erasmus JJ, Volpacchio M, Franquet T, Castiglioni T, McAdams HP. 'Crazy-paving' pattern at thin-section CT of the lungs: radiologic-pathologic overview. *Radiographics* 2003; 23:1509–1519.
2. Michaud G, Reddy C, Ernst A. Whole-lung lavage for pulmonary alveolar proteinosis. *Chest* 2009; 136:1678–1681.
3. Cheng SL, Chang HT, Lau HP, Lee LN, Yang PC. Pulmonary alveolar proteinosis: treatment by bronchofiberscopic lobar lavage. *Chest* 2002; 122:1480–1485.
4. Parker LA, Novotny DB. Recurrent alveolar proteinosis following double lung transplantation. *Chest* 1997; 111:1457–1458.
5. Leth S, Bendstrup E, Vestergaard H, Hilberg O. Autoimmune pulmonary alveolar proteinosis: treatment options in year 2013. *Respirology* 2013; 18:82–91.

### SUGGESTED READING

- Borie R, Danel C, Debray MP, et al. Pulmonary alveolar proteinosis. *Eur Respir Rev* 2011; 20:98–107.
- Carey B, Trapnell BC. The molecular basis of pulmonary alveolar proteinosis. *Clin Immunol* 2010; 135:223–235.
- Ioachimescu OC, Kavuru MS. Pulmonary alveolar proteinosis. *Chron Respir Dis* 2006; 3:149–159.
- Luisetti M, Kadija Z, Mariani F, Rodi G, Campo I, Trapnell BC. Therapy options in pulmonary alveolar proteinosis. *Ther Adv Respir Dis* 2010; 4:239–248.

**ADDRESS:** Mohammed H. AlShati, MD, FCCP, Division of Respiriology and Sleep Medicine, Department of Internal Medicine, Al-Adan Hospital, PO Box 46969, 64020 Ahmadi, Kuwait; e-mail: dr\_alshatti@hotmail.com