

Primary mediastinal myelolipoma

C. VAUGHN STRIMLAN, MD, AND S. KHASNABIS, MD

■ Myelolipomas are benign tumors composed of fat cells and mature bone marrow elements. They usually occur in the adrenal glands; fewer than 20 extra-adrenal myelolipomas have been reported. Myelolipomas may be found in abdominal, pelvic, or mediastinal sites. We report a patient with a right posterior mediastinal myelolipoma that was successfully resected.

□ INDEX TERMS: LIPOMA; MEDIASTINAL NEOPLASMS □ CLEVE CLIN J MED 1993; 60:69-71

P RIMARY MEDIASTINAL myelolipoma is extremely rare. The clinical signs and symptoms are nonspecific, and definitive tissue diagnosis is difficult to make prior to surgical resection. We report a patient with benign mediastinal myelolipoma.

CASE HISTORY

A 65-year-old white female was admitted for progressive shortness of breath. She had a history of chronic obstructive lung disease and chronic respiratory failure secondary to cigarette smoking. She had stopped smoking 1 year previously; she had smoked 40 packs per year. Her physical examination revealed expiratory wheezing but was otherwise unremarkable.

Chest radiography showed a right posterior mediastinal paraspinal mass lesion, which was confirmed by computed tomography (CT) of the chest (Figures 1 and 2). Intravenous contrast material was administered. The Hounsfield unit value of the mass was 36. There was no evidence of bone destruction. A small left lingular nonspecific fibrotic scar was noted.

The hemoglobin was 16.0 g/L, the hematocrit was 47.7%, and the leukocyte count was 8,300 cells/ μ L. A bone marrow biopsy was normal. Erythroblasts and granulocytic maturation appeared normal. The prothrombin time, partial thromboplastin time, and platelet counts were normal. Cardiac and liver enzymes were normal. The general health screen was normal, with a fasting blood glucose of 103 mg/dL. Electrolytes, blood urea nitrogen, and creatinine were also normal.

Examination with flexible fiberoptic bronchoscopy was normal. No endobronchial lesions were seen. Cytology studies and complete cultures were negative.

The patient was referred for surgical consultation and underwent a right thoracotomy. The entire well-encapsulated mass lesion was excised without difficulty from the right seventh paravertebral area. The lesion was benign. Microscopic sections revealed mixed fat cell and mature bone marrow elements including megakaryocytes, normoblasts, and granulocytes (Figures 3 and 4).

The patient had an uncomplicated hospital course and was discharged on the eighth postoperative day.

DISCUSSION

Myelolipomas are benign neoplasms composed of adipose cells and mature bone marrow elements, in-

From the Departments of Medicine and Pathology, South Side Hospital, Pittsburgh.

Address reprint requests to C.V.S., Suite 306, 1050 Bower Hill Road, Pittsburgh, PA 15243.

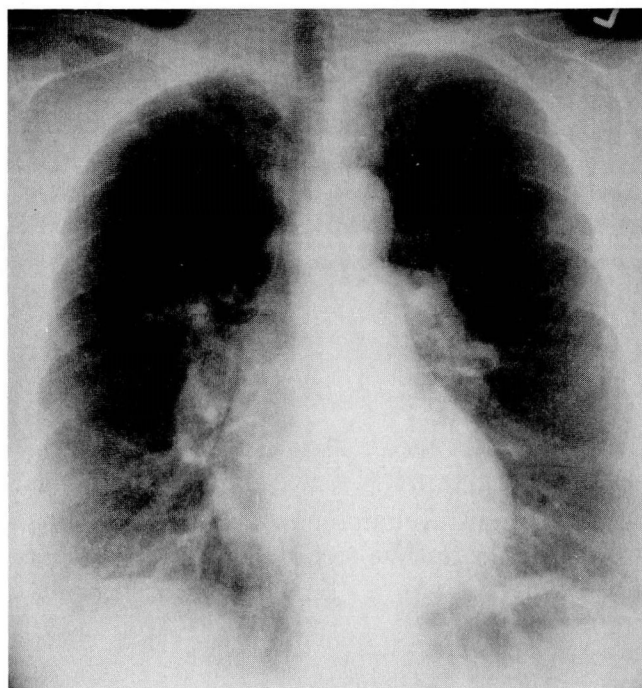


FIGURE 1. Posteroanterior chest radiograph demonstrating a right paraspinal mass lesion.

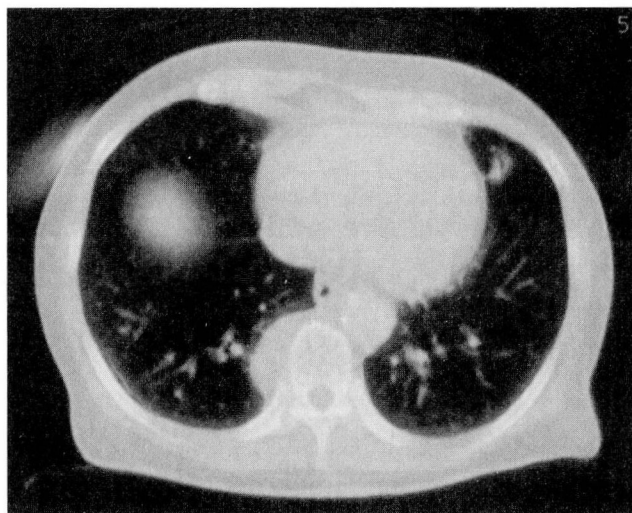


FIGURE 2. Computed tomographic mediastinal window image confirming the posterior mass lesion (Hounsfield unit value 36).

cluding megakaryocytic, granulocytic, and normoblastic lines. All of the reported myelolipomas are clinically and pathologically similar and have no relationship to bone marrow disorders.^{1,2}

Extra-adrenal myelolipomas are rare; fewer than 20 cases have been reported. Usually discovered radiographically or incidentally, they occur primarily in middle-aged or older women. They are predominantly solitary tumors and have been reported in abdominal, pelvic, and mediastinal locations.^{3,4}

Benign myelolipomas are distinct from extramedullary tumors of hematopoietic tissue. The latter are associated clinically with hematologic disorders characterized by marked bone marrow hyperplasia, anemia, hepatosplenomegaly, and abnormal peripheral blood smears. The tumors are usually multiple and occur in younger, predominantly male, patients. Extramedullary hematopoiesis results from abnormal proliferation of bone marrow elements.⁵⁻⁷

Only four other primary mediastinal myelolipomas have previously been reported in the English literature (Table). They were discovered radiographically or incidentally at autopsy. They occurred equally in men and women (ages 55 to 81). Pathologic features were identical in all cases.^{1,2,8,9}

The pathogenesis of extra-adrenal myelolipoma is unknown, although several theories—including proliferation of embryonic rests of hematopoietic tissues, differentiation of mesenchymal cells, and direct extension from bone marrow—have been proposed.^{4,5}

The differential diagnosis of a posterior mediastinal mass includes bronchogenic cyst, neurogenic cyst or tumor, aortic aneurysm, esophageal lesions, posterior thyroid tumor, and foramen of Bochdalek hernia. Myelolipoma should be considered in the differential diagnosis of benign tumors of the mediastinum. Lesions of this kind are benign, well encapsulated, and usually single. They are not associated with anemia or myeloproliferative disease. The diagnosis is confirmed by chest CT and tissue biopsy. Chest CT may distinguish these lesions from solid bronchogenic tumor masses.

TABLE
REPORTS OF PRIMARY MEDIASTINAL MYELOLIPOMA

Author	Sex	Age	Location	Size (cm)
Strimlan et al (1993)	F	65	Right posterior paravertebral	5
Kim et al (1984)	M	55	Left posterior mediastinal	7
Krag et al (1972)	F	71	Right anterior mediastinal	5
Foster (1958)	M	80	Right posterior paravertebral	4
Saleeby (1925)	F	81	Right and Left posterior paravertebral	2.5

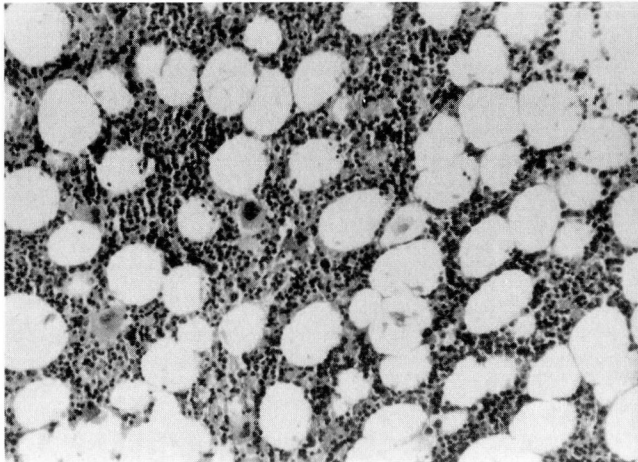


FIGURE 3. Periphery of tumor, demonstrating fat cells and bone marrow elements (hematoxylin-eosin, $\times 100$).

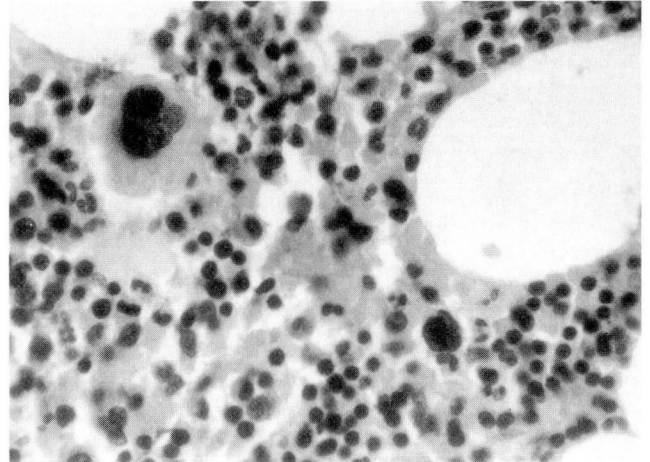


FIGURE 4. Interior of the tumor composed of fat cells and mature stages of erythroid series (hematoxylin-eosin, $\times 400$).

REFERENCES

1. Kim K, Koo BC, Davis JT, Franco-Saenz R. Primary myelolipoma of mediastinum. *J Comput Tomogr* 1984; **8**:119-123.
2. Krag D, Reich SB. Heterotopic bone marrow (myelolipoma) of the mediastinum. *Chest* 1972; **61**:514-515.
3. Grignon DJ, Shkrum MJ, Smout MS. Extra-adrenal myelolipoma. *Arch Pathol Lab Med* 1989; **113**:52-54.
4. Massey GS, Green JB, Marsh WL. Presacral myelolipoma. *Cancer* 1987; **60**:403-406.
5. Fowler MR, Williams RB, Alba JM, Byrd CR. Extra-adrenal myelolipomas compared with extramedullary hematopoietic tumors. *Am J Surg Pathol* 1982; **6**:363-374.
6. Verani R, Olson J, Moake JL. Intrathoracic extramedullary hematopoiesis: report of a case in a patient with sickle-cell disease-beta-thalassemia. *Am J Clin Pathol* 1980; **73**:133-137.
7. Glew RH, Haese WH, McIntyre PA. Myeloid metaplasia with myelofibrosis: the clinical spectrum of extramedullary hematopoiesis and tumor formation. *Johns Hopkins Med J* 1973; **132**:253-270.
8. Foster JBT. Primary thoracic myelolipoma. *Arch Pathol* 1958; **65**:295-297.
9. Saleeby ER. Heterotopia of bone marrow without apparent cause. *Am J Pathol* 1925; **1**:69-76.