

HYPERTROPHIC PYLORIC STENOSIS IN THE ADULT

Discussion of Etiology and Report of a Case

WILLIAM K. RUNYEON, M.D., STANLEY O. HOERR, M.D.

Department of General Surgery

and

JOHN B. HAZARD, M.D.

Department of Pathology

AN ADULT FORM of hypertrophic pyloric stenosis has been recognized since 1835, when Jean Cruveilhier¹ first reported the case of a 72-year-old woman who presented a lifelong history of dyspepsia and vomiting. Although this disease has received far less attention than its more common pediatric counterpart, reports of cases have continued to appear sporadically since that time. Few authors have failed to express themselves on the fundamental issue of whether the disease entity is congenital or acquired. This report has been prepared not only in order to add one more case to the literature, but also in the hope that a summation of available data may provide sufficient information reasonably to resolve this central problem of etiology.

Historical Review

In 1885, Maier² described 35 cases discovered at autopsy. Judd and Thompson³ in 1933 reported 20 cases confirmed at laparotomy during a ten-year period. In 11 of these the diagnosis was confirmed histologically. In the same year, Kirklin and Harris⁴ reported 81 cases in which they believed that a roentgenographic diagnosis of the disease entity had been established; in 31 of their patients there was no other gastrointestinal abnormality. However, their contention that the roentgenographic finding of a crescentic indentation of the duodenal bulb with prepyloric narrowing was pathognomonic was not supported by the findings of Bockus⁵ and other observers, and is not widely accepted today. Other authors whose contributions were concerned with smaller series of five cases or less include McClure,⁶ Crohn,⁷ Katz,⁸ Wakefield,⁹ Berk and Dunlap,¹⁰ and Greenfield.¹¹

Clinical Picture

Incidence. From available data, it is clear that approximately 80 per cent of the patients are males (as in the infantile type), and that there is a very wide age distribution.

Symptom complex. No consistent symptomatic pattern of the disease emerges from the literature. The lack of histopathologic criteria contributes to the confusion, for some reported cases are inadequately described and others may well represent changes secondary to gastric or duodenal ulcerations. Judd and Thompson³ report an average duration of symptoms of ten years, and clinical histories characterized by repeated bouts of vomiting and epigastric discomfort are not uncommon. However, confirmed cases with presenting complaints of less than one year's duration, usually simulating those of ulcer or of neoplasm, are also not exceptional. A high incidence of coexistent ulcer or gastritis is generally reported.

It is clear that the principal hypertrophy, as in the childhood variety, is limited to the circular (constrictor) muscle with little change in the longitudinal (dilator) fibers. Although Horwitz, Alvarez, and Ascanio¹² have found that in their series the thickness of the normal pyloric musculature varied from 3.8 to 8.5 mm. (5.8 ± 0.1 mm. average), criteria for the establishment of the diagnosis of adult hypertrophic pyloric stenosis remain more clinical than arithmetic. This is true both because there have been relatively few surgical specimens available for study, and also because, as Horton¹³ points out, the dimensions of the pyloric musculature vary widely with the age and with the weight of the patient and also with the state of contraction or relaxation of the muscle at the time of fixation for sectioning.

Discussion and Conclusions

It is not known whether the condition of adult hypertrophic pyloric stenosis is uniformly of congenital origin, as Crohn⁷ believes it to be, or whether it sometimes may be acquired. The possible etiologic role of pyloric spasm, perhaps secondary to other gastrointestinal disease, is supported by Berk,¹⁰ and McClure,⁶ but is questioned by Wakefield⁹ who cites the frequency of spasm and the rarity of true hypertrophy. Katz⁸ raises the interesting possibility that hypertrophy of the pylorus, may result from dilatation rather than constriction and, if acquired, might be secondary to some disturbance of the autonomic nervous system.

We believe it is justifiable tentatively to conclude that true hypertrophic pyloric stenosis in the adult is of congenital origin for the following reasons: 1. A history of gastric complaints dating from childhood is usual. 2. Pyloric spasm is common but hypertrophy is uncommon. 3. The sex incidence and the pathologic changes of hypertrophy of the circular muscle are similar in the infant and in the adult. It is probable that the disease can exist in subclinical form for many years before gastric distention or symptoms of gastritis or gastric ulcer result in clinical symptoms. Indeed, it is of interest to speculate whether

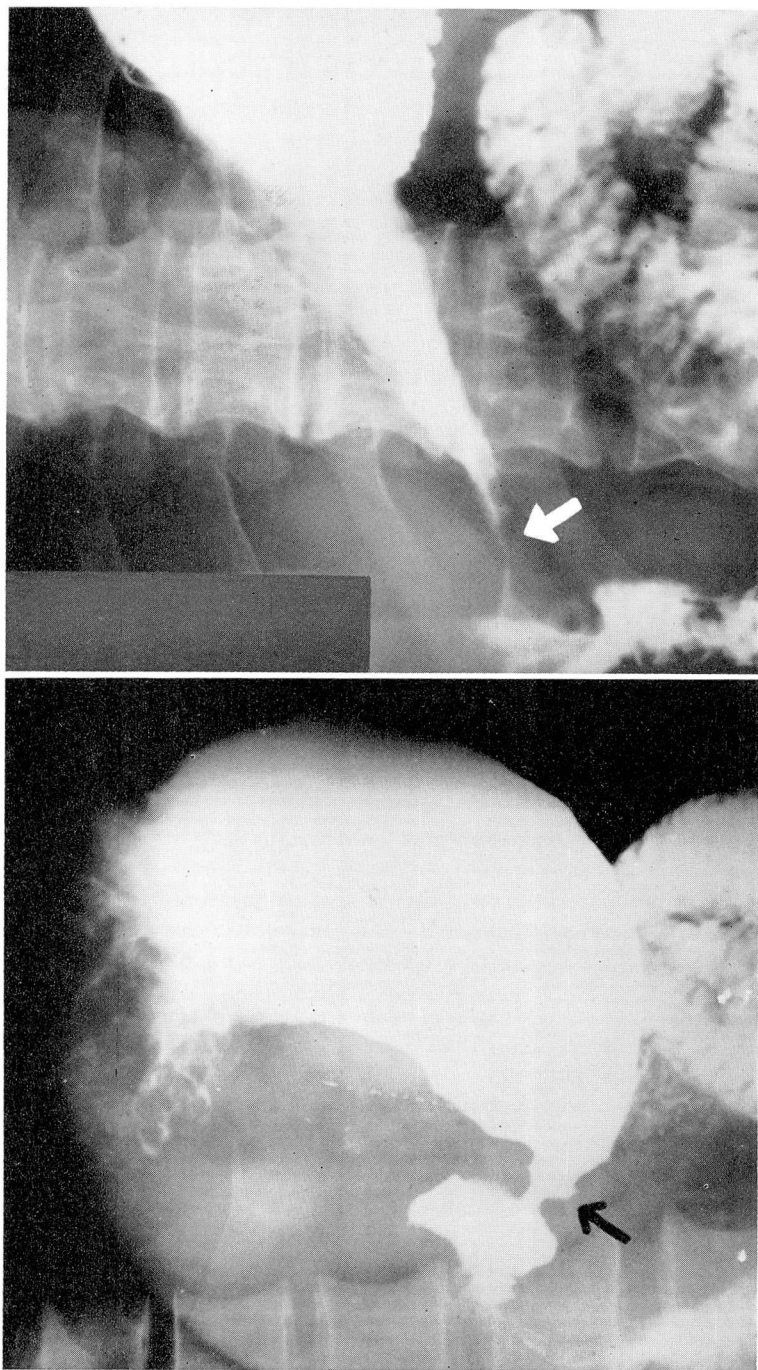


Fig. 1. (A) Preoperative roentgenogram of stomach, (B) showing prepyloric narrowing.

the presence of some degree of hypertrophy of the pyloric muscle in gastric (but not in duodenal) ulcer¹² may indicate that such hypertrophy plays a role in the pathogenesis of some gastric ulcers.

If the clinician becomes more aware of hypertrophic pyloric stenosis as a diagnostic possibility, the disease will be suspected preoperatively more often than is now the case. However, surgical exploration remains the chief means of diagnosis. At laparotomy, partial gastric resection, with its present low mortality rate, is usually the treatment of choice, for even at operation it is not possible to distinguish with certainty between hypertrophic pyloric stenosis and prepyloric malignant disease or ulcer.

Case Report

A 65-year-old white man was admitted in June 1953 with the chief complaint of six episodes of epigastric and right upper quadrant pain during the preceding year. The attacks characteristically began early in the morning, awakening him from sleep, and were associated with flatulence and vomiting; they usually lasted more than 24 hours. The most recent attack had occurred five weeks previously. He had experienced vague epigastric distress and bloating for many years, although otherwise his health had been good. There had been no loss of weight.

Physical and laboratory findings. Physical examination revealed a moderately obese elderly man (height 63½ inches, weight 151 pounds). The remainder of the examination was essentially within normal limits. The pertinent roentgenographic findings included nonfunction of the gallbladder following double-dose technic, diverticulosis of the lower descending and sigmoid colon, and an upper gastrointestinal examination that was reported as follows:

The esophagus and proximal three fourths of the stomach are normal.

There is narrowing and irregularity of the distal antrum with partial destruction of its mucosal pattern and a very small projection of barium on the greater curvature aspect probably representing an ulcer. Changes are highly suggestive of ulcerated carcinoma of the antrum. The duodenal bulb is normal. Impression: Probable ulcerated neoplasm, distal antrum. (Fig. 1A and B)

A gastric analysis revealed 12 units of free acid and 44 units of total acid after histamine stimulation. The blood hemoglobin was 14.9 Gm. per hundred ml., and a single stool examination showed no occult blood.

The preoperative diagnoses were: 1) cholelithiasis with biliary colic and 2) possible gastric malignancy. At operation on July 6, 1953, a cholecystectomy was performed for a thickened gallbladder containing four stones. An operative cholangiogram revealed a normal biliary ductal system. There was marked hypertrophy of the pyloric musculature with induration but no palpable ulcer crater. A clinical diagnosis of probable healed or healing gastric ulcer was made and a 60 per cent gastric resection with Billroth I gastroduodenostomy was performed.

Pathologic findings. The pathologic description of the resected segment of stomach was as follows:

Gross examination: (See Fig. 2) The segment of stomach measured 14.5 cm. on the greater curvature, 7.0 cm. on the lesser curvature; and 11.5 cm. in circumference at the proximal line of dissection and 5.0 cm. at the distal

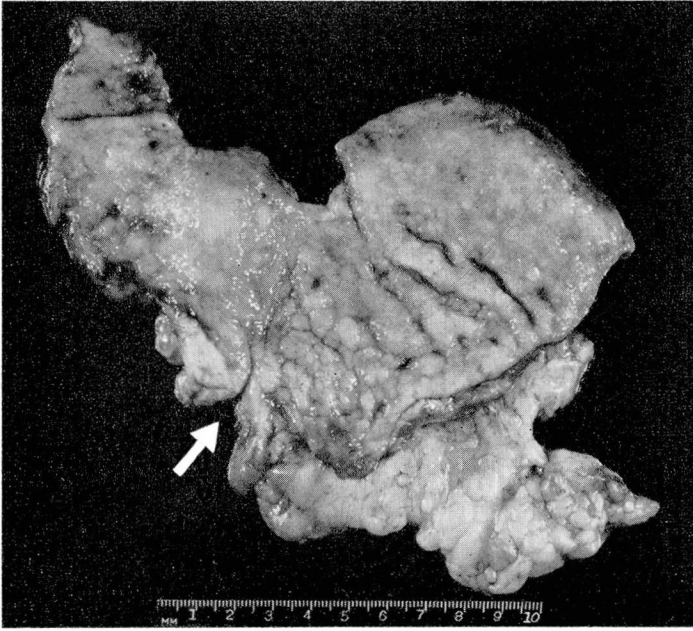


Fig. 2. The opened specimen showing marked thickening at the pyloric ring where the arrow points.

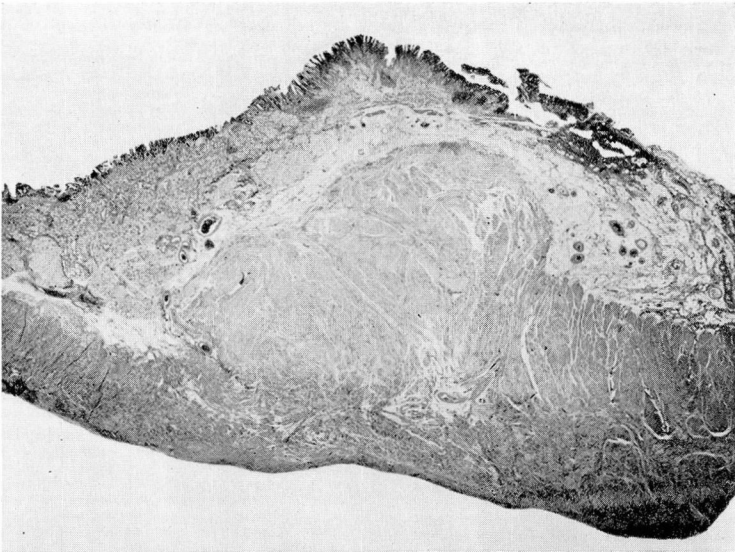


Fig. 3. Low-power photomicrograph showing muscular hypertrophy of the pylorus, principally the circular layer. X5.

HYPERTROPHIC PYLORIC STENOSIS

line. The serosal surface was normal. There was a firm, indefinitely outlined mass palpable on the anterior wall in the pyloric region. When opened, it was found to be a zone of thickening of the pylorus, 1.3 cm. in maximum thickness and 2.0 cm. in length. On section, the tissue was pinkish gray, glistening, and had a bulging cut surface. Posteriorly, there was only slight thickening of the pyloric muscle. No scarring was apparent. Grossly, the gastric mucous membrane was not remarkable; the gastric wall was thickened to .7 cm.

Microscopic examination: (See Fig. 3) In the area of pyloric thickening, the circular muscular layer was increased in width; the arrangement of cells was of usual pattern. Nerves and ganglia were prominent. The mucosa of the stomach was of typical architecture but there were frequent plasma cells, lymphocytes, neutrophils, and eosinophils in the tunica propria. The muscularis mucosa was somewhat thickened and the muscularis, principally the circular layer, was markedly increased in thickness.

Pathologic diagnosis: Hypertrophy of the pylorus and of the gastric musculature; chronic gastritis.

Subsequent course. The postoperative course was uneventful and the patient was discharged on the eighth postoperative day. Roentgenograms showed normal emptying

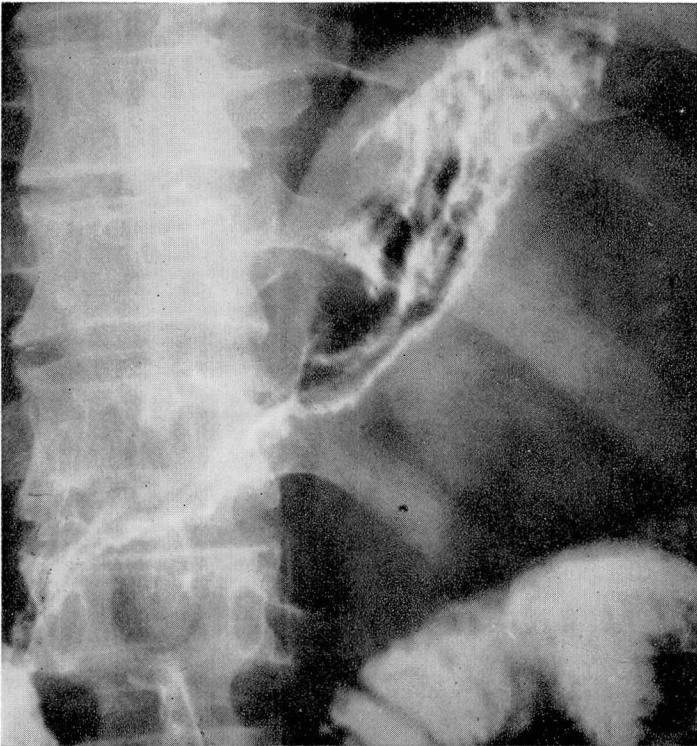


Fig. 4. Postoperative appearance of stomach by roentgenogram. About three fifths of the stomach was resected; continuity was re-established by a Billroth I anastomosis.

of the stomach (Fig. 4). Eighteen months later there had been no recurrence of the abdominal pain. His weight had remained essentially unchanged.

SUMMARY

1. The literature concerning hypertrophic pyloric stenosis in the adult has been briefly reviewed.
2. The variable clinical and histologic picture has been described.
3. It has been argued, on the basis of (1) the frequent presence of a history of epigastric distress dating to childhood, (2) the relative rarity of pyloric hypertrophy as compared with pyloric spasm, and (3) the similar sex incidence in infantile and adult hypertrophic pyloric stenosis, that a congenital etiology is most probable.
4. Because of the virtual impossibility of making the differential diagnosis between hypertrophic pyloric stenosis and prepyloric malignant disease prior to tissue section, subtotal gastric resection is the procedure recommended.
5. A single case report has been added to the literature.

References

1. Cruveilhier, J.: *Anatomic pathologique du corps humain. fol. Paris*, 1829-1842.
2. Maier, R.: *Virchow's Archiv. für pathologische Anatomie und Physiologie* **102**: 413, 1885.
3. Judd, E. S. and Thompson, H. L.: Hypertrophic stenosis of pylorus in adults. *S. Clin. North America* **13**: 801-806 (August) 1933.
4. Kirklin, B. R. and Harris, M. T.: Hypertrophy of pyloric muscle of adults: distinctive roentgenologic sign. *Am. J. Roentgenol.* **29**: 437-442 (April) 1933.
5. Bockus, H. L.: *Gastro-Enterology. Volume I: The Esophagus and Stomach: Examination of Patient, and Diagnosis and Treatment of Disorders of Esophagus and Stomach, Including Duodenal Ulcer.* Philadelphia, W. B. Saunders Co., 1943, p. 759.
6. McClure, C. C.: Hypertrophy of pyloric muscle in adults. *Surg., Gynec. & Obst.* **52**: 945-952 (May) 1931.
7. Crohn, B. B.: Congenital pyloric stenosis in adult life. *J.A.M.A.* **90**: 197-199 (Jan. 21) 1928.
8. Katz, A. B.: Hypertrophic pyloric stenosis in adult. *Am. J. Digest Dis.* **14**: 85-88 (March) 1947.
9. Wakefield, H.: Hypertrophic pyloric stenosis in adults. *Gastroenterology* **2**: 250-257 (April) 1944.
10. Berk, J. E. and Dunlap, H. J.: Hypertrophic stenosis in adults; report of 2 cases. *Ann. Surg.* **119**: 124-133 (Jan.) 1944.
11. Greenfield, H.: Hypertrophic pyloric stenosis in adults. *Ann. Int. Med.* **34**: 492-498 (Feb.) 1951.
12. Horwitz, A., Alvarez, W. C. and Ascanio, H.: Normal thickness of pyloric muscle and influence on it of ulcer, gastro-enterostomy and carcinoma. *Ann. Surg.* **89**: 521-528 (April) 1929.
13. Horton, B. T.: cited by Eusterman, G. B. and Balfour, D. C.: *The Stomach and Duodenum.* Philadelphia, W. B. Saunders Co., 1935, p. 726.