A case of generalized granuloma annulare responding to hydroxychloroquine[1]

Marie C. Carlin, M.D.
John Louis Ratz, M.D., F.A.C.P.

The authors report a case of generalized granuloma annulare which responded favorably to hydroxychloroquine use. Possible pathogenic mechanisms for the disease and past therapeutic modalities are discussed.

Index term: Granuloma, drug therapy

Cleve Clin J Med 54:229–232, May/June 1987

Granuloma annulare is usually a benign, self-limited disease which responds well to topical treatment or intralesional steroids. The generalized variant, however, is a rare form that may involve large areas of the body, be pruritic or tender, and is much more resistant to treatment. We report a case of generalized granuloma annulare responding rapidly and favorably to orally administered hydroxychloroquine (Plaquenil).

Case report

A 76-year-old white woman presented to the Cleveland Clinic Dermatology Department with a nine-month history of a pruritic skin rash that began on her right shin and progressed over two months' time to involve both legs, forearms, neck, face, scalp, and upper back. There was no history of photosensitivity, systemic medications, thyroid disease, or diabetes mellitus. She had been treated by her local dermatologist with hydrocortisone butyrate cream, betamethasone diproprionate ointment, and prednisone (10 mg/day) for two months without improvement. The physical examination revealed large, erythematous annular plaques with borders of confluent and discrete flesh-colored papules over her face, arms, chest, upper back, and lower extremities (*Fig. 1*). The results of the rest of the examination were normal. The laboratory evaluation, including a complete blood count with differential, chemistry profile, rapid plasma reagin, and antinuclear antibody measurement, was also normal. Other laboratory values were: fasting blood sugar, 88 (normal, 65–110); thyroxine, 8.8 μg% (normal, 5.2–11.3); and white blood cell count, 8.5 K/μL (normal, 4.0–11.0).

Multiple skin biopsies were obtained from the upper extremities and all revealed similar pathologic findings. The upper and middle dermis demonstrated granuloma formation with necrobiosis surrounded by lymphocytes and occasional giant cells (*Fig. 2*). A Verhoeff-Von Gieson stain for elastin showed disruption of elastic fibers in the granulomas. A colloidal iron stain for acid mucopolysaccharides was negative. A diagnosis of generalized granuloma annulare was made, and niacinamide therapy was started (100 mg, three times daily) because of its reported effect on suppression of T-cell function. After treatment for two months with slight worsening of the dermatosis and pruritus, niacinamide was discontinued and hydroxychloroquine (200 mg, twice daily) was begun, after a complete ophthalmologic evaluation. Within six weeks, the patient noted marked diminution of the pruritus, and the skin had improved by 50%. Treatment was stopped after three months after nearly complete clearing (*Fig. 3*). The pruritic rash began to return over the next six weeks, however, so the patient resumed the medication at the same dosage, with resultant clearing of the skin.

Discussion

Granuloma annulare is a common dermatosis

[1] Department of Dermatology, The Cleveland Clinic Foundation. Submitted for publication May 1986; accepted Aug 1986.

0891-1150/87/03/0229/04/$2.00/0

Copyright © 1987, The Cleveland Clinic Foundation



Fig. 1. Pretreatment appearance of skin with confluent and discrete flesh-colored and erythematous papules and plaques.



Fig. 2. Well-circumscribed dermal granulomas with necrobiosis of collagen. Lymphocytes, histiocytes, and occasional giant cells are also shown (hematoxylin-eosin, ×100).

which was first described by Colcott Fox in 1895.[1] It typically presents as asymptomatic groups of flesh-colored or red papules often arranged in arciform or annular patterns. In about 15% of patients, the disease is present in a generalized or disseminated form. Hundreds or even thousands of individual 1–2-mm papules arise anywhere on the cutaneous surface with marked involvement of the trunk, occasionally with a marked predilection for sun-exposed areas of the body. Individual papules may be dome shaped or form small rings with a waxy appearance.

Cases of generalized granuloma annulare persist for an average of three to four years, but may last more than a decade. As in the localized form, more women are affected than men (2.5:1). There is a bimodal distribution of age of onset, with peak incidences occurring between ages 30 and 60 years and before age 10. Diabetes, hypoglycemia, and autoimmune thyroid disease have been associated with this disease.

Histologically, generalized granuloma annulare is characterized by dermal or subcutaneous granuloma formation with necrobiosis of collagen, mucin deposition, and a palisading infiltrate consisting of histiocytes and multinucleated giant cells.[1,2]

The cause of granuloma annulare is unknown, but cellular immunity and delayed hypersensitivity responses have been thought to play a role. Lymphocytes and histiocytes have been recognized as the principal cells accompanying focal areas of necrobiosis in both granuloma annulare and granulomas produced by delayed hypersensitivity skin tests. Ultrastructural studies have revealed activated macrophages and lymphocytes similar to those associated with developing delayed hypersensitivity reactions.[3] The strongest evidence for delayed hypersensitivity reaction has been the demonstration by Umbert et al[4] of circulating lymphokines to macrophages in the serum of patients with granuloma annulare. Agents which can suppress T-cell activity and suppress delayed hypersensitivity reactions, including systemic corticosteroids,[1] alkylating agents,[3,5,6] niacinamide,[7] chloroquine,[8–10] and dapsone,[11] have been used successfully to treat generalized granuloma annulare.

The mechanism of action of antimalarial agents in the treatment of generalized granuloma annulare probably involves their immunosuppressive and anti-inflammatory functions. Antimalarials are anti-inflammatory by causing stabi-

lization of lysosomal membranes, inhibiting prostaglandin synthesis, and possibly, other enzyme systems. They also have been shown to inhibit the response of cultured human lymphocytes to mitogens. Finally, antimalarials can inhibit DNA replication and transcription, thus decreasing protein synthesis.[12]

There have been several case reports of successful treatment of generalized granuloma annulare with chloroquine.[8] One patient who had been unresponsive to other systemic medications improved after taking chloroquine (250 mg twice daily for two months). He relapsed soon after stopping the medication, but the dermatosis cleared again one month after resuming the drug.[10] However, chloroquine has been thought to have more long-term toxicity than other antimalarial agents. We decided to use hydroxychloroquine for our patient and noted significant resolution of the disease within six weeks and after resuming the drug following a recurrence of the generalized granuloma annulare.

The antimalarials may produce serious side effects and may affect almost any body system, including the gastrointestinal tract, muscles, nerves, eyes, central nervous system, skin, and bone marrow. The antimalarials can cause gastrointestinal upset, bluish-gray hyperpigmentation, nonspecific cutaneous drug reactions, neurologic changes, corneal deposits of the drug, irreversible retinopathy, and aplastic anemia. Hydroxychloroquine and chloroquine have weak hemolytic effects when given to persons with glucose 6-phosphate dehydrogenase deficiency.

Complete ophthalmologic examination should be performed prior to therapy and every four months thereafter while hydroxychloroquine is being taken because of potential corneal and retinal toxicity. Baseline blood work should include a complete blood count, reticulocyte count, standard chemistry screen, and measurement of glucose 6-phosphate dehydrogenase levels. Both the complete blood count and chemistry screen should be repeated every three to four months. Contraindications for use include pregnancy and retinal disease. Because antimalarials accumulate in the liver, hydroxychloroquine should not be used if hepatic disease is present. The drug should not be given to children. Also, hydroxychloroquine should be used with caution in patients with psoriasis, myasthenia gravis, and multiple sclerosis.

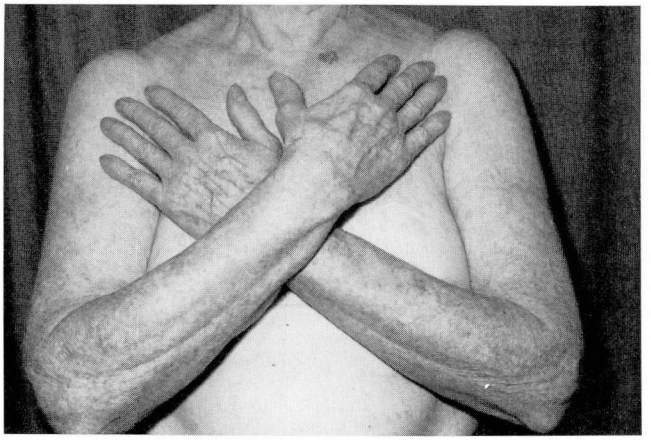

Fig. 3. Skin after three months of treatment. Note the decrease in erythematous papules and plaques.

Dosage is, in general, two to seven times that used for malarial prophylaxis. Isaacson et al[13] suggest a maximum dose of 3.5 mg/lb body weight per day.

Hydroxychloroquine is a relatively safe and effective treatment for generalized granuloma annulare and may be an alternative to the use of systemic corticosteroids or chemotherapeutic agents.

John D. Ratz, M.D.
Department of Dermatology
The Cleveland Clinic Foundation
9500 Euclid Ave.
Cleveland, OH 44106

References

1. Muhlbauer JE. Granuloma annulare. J Am Acad Dermatol 1980; **3:**217–230.
2. Lever WF, Schamburg-Lever G. Histopathology of the Skin. Philadelphia, JB Lippincott, 6th ed, 1983, pp 229–244.
3. Kossard S, Winkelmann RK. Low-dose chlorambucil in the treatment of generalized granuloma annulare. Dermatologica 1979; **158:**443–450.
4. Umbert P, Belcher RW, Winkelmann RK. Lymphokines (MIF) in the serum of patients with sarcoidosis and cutaneous granuloma annulare. Br J Dermatol 1976; **95:**481–485.

5. Rudolph RI. Disseminated granuloma annulare treated with low-dose chlorambucil. Arch Dermatol 1979; **115:**1212–1213.
6. Kossard S, Winkelmann RK. Response of generalized granuloma annulare to alkylating agents. Arch Dermatol 1978;**114:**216–220.
7. Ma A, Madenica M. Response of generalized granuloma annulare to high-dose niacinamide. Arch Dermatol 1983; **119:**836–839.
8. Stritzler C. Generalized granuloma annulare (apparently responding well to chloroquine therapy) (society transaction). Arch Dermatol 1961; **83:**1033–1034.
9. Stankler L, Leslie G. Generalized granuloma annulare: a report of a case and review of the literature. Arch Derm 1967; **95:**509–513.
10. Mandel EH. Disseminated granuloma annulare: report of a case treated with chloroquine phosphate (Aralen) (clinical note). Arch Derm 1959; **79:**352–353.
11. Saied N, Schwartz RA, Estes SA. Treatment of generalized granuloma annulare with dapsone (letter). Arch Dermatol 1980; **116:**1345–1346.
12. Tanenbaum L, Tuffanelli DL. Antimalarial agents: chloroquine, hydroxychloroquine, and quinacrine. Arch Dermatol 1980; **116:**587–591.
13. Isaacson D, Elgart M, Turner ML. Anti-malarials in dermatology. Int J Dermatol 1982; **21:**379–395.