

## THE CLINICAL PICTURE



**EDUCATIONAL OBJECTIVE:** Readers will be alert to the danger of fungal lung infections in immunocompromised patients

**ADRIANO R. TONELLI, MD**

Division of Pulmonary, Critical Care and Sleep Medicine, University of Florida, Gainesville

**ERIC L. OLSON, MD**

Assistant Professor, Division of Pulmonary, Critical Care and Sleep Medicine, University of Florida, Gainesville

# The Clinical Picture

## A 19-year-old man with progressive lung infiltrates

**A** 19-YEAR-OLD MAN RECEIVED induction chemotherapy with idarubicin and cytarabine for secondary acute myeloid leukemia. Subsequently, he developed fever, progressive lung infiltrates, and severe neutropenia. His white blood cell count was  $1.1 \times 10^9/L$  (reference range 4.0–11.0) with 100% lymphocytes; his blood glucose level remained normal.

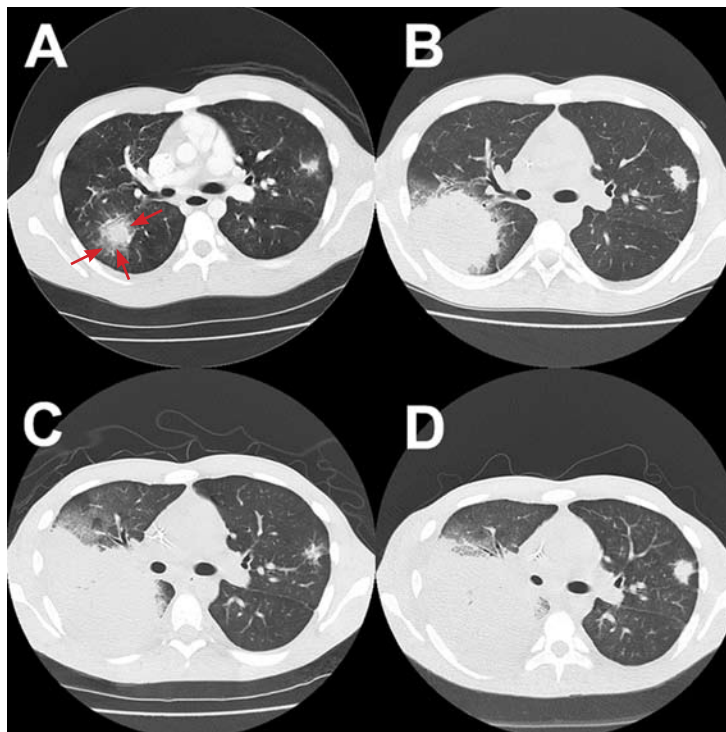
The patient was admitted to the hospital. Bronchoscopy showed the airways to be normal, but the bronchoalveolar lavage (BAL) fluid contained an elevated number of white blood cells, predominantly monocytes. A galactomannan antigen test (a test for *Aspergillus*) of the BAL fluid gave a result of 0.7 (a positive result is  $\geq 0.5$ ). Cultures of the BAL fluid and of transbronchial biopsy specimens were negative for bacteria and fungi. A galactomannan test of the blood was negative at 0.24.

The patient was treated with voriconazole (Vfend) and broad-spectrum antibiotics.

In the next month and a half, serial computed tomographic scans of the chest were performed (FIGURE 1). The patient underwent bronchoscopy again (between images C and D in FIGURE 1), which revealed an endobronchial lesion in the right upper lobe that had not been seen before (FIGURE 2). A bronchial biopsy specimen was examined microscopically with Gomori methenamine silver staining (FIGURE 3). A galactomannan test of the second BAL specimen was negative.

After the second bronchoscopy, appropriate therapy was started, but the patient died after 2 months in the hospital as a result of massive hemoptysis.

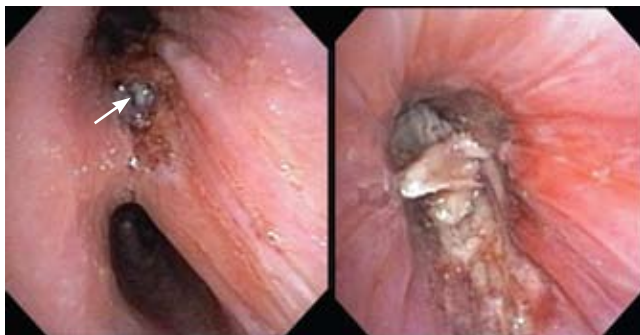doi:10.3949/ccjm.76a.08111



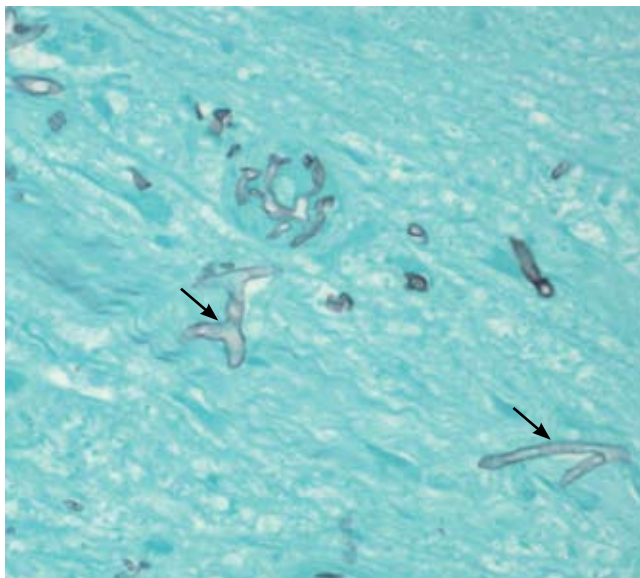
**FIGURE 1.** Sequential axial computed tomographic images of the chest in the course of 1.5 months. Note the progression of lung infiltrates in the right and left upper lobes, as well as the “halo sign” (arrows in image A). The patient had associated pleural effusion and progression of the infiltrate in the right side to the lower lobe, as seen in images C and D. He had a second bronchoscopy and began appropriate therapy after image C.

**Q:** Which is the most likely cause?

- A bacterium
- A virus
- Cryptococcus*
- Aspergillus*
- Zygomycetes*



**FIGURE 2.** Left: bronchoscopic image at the level of the division of the right upper lobe and bronchus intermedius. A grey-white endobronchial lesion is seen in the right upper lobe. Right: Close-up of the fungating endobronchial lesion in the right upper lobe.



**FIGURE 3.** Histopathologic examination of the endobronchial tissue using Gomori methenamine silver stain. Note the irregularly shaped, broad, and nonseptate hyphae with predominantly right-angle branching.

**A:** The correct answer is *Zygomycetes*, the second most common cause of fungal respiratory disease in patients with hematologic malignancies.

**■ UNCOMMON BUT OFTEN FATAL**

*Zygomycetes* is a class of fungi that contains two orders, *Mucorales* and *Entomophthorales*. Human disease, which is uncommon but frequently fatal, is predominantly associ-

ated with *Mucorales* and is commonly called mucormycosis.<sup>1,2</sup>

The major mode of transmission is through inhalation of spores from diverse decaying environmental sources. As *Zygomycetes* are aerogenous pathogens, they predominantly affect the paranasal sinuses and the lungs. The main risk factors for *Zygomycetes* infection include diabetes mellitus, hematologic malignancies (predominantly acute leukemias treated with aggressive chemotherapeutic regimens), pharmacologic immunosuppression, solid organ or bone marrow transplantation, and therapy with deferoxamine (Desferal), an iron-chelating agent.<sup>1,3</sup>

Overall, rhinocerebral disease is the most common manifestation, especially in the setting of diabetic ketoacidosis.<sup>1</sup> In hematologic malignancies, the most common presentation is pulmonary zygomycosis with associated profound neutropenia, as neutrophils are the central defense against filamentous fungal hyphae.<sup>1,4</sup>

The incidence of zygomycosis is increasing, likely owing to the greater number of patients receiving stem cell or solid organ transplants, the use of more aggressive immunosuppressive regimens, prolonged survival, and the frequent prophylactic use of antifungal agents without activity against *Zygomycetes*.<sup>2,5</sup>

**■ INFECTION PROGRESSES RAPIDLY**

Most patients present with fever, cough, thoracic pain, and dyspnea in association with hypoxemia and pulmonary infiltrates refractory to broad-spectrum antibiotics. Zygomycosis can also present radiographically as pulmonary nodules or consolidations with or without the halo sign or cavitations.<sup>6,7</sup>

The disease usually progresses rapidly, invading vessels and causing infarction, bleeding, and dissemination to extrapulmonary sites.<sup>1,5</sup>

In reported cases in patients with acute leukemia who received aggressive chemotherapy, the fungal infection occurred several days after profound neutropenia developed.<sup>3,4</sup>

**■ SPUTUM, LAVAGE, BIOPSY**

The diagnosis is based on directly identifying the fungus morphologically and on culturing

it. However, cultures of sputum, BAL fluid, and blood are usually negative.

Morphologically, the fungus is broad with irregular walls; it is also nearly aseptate and frequently has right-angle branching. In contrast, *Aspergillus* is narrow with parallel walls, distinctive septae, and acute branching.<sup>2</sup>

Of note: physicians need to alert the microbiology laboratory about their clinical suspicion of *Zygomycetes* infection, because the recovery rate of *Zygomycetes* in culture is increased by slicing the biopsy specimen in small pieces but not dicing it (to avoid breaking the septae).<sup>1</sup>

The diagnostic tests include microscopic examination and culture of sputum, BAL fluid, and transbronchial biopsy specimens. If the initial tests are negative but the suspicion of zygomycosis is strong on clinical grounds, then fine-needle aspiration or open lung biopsy should be considered.<sup>1</sup>

Useful predictors that favor the diagnosis of pulmonary zygomycosis instead of the main alternative, invasive pulmonary aspergillosis, include concomitant sinusitis, voriconazole prophylaxis (due to antifungal pressure), a negative galactomannan test in serum, multiple pulmonary nodules, and pleural effusion.<sup>2,8</sup>

### ■ TREATMENT WITH AMPHOTERICIN

The treatment includes giving effective antifungal agents promptly, correcting hyperglycemia and metabolic acidosis, reversing immunosuppression (if possible), and considering surgical debridement.<sup>1,2</sup>

Antifungal therapy is with conventional amphotericin B (Amphocin) or its lipid formulation (Abelcet). The lipid formulation is at least as effective as conventional amphotericin B and less nephrotoxic, thus allowing higher doses.<sup>1,9</sup> The optimal duration of therapy has not been evaluated, but experts in general treat until the pulmonary and sinus lesions have resolved.<sup>2</sup>

Posaconazole (Noxafil), a broad-spectrum oral azole, has activity in vitro and is a valuable alternative for patients who have refractory zygomycosis or who cannot tolerate amphotericin B.<sup>5,10</sup>

The role of echinocandins is unclear, as they do not have in vitro activity against *Zygomycetes*. However, tests in animals have shown a synergistic effect between the echinocandin

caspofungin (Cancidas) and amphotericin B lipid complex.<sup>11</sup> Other antifungal agents such as azoles lack activity against *Zygomycetes*.<sup>5</sup>

The return of neutrophils plays a substantial role in resolving the infection in neutropenic patients, a proposition supported by reports of the failure of antifungal therapy in patients with persistent neutropenia.<sup>1</sup> The addition of granulocyte colony-stimulating factor may accelerate neutrophil recovery and enhance neutrophil activity against opportunistic fungal pathogens.<sup>12</sup>

Even though progress has been made in the treatment of this disease, the prognosis continues to be poor in patients with hematologic malignancies and pulmonary or disseminated zygomycosis.<sup>9</sup>

### ■ ENDOBRONCHIAL ZYGOMYCOSIS

Aspergillosis is the most common endobronchial fungal disease. Zygomycosis is the third most common, after coccidioidomycosis. In zygomycosis, endobronchial lesions can be found in a third of patients who have pulmonary involvement.<sup>6,13,14</sup>

The most common predisposing conditions for the development of endobronchial zygomycosis are diabetes and hematologic malignancies associated with neutropenia.<sup>14</sup>

Endobronchial zygomycosis is characterized by a locally invasive gray-white mucoid lesion that blocks a major airway.<sup>13</sup> The involved airway is usually edematous and necrotic. The diagnosis can be made by visualizing the organism in bronchial washings, brushings, or endobronchial biopsies.<sup>14</sup>

If the disease is not promptly diagnosed, the risk of death is very high. The management includes high-dose conventional or lipid amphotericin B and surgical or endobronchial resection.<sup>13,15</sup>

### ■ OUR CASE CONTINUED

After *Zygomycetes* was seen in the tissue from his bronchial biopsy, our patient received amphotericin B lipid complex at 5 mg/kg/day (started between images C and D in **FIGURE 1**). He had a good initial clinical response, but the infection progressed (image D in **FIGURE 1**).

The patient died as a result of massive he-

**Risk factors for zygomycosis: diabetes, aggressive chemotherapy for leukemia, immunosuppressive drugs, deferoxamine**

## PROGRESSIVE LUNG INFILTRATES

moptysis attributable to the angioinvasive nature of the fungus, which most likely caused an erosion of a major pulmonary vessel.

### TAKE-HOME POINTS

- Pulmonary disease is the most common manifestation of zygomycosis in patients
- with underlying hematologic malignancy. In this setting, zygomycosis has a high rate of morbidity and death.
- Endobronchial lesions can be seen in up to a third of patients with pulmonary zygomycosis.
- Prompt and effective therapy is essential for treatment to be successful. ■

### REFERENCES

1. Gonzalez CE, Rinaldi MG, Sugar AM. Zygomycosis. *Infect Dis Clin North Am* 2002; 16:895-914.
2. Pyrgos V, Shoham S, Walsh TJ. Pulmonary zygomycosis. *Semin Respir Crit Care Med* 2008; 29:111-120.
3. Kara IO, Tasova Y, Uguz A, Sahin B. Mucormycosis-associated fungal infections in patients with haematologic malignancies. *Int J Clin Pract* 2007; 63:134-139.
4. Pagano L, Offidani M, Fianchi L, et al. Mucormycosis in hematologic patients. *Haematologica* 2004; 8:207-214.
5. van Burik JA, Hare RS, Solomon HF, Corrado ML, Kontoyiannis DP. Posaconazole is effective as salvage therapy in zygomycosis: a retrospective summary of 91 cases. *Clin Infect Dis* 2006; 42:e61-e65.
6. Jamadar DA, Kazerooni EA, Daly BD, White CS, Gross BH. Pulmonary zygomycosis: CT appearance. *J Comput Assist Tomogr* 1995; 19:733-738.
7. Lee YR, Choi YW, Lee KJ, Jeon SC, Park CK, Heo JN. CT halo sign: the spectrum of pulmonary diseases. *Br J Radiol* 2005; 78:862-865.
8. Chamilos G, Marom EM, Lewis RE, Lionakis MS, Kontoyiannis DP. Predictors of pulmonary zygomycosis versus invasive pulmonary aspergillosis in patients with cancer. *Clin Infect Dis* 2005; 41:60-66.
9. Gleissner B, Schilling A, Anagnostopoulos I, Siehl I, Thiel E. Improved outcome of zygomycosis in patients with hematological diseases? *Leuk Lymphoma* 2004; 45:1351-1360.
10. Greenberg RN, Mullane K, van Burik JA, et al. Posaconazole as salvage therapy for zygomycosis. *Antimicrob Agents Chemother* 2006; 50:126-133.
11. Spellberg B, Fu Y, Edwards JE Jr, Ibrahim AS. Combination therapy with amphotericin B lipid complex and caspofungin acetate of disseminated zygomycosis in diabetic ketoacidotic mice. *Antimicrob Agents Chemother* 2005; 49:830-832.
12. Liles WC, Huang JE, van Burik JA, Bowden RA, Dale DC. Granulocyte colony-stimulating factor administered in vivo augments neutrophil-mediated activity against opportunistic fungal pathogens. *J Infect Dis* 1997; 175:1012-1015.
13. Husari AW, Jensen WA, Kirsch CM, et al. Pulmonary mucormycosis presenting as an endobronchial lesion. *Chest* 1994; 106:1889-1891.
14. Karnak D, Avery RK, Gildea TR, Sahoo D, Mehta AC. Endobronchial fungal disease: an under-recognized entity. *Respiration* 2007; 74:88-104.
15. al-Majed S, al-Kassimi F, Ashour M, Mekki MO, Sadiq S. Removal of endobronchial mucormycosis lesion through a rigid bronchoscope. *Thorax* 1992; 47:203-204.

ADDRESS: Adriano R. Tonelli, MD, Health Science Center, 1600 SW Archer Road, Room M452, PO Box 100225, Gainesville, FL 32610-0225; e-mail Adriano.Tonelli@medicine.ufl.edu.



The *Cleveland Clinic Journal of Medicine* uses the AMA's database of physician names and addresses.

(All physicians are included in the AMA database, not just members of the AMA.) Only

the AMA can update this data, and will accept a change-of-address notice only from you.

Be sure your primary specialty and type of practice also are up-to-date on AMA records. This information is important in determining who receives the *Cleveland Clinic Journal of Medicine*.

If you have ever notified the AMA that you did not want to receive mail, you will not receive the *Cleveland Clinic Journal of Medicine*. You can reverse that directive by notifying the AMA. Please note that a change of address with the AMA will redirect all medically related mailings to the new location.

### FOR FASTER SERVICE

■ PHONE 800-262-3211 ext. 5192

■ FAX 312-464-5843

■ E-MAIL nicole\_neal@www.ama-assn.org

or send a recent mailing label along with new information to:

AMA  
DEPARTMENT OF DATA SERVICES  
515 North State Street  
Chicago, IL 60654

### NEW INFORMATION

NAME

STREET ADDRESS

CITY

STATE

ZIP

Please allow 6 to 8 weeks for change to take effect