

(Cleve Clin Q 26:144-147, 1959)

REMISSION OF LESIONS IN MYCOSIS FUNGOIDES FOLLOWING TOPICAL APPLICATION OF NITROGEN MUSTARD

A Case Report

JOHN R. HASERICK, M.D., JOSEPH H. RICHARDSON, M.D.,*

and

DOUGLAS J. GRANT, M.D.†

Department of Dermatology

MMETHYL - BIS - (β - CHLOROETHYL) AMINE HYDROCHLORIDE, commonly known as nitrogen mustard, is a nitrogen analogue of sulfur mustard, the vesicant gas of World War I. In 1931, Adair and Bagg reported that the topical and intralesional use of sulfur mustard in the treatment of numerous types of primary and secondary cutaneous malignant lesions gave good initial results, but this therapeutic moiety was subsequently neglected.

Following the development of nitrogen mustard, investigational studies² into its actions led to the recognition of the similarity of these actions to those of irradiation. Shortly afterwards, nitrogen mustard was used intravenously in the treatment of various forms of lymphoma.³⁻⁵ Its use then became extended to the local treatment of malignant effusions in the pleural and peritoneal cavities, and in rheumatoid arthritis⁶ to the intraarticular cavities.

The purpose of this preliminary report is to present a case of remission in lesions of mycosis fungoides after the local applications of diluted nitrogen mustard solution. To our knowledge this is the first such observation.

Report of a Case

In 1956, a 28-year-old white man was examined by his local physician because of a blotchy nonpruritic axillary eruption. The diagnosis of mycosis fungoides was confirmed by biopsy. Twelve applications of roentgen therapy were given but brought no relief, and the patient was then referred to the Cleveland Clinic.

At the time of our initial examination in February, 1958, the eruption showed discrete, nummular, pea to silver dollar sized erythematous scaling, slightly infiltrated lesions predominantly in the groin and in the axillae. The other findings from the physical examination were essentially normal, and laboratory studies were noncontributory.

During the next thirteen months the lesions became more numerous and widespread, heavily infiltrated, nodular, and pruritic. On April 4, 1959, the patient was admitted to our hospital for treatment. Nitrogen mustard was administered intravenously on three alternate days for a total dosage of 0.4 mg. per kilogram of body weight. During this course of therapy, on three successive days nitrogen mustard was applied topically to half the area of each of two plaques on the patient's arms. Several days later, pruritus

* Formerly Fellow in the Department of Internal Medicine; present address: 911 River Drive, Marion, Indiana.
† Fellow in the Department of Dermatology.

TOPICAL NITROGEN MUSTARD IN MYCOSIS FUNGOIDES

had disappeared, the lesions began to regress, and the patient was discharged from the hospital. Within three weeks there was recurrence (*Fig. 1*) in all lesions except in the sites treated topically with nitrogen mustard.

Fig. 1. Lesions of mycosis fungoides before topical therapy.

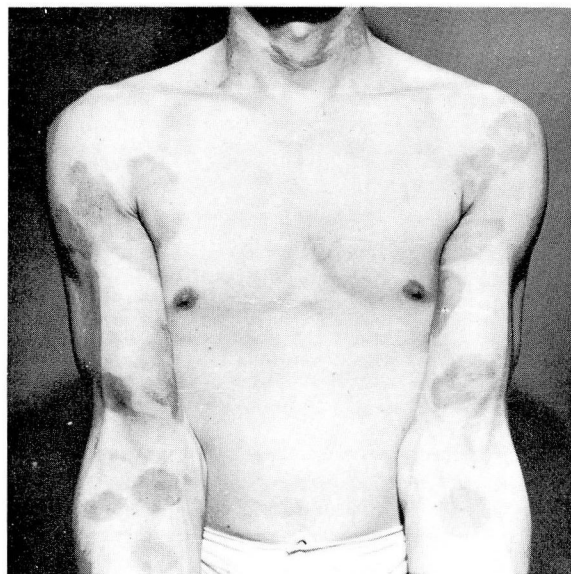
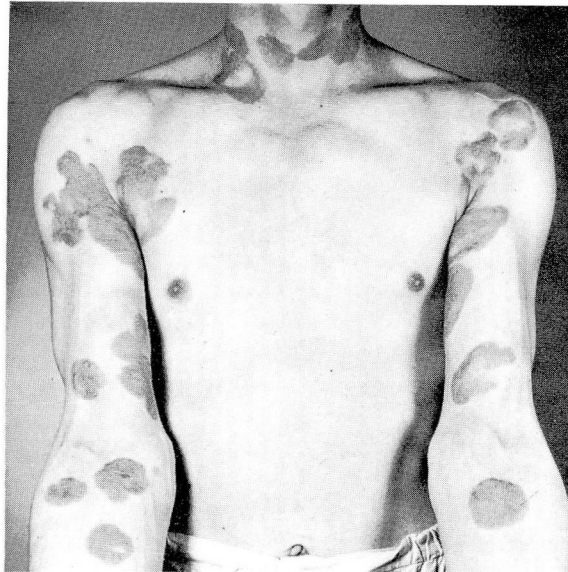


Fig. 2. Lesions of mycosis fungoides three weeks after topical therapy with nitrogen mustard solution.

(Cleve Clin Q 26:144-147, 1959)

HASERICK, RICHARDSON, AND GRANT

The patient was readmitted to the hospital on June 24, 1959, for further topical therapy. Most of the recurrent lesions were covered with gauze pads that were dampened with a solution of nitrogen mustard (10 mg. per 50 ml. of saline solution). The pads were left in place for 15 minutes. This treatment was applied on three consecutive days. Within 48 hours of the last application the lesions became mildly erythematous and then gradually flatter, nonpruritic, and less infiltrated (*Fig. 2*). Lesions that were not treated showed no regression. There was no evidence of systemic toxicity; there were no changes in the hemoglobin content and in the leukocyte count; and there was no reactivation of lesions during the month following treatment.

Discussion

The complications of nitrogen mustard intravenously administered are well known. Toxic systemic reactions occur, such as nausea, vomiting, and depression of formed elements in the circulating blood. This toxicity limits the size of the individual dose of nitrogen mustard and the frequency of its administration. It appears from our preliminary studies that these reactions were avoided by topical application.

Nitrogen mustard in polar solvents, by intramolecular cyclization, forms highly reactive transient groups that are rapidly destroyed by self-interaction and contact with tissue elements. The effect exerted upon living cells by nitrogen mustard is intimately related to the mitotic activity of these cells; therefore, anaplastic tissues are more profoundly influenced than are well-differentiated tissues. Since nitrogen mustard is rapidly deactivated by tissue contact, little systemic effect would be expected from topical application. Consideration of the above factors led us to attempt the treatment of mycosis fungoides by the topical application of nitrogen mustard, despite the potential dangers of sensitization.⁷

Summary

A solution of nitrogen mustard, applied topically on three consecutive days to long-standing lesions of mycosis fungoides, gave good initial results and no evidence of sensitization or systemic toxicity. There was no reappearance of lesions topically treated during intravenous nitrogen mustard therapy, although the others did recur. Subsequent topical application has resulted in the regression of all lesions during the month of posttherapeutic observation.

References

1. Adair, F. E., and Bagg, H. J.: Experimental and clinical studies on treatment of cancer by dichlorethylsulphide (mustard gas). *Ann. Surg.* 93: 190-199, 1931.
2. Gilman, A., and Philips, F. S.: Biological actions and therapeutic applications of β -chloroethyl amines and sulfides. *Science* 103: 409-415, 1946.

(*Cleve Clin Q* 26:144-147, 1959)

TOPICAL NITROGEN MUSTARD IN MYCOSIS FUNGOIDES

3. Rhoads, C. P.: Nitrogen mustards in treatment of neoplastic disease; official statement. *J. A. M. A.* 131: 656-658, 1946.
4. Henstell, H. H., and Tober, J. N.: Treatment of mycosis fungoides with nitrogen mustard. *J. Invest. Dermat.* 8: 183-188, 1947.
5. Kierland, R.; Watkins, C. H., and Shullenberger, C. C.: Use of nitrogen mustard in treatment of mycosis fungoides. *J. Invest. Dermat.* 9: 195-201, 1947.
6. Scherbel, A. L.; Schuchter, S. L., and Weyman, S. J.: II. Intraarticular administration of nitrogen mustard alone and combined with a corticosteroid for rheumatoid arthritis; experimental and clinical studies. *Cleveland Clin. Quart.* 24: 78-89, 1957.
7. Nexmand, P. H.: Skin sensitization to nitrogen mustard with reference to cytologic differences between primary-irritant and eczematous reactions. *Dermatologica* 100: 73-86, 1950.

(Cleve Clin Q 26:144-147, 1959)