Duodenoscopy

A study of 94 cases

Kenneth L. Burkhart, M.D.*
B. H. Sullivan, Jr., M.D.
Richard G. Farmer, M.D.

Department of Gastroenterology

Endoscopists have been examining the esophagus for 40 years, but that portion of the gastrointestinal tract beyond the pylorus has eluded them. Hirschowitz[1] in describing the application of his fiberoptic gastroscope claimed that this instrument could enter the duodenal bulb. Few others were able to emulate him. When certain technical refinements, including a controllable tip for the gastroscope, were introduced in 1968, many examiners could maneuver the instrument into the duodenal bulb in about 20% of their examinations. It was not until early 1971 that the American Cystoscope Makers, Inc. introduced an instrument (Model 7089-J) with which an experienced operator could examine not only the esophagus and stomach, but also the duodenal bulb in most of the cases studied. In rare instances, it was possible to advance the instrument beyond the bulb and into the descending duodenum. Meanwhile, Japanese instrument makers had developed instruments designed exclusively for examination of the duodenum and had adopted a side-viewing instrument, because they wished to catheterize the ampulla of Vater for the purpose of obtaining pancreatograms and retrograde cholangiograms. Reports of experiences with these new instruments were published in the Japanese literature beginning in 1968.[2-5]

* *Fellow, Department of Gastroenterology.*

We have had an opportunity to use both instruments. The ACMI instrument is forward-viewing, 105 cm long, has a directable tip, a biopsy channel, and facilities for suction and inflating. Photographs are made by an external camera. The Olympus JF-B Duodenoscope, 120 cm long, has a diameter of 10 mm at its distal end, and four-way deflection is possible. It is side-viewing, and a lever controls the elevation of the biopsy forceps (or cannula). Photographs are made by a special external camera with automatic exposure.

Materials and methods

During the 5-month period, duodenal examinations were made in 94 patients utilizing the same premedication (intravenous meperidine and diazepam) and techniques employed for esophagoscopy or gastroscopy. Some of these examinations were performed on patients who had lesions in the esophagus or stomach which warranted endoscopic inspection. The duodenum was examained to exclude the presence of another lesion.

Results

The abnormal findings in 23 examinations of the duodenum are listed in *Table 1.* Two of the patients had no radiographic examination of the upper gastrointestinal tract.

Table 1.—Classification of duodenal lesions in 23 patients

Diagnosis	Number of patients
Duodenitis	8
Duodenal ulcer	5
Pseudodiverticulum	2
Duodenal polyp	2
Carcinoma	2
Carcinoma of ampulla	1
Diverticulum	1
Hypertrophic folds	1
Scar	1

Duodenoscopy confirmed the radiographic findings in 13 patients. Radiographic examination was normal in seven other patients, but mucosal hypertrophy (1 case) and hemorrhagic erosions (6 cases) were found on duodenoscopy. The remaining patient had radiographic evidence of a duodenal ulcer, but this was not confirmed on duodenoscopy, although erythematous duodenitis was observed.

No abnormality was detected in 71 of the 94 examinations. Twenty-six of these patients were examined primarily for a suspected abnormality in the esophagus or stomach. Fifteen patients were examined to determine the site of gastrointestinal bleeding. Six of these examinations were normal; in the other nine patients the site of bleeding was in the stomach or esophagus. Of the remaining 30 patients with normal duodenoscopies, 23 were examined for nonspecific complaints such as abdominal pain even though x-ray examinations were normal. Seven patients had radiographic diagnoses of duodenal polyp (3 patients), duodenal deformity (1 patient), or duodenal ulcer (3 patients), but these lesions were not demonstrated endoscopically.

Case reports

Case 1. A 64-year-old man was referred to the Cleveland Clinic in July 1971 with a 2-month history of increasing fatigue. Evaluation at his local hospital revealed a low hemoglobin (10.2 g/100 ml), elevated bilirubin (2.6 mg/100 ml), alkaline phosphatase (100 KA units), and SGOT (225 K units). Upper gastrointestinal roentgenograms were normal. Duodenoscopy demonstrated a nodular mass in the sec-

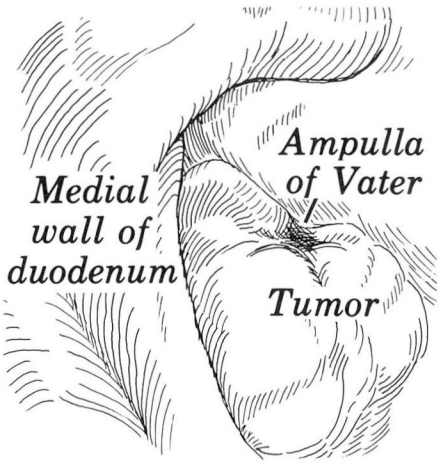

Fig. 1. A, Case 1. Roentgenogram of duodenum shows some deformity of the descending portion.

B, Line drawing of tumor mass at the ampulla of Vater.

C, Case 1. Photograph of a large tumor mass at the ampulla of Vater.

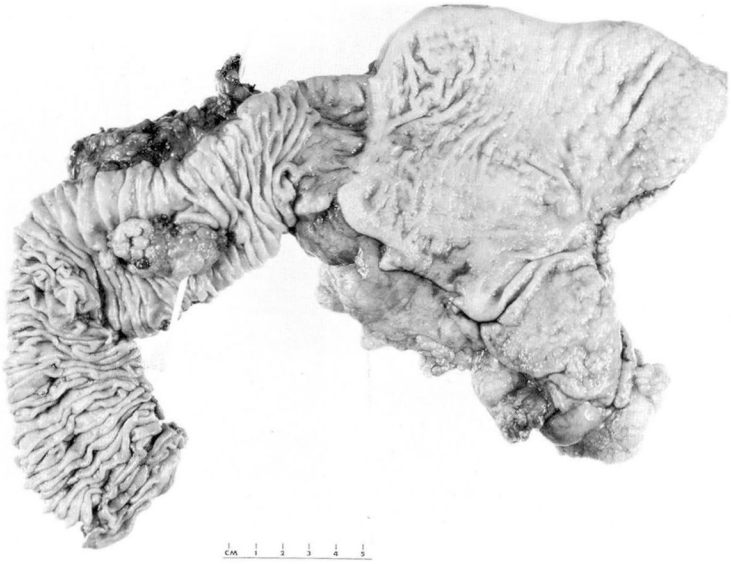

D, Case 1. Photograph of the surgical specimen. The duodenum has been opened and a probe passed through the main pancreatic duct and ampulla of Vater. The tumor mass surrounds the probe.

ond portion of the duodenum involving the ampulla of Vater. Biopsy of the mass revealed mucosal segments with moderate chronic inflammation and focal glandular atypia. Operation on the following day verified the diagnosis of ampullary carcinoma. A Whipple procedure was performed. Two lymph nodes were positive for metastatic tumor. The patient was doing quite well when last seen in November 1971.

Case 2. A 72-year-old woman, who had had a partial colon resection 4 years previously for carcinoma, with no evidence of metastases, noted in December 1970 the onset of anorexia and weight loss. She was admitted to her local hospital in April 1971, and received two units of blood for anemia. She was hospitalized again in July 1971, and received four units of blood. She was then transferred to the Cleveland Clinic. Outside radiographic examination of the upper gastrointestinal tract showed a lesion in the second portion of the duodenum. Barium enema examination performed at the Cleveland Clinic revealed an obstructing mass in the transverse colon. Duodenoscopy showed a

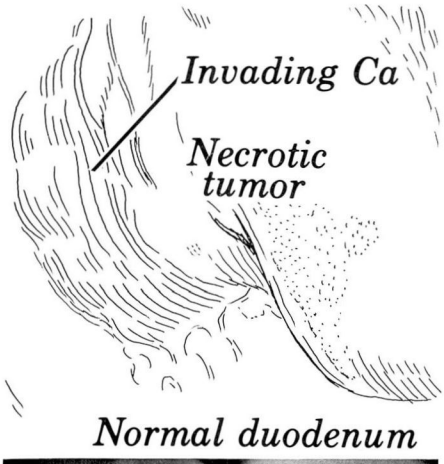

Fig. 2. A, Case 2. Roentgenogram shows a large duodenal bulb with a filling defect in its inferior surface. Descending duodenum is irregularly distorted, suggesting possible tumor invasion.

B, Line drawing of a large tumor mass, just beyond the duodenal bulb. C, Photograph of colon carcinoma involving duodenal bulb.

multilobular tumor mass almost filling the descending duodenum. Biopsy showed gastrointestinal mucosa with moderate atypicality. The following day, carcinoma involving the colon, duodenum, jejunum, and mesentery was found at laparotomy. A gastrojejunostomy was performed with the placement of a feeding tube, but renal complications developed and the patient died 7 days after operation.

Case 3. A 73-year-old man with known posthepatitic cirrhosis and portal hypertension had a portacaval shunt performed at the Cleveland Clinic in April 1970. When seen in July 1971, he gave a 1-month history of abdominal pain and melena, and was found to have a hemoglobin of 6 g/100 ml. Duodenoscopy performed on July 20 revealed a reddish-purple polypoid mass in the duodenal bulb which appeared to be the site of blood loss. At laparotomy, a large metastatic hepatoma which had eroded into the duodenum was removed; it was not connected to the liver. The patient died 2 days after operation from renal complications. Portal cirrhosis, hemochromatosis and intrahepatic hepatoma, as well as

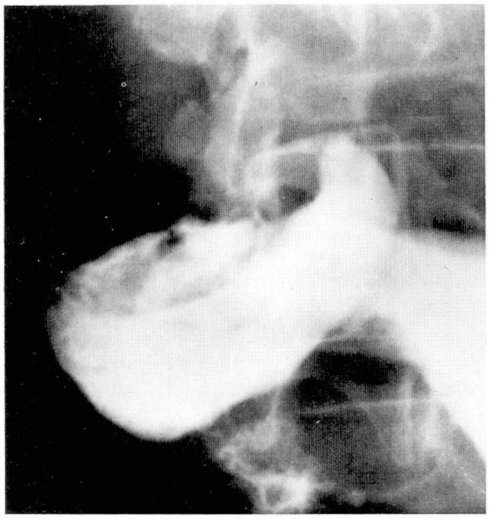

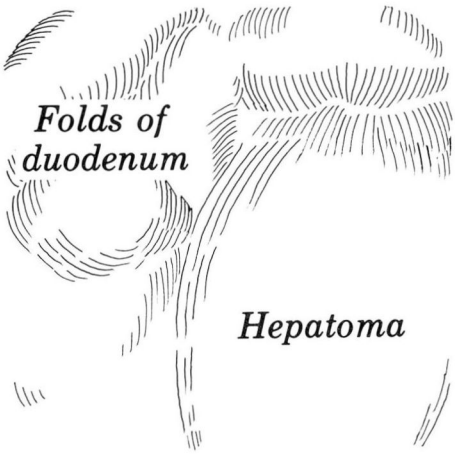

Fig. 3. A, Case 3. Roentgenogram shows a filling defect in the superior portion of the duodenal bulb, as a rounded configuration, suggesting the presence of a tumor mass or an ulcerating neoplasm. B, Drawing of a large, smooth neoplasm in the duodenal bulb. C, Photograph of a metastatic hepatoma in the wall of the duodenal bulb.

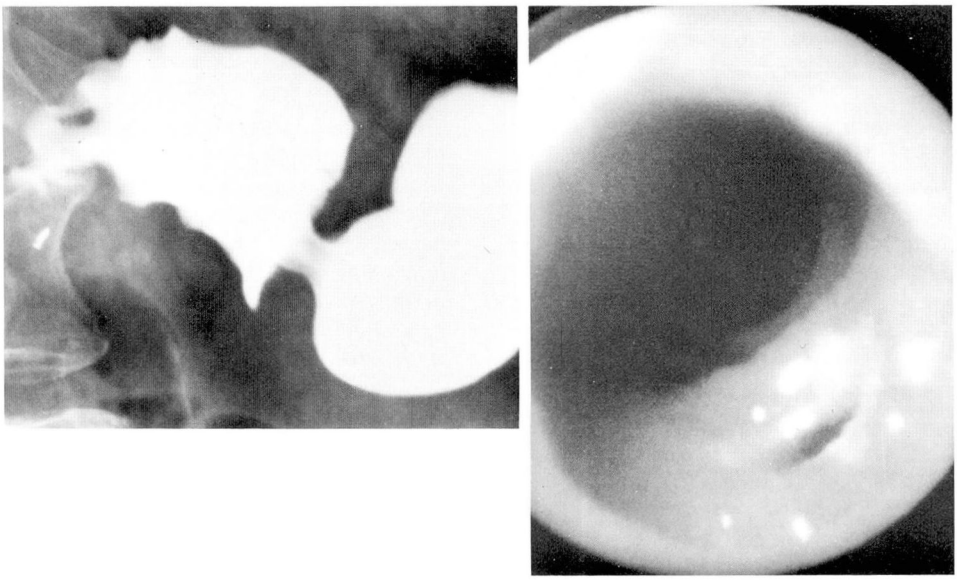

Fig. 4. A, Case 4. Roentgenogram of the duodenal bulb showing deformity of the inferior aspect of the bulb, suggesting the presence of a duodenal ulcer crater in the central portion of the bulb on the posterior wall. B, Photograph of duodenal ulcer on the inferior (greater curvature aspect) wall of the duodenal bulb in about the midportion.

microscopic pulmonary metastases were observed at autopsy.

Case 4. A 71-year-old man was examined in February 1971 for abdominal pain, regurgitation, and dysphagia. He was found to have a hiatal hernia, peptic esophagitis, stricture, and a duodenal ulcer. A medical treatment program was begun but the patient continued to experience abdominal pain. Reevaluation with duodenoscopy revealed a 14-mm deeply punched-out ulcer with a black clot in the center. Continued medical therapy resulted in improvement, but there was little change in the endoscopic findings when he was reexamined 2 months later.

Case 5. A 64-year-old woman came to the Cleveland Clinic for a routine checkup in July 1970. An upper gastrointestinal roentgenogram revealed a 1.5-cm radiolucent defect in the immediate postbulbar region. Review of films from a study made 4 years earlier showed the same lesion. Duodenoscopy showed this defect to be an 8-mm sessile polyp in the proximal second portion of the duodenum. Biopsy of the polyp showed normal duodenal mucosa. The patient was reassured and no further treatment was required for the benign polyp.

Comment

Eighty-four patients had radiographic study of the duodenum prior to endoscopy. Radiologic and endoscopic diagnoses were consonant in 69 (82%) of these cases. This is somewhat higher than the 72% reported by Belber,[6] probably because more of our studies were normal, thus tending to increase the correlation between endoscopic and radiographic findings. Ten patients did not have radiographic examination of the duodenum prior to duodenoscopy. Nine of these were examined to determine the etiology of acute upper gastrointestinal hemorrhage.

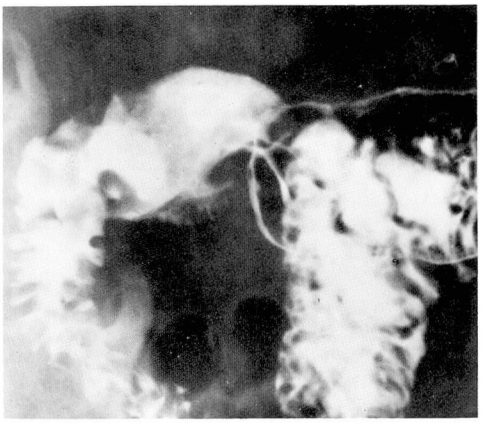

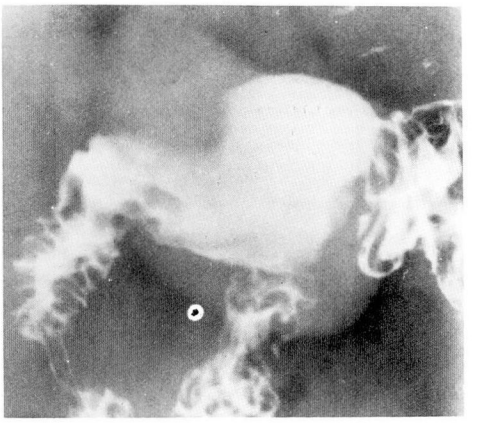

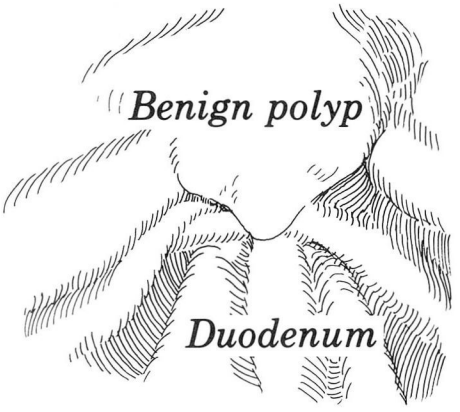

Fig. 5. A, Case 5. Roentgenogram of the duodenal bulb shows a rounded filling defect with central opacification, suggesting the presence of an ulcerating tumor mass located at the apex of the duodenal bulb on its inferior aspect. B, The 1968 roentgenogram shows the same lesion. There has been virtually no change in size. C, Line drawing of photograph of benign polyp in the apex of the duodenal bulb. D, Photograph, Case 5. A smooth protrusion is seen, but no ulcer was identified.

No complications have occurred in our limited experience. The examination of the duodenum adds 10 to 15 minutes to the time required for esophagoscopy and gastroscopy when the ACMI instrument is used. Useful information is often obtained by carrying the examination a few centimeters distal to the pylorus. However, it is still possible to overlook a lesion on the distal surface of the pylorus (base of the duodenal bulb) with this instrument, and in most cases very little can be seen beyond the duodenal bulb. If there is suspicion of a lesion beyond the bulb, it is advisable to employ the Olympus JF-B Duodenoscope. Since this instrument cannot be used to inspect the esophagus and is unsatisfactory as a gastroscope, no time is spent examining these two organs. The time required to place it in the

duodenum varies, but seldom exceeds 5 minutes. We have not attempted to catheterize the ampulla of Vater, but it is reported that this technique is not easy and may be time-consuming. We have used the biopsy forceps and found them to be effective and no more difficult to operate than the forceps of the esophagoscope and gastroscope.

Summary

Ninety-four duodenoscopic examinations were performed in a 5-month period. Many examinations were confined to the duodenal bulb. Lesions were discovered in 23 examinations. The endoscopic and radiographic findings were in accord in 82% of the cases. A special side-viewing duodenoscope is required for adequate examination beyond the first portion of the duodenum. Duodenoscopy is a safe and effective means of confirming the presence of lesions in the duodenal bulb and descending duodenum.

References

1. Hirschowitz BI: Endoscopic examination of the stomach and duodenal cap with the fiberscope. Lancet **1:** 1074–1078, 1961.
2. Shindo S, Sugaya K, Yanagisawa F: Duodenofiberscope. Gastroenterol Endosc (Japanese) **12:** 70–82, 1970.
3. Soma S, Fujita R, Kidokoro T: Clinical application of duodenofiberscope. Gastroenterol Endosc (Japanese) **12:** 97–110, 1970.
4. Ogoshi K, Tobita Y, Hara Y: Endoscopic observation of the duodenum and pancreato-choledochography using duodenal fiberscope under direct vision. Gastroenterol Endosc (Japanese) **12:** 83–96, 1970.
5. Kasugai T, Kuno N, Aoki I, et al: Fiberduodenoscopy: analysis of 353 examinations. Gastrointest Endosc **18:** 9–16, 1971.
6. Belber JP: Endoscopic examination of the duodenal bulb: a comparison with x-ray. Gastroenterology **61:** 55–61, 1971.