Case report

Intraoperative upper gastrointestinal endoscopy and biopsy

Michael V. Sivak, Jr., M.D.*

Department of Gastroenterology

Caldwell B. Esselstyn, Jr., M.D.

Department of General Surgery

Francis J. Owens, M.D.

Department of Gastroenterology

Several reports in the literature emphasize the usefulness of endoscopy during operative colonoscopy.[1, 2] The indications for colonoscopy during laparotomy are relatively well defined, and include localization of lesions and bleeding sites. There has been little reported on the use of intraoperative upper gastrointestinal endoscopy, and the indications for its use are poorly defined. Yet there are some situations in which it can be useful during the operative procedure. This paper illustrates the use of intraoperative fiberoptic examination and biopsy of the upper gastrointestinal tract.

Case report

A 79-year-old white man was admitted to the hospital with a 7-week history of progressive jaundice and pruritus associated with intermittent chills and fever. In addition he complained of nausea and vomiting and had lost 22.7 kg. He was cachectic and icteric. The gallbladder was palpable on abdominal examination, but the liver was not enlarged.

Pertinent abnormal laboratory data included a total bilirubin of 18 mg/100 ml. The blood urea nitrogen (BUN) was 40 mg/100 ml with a serum creatinine of 3.0 mg/100 ml. Contrast roentgenography of the upper gastrointestinal tract demonstrated a widened "C-loop" of the duodenum with effacement of the mucosa of the medial duodenal wall (*Fig. 1*). The clinical diagnosis was carcinoma of the pancreas.

* *Fellow, Department of Gastroenterology.*

Fig. 1. Roentgenogram showing involvement of medial duodenal wall by tumor.

Efforts were made to restore renal function, and following this the patient underwent abdominal exploration at which time a palpable mass was found in the head of the pancreas. No regional lymph nodes suggestive of metastasis could be found, nor was there any evidence of metastasis to the liver, surfaces of the peritoneum, or mesentery. The only accessible area for biopsy was the tumor itself. Duodenotomy with biopsy of the medial duodenal wall was considered. However, the risks of the additional operative procedure, including the risk of spreading the tumor, caused us to consider an endoscopic approach.

The forward viewing Olympus GIF Esophagogastroduodenoscope was passed with no difficulty by combining the techniques of direct vision passage with the aid of the anesthesiologist and laryngoscopy. The instrument was guided to the region of the duodenum opposite the tumor mass, at which point the tumor was invading the duodenal wall (*Fig. 2*). Biopsy specimens were taken and reported on frozen section as adenocarcinoma of the signet ring cell type (*Fig. 3*).

Because of the patient's age, the posterior fixation of the tumor, and his poor condition, no attempt at a curative resection was made. A cholecystojejunostomy and gastrojejunostomy were performed to relieve obstruction of the biliary and gastrointestinal systems. The patient had a prolonged gastric ileus postoperatively. At the time of discharge jaundice cleared; he had no further pruritus, nausea, or vomiting.

Discussion

The risk of pancreatic biopsy by any technique has been attested to by many surgeons.[3] Biopsy of lesions in the pancreas adds significantly to the risk of morbidity and mortality of any operative procedure. The possible complications include development of postoperative pancreatitis, pseudocysts, pancreatic fistulas, spread of tumor cells, hemorrhage, and peritonitis. Schultz and Sanders[4] reviewed the case histories of 159 patients who

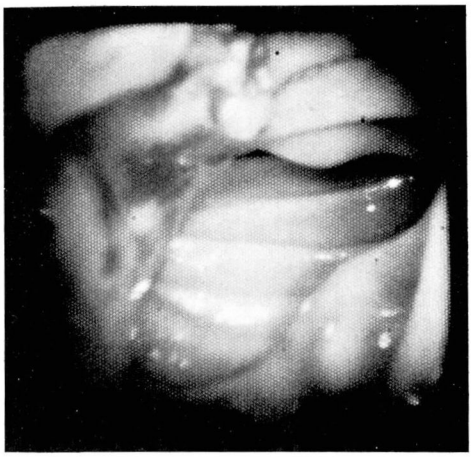

Fig. 2. Endoscopic photograph showing tumor involving duodenum.

Fig. 3. Endoscopic biopsy specimen showing normal mucosa with submucosal adenocarcinoma.

had undergone pancreatic biopsy. In their series there were six deaths (3.8%), five of which were proven at autopsy to be related to the biopsy. A sixth patient died with a clinical picture of acute pancreatitis. They also reported nine nonfatal complications in their series; an overall complication rate of 9.5%.

Nevertheless, a tissue diagnosis is often invaluable to confirm a clinical impression of a disease with a poor prognosis. In cases in which the clinical diagnosis of malignant disease of the pancreas or ampulla is uncertain or equivocal, a positive biopsy is helpful, especially if pancreaticoduodenectomy is being considered. A negative biopsy may assist in avoiding unnecessarily extensive procedures. If a previously unrecognized pancreatic tumor with duodenal involvement or tumor of the ampulla of Vater is discovered at surgery, intraoperative upper gastrointestinal endoscopy can be useful.

Summary

When it is undesirable to open the duodenum for biopsy of a periampullary lesion, or hazardous to biopsy an invading pancreatic lesion, a tissue diagnosis may be obtained quickly and easily with the fiberoptic endoscope and the assistance of the operating surgeon to guide the endoscopist to the area for biopsy. Then in many cases, opening the duodenum prior to resection or bypass procedures will not be necessary.

References

1. Espiner HJ, Salmon PR, Teague RH, et al: Operative colonoscopy. Br Med J 1: 453–454, 1973.
2. Richter RM, Littman L, Levowitz BS:

Intraoperative fiberoptic colonoscopy; localization of nonpalpable colonic lesions. Arch Surg **106:** 228, 1973.

3. Crile G Jr: The advantages of bypass operations over radical pancreatoduodenectomy in the treatment of pancreatic carcinoma. Surg Gynecol Obstet **130:** 1049–1053, 1970.
4. Schultz NJ, Sanders RJ: Evaluation of pancreatic biopsy. Ann Surg **158:** 1053–1057, 1963.