CLEVELAND CLINIC QUARTERLY
Volume 38, July 1971
Copyright © 1971 by The Cleveland Clinic Foundation
Printed in U.S.A.

Primary intraorbital meningioma

Report of a case

DOMINICK C. ADORNATO, JR., M.D.*

DONALD F. DOHN, M.D.
Department of Neurological Surgery

MENINGIOMAS comprise 14 percent of all intracranial tumors.[1] They are almost exclusively intracranial in origin and location, and only rarely arise primarily within the orbit.[2, 3] The large majority of intraorbital meningiomas are secondary, extending into the orbit from a primary intracranial site.[4]

Primary intraorbital meningiomas can be classified into two groups—those attached to the optic nerve sheath, and those not attached to the nerve sheath; those with no sheath attachment and lying outside the muscle cone are extremely rare.[2, 3] The case reported here is of a meningioma of the latter, rare type.

Report of a case

A 55-year-old, right-handed woman was examined at the Cleveland Clinic in December 1968 because of gradual protrusion of her right eye without visual impairment. Three weeks before the examination she had noticed sudden increase in the protrusion which was associated with dull, throbbing pain. There was no diplopia. In 1967 the patient had been examined by an ophthalmologist who advised surgical treatment for a suspected intraorbital tumor.

Examination. Except for the eyes, results of the neurologic examination were normal. There was proptosis and deviation of the right eye forward and downward. A firm mass was palpable between the supraorbital rim of the right orbit and the globe. The right upper lid was edematous. Eye movements were normal except for the inability to elevate the right eye. Exophthalmometer measurements were 28 mm for the right eye and 19 mm for the left eye. Visual fields, tonometry, and ophthalmoscopic findings were normal. Visual acuity was 6/15-1 in the right eye and 6/12 in the left. The pupils were 3 mm bilaterally, and round. Both the direct and consensual reflexes were intact. Convergence was normal. Lancaster red-green testing revealed paresis of the right superior rectus and inferior oblique muscles.

Skull roentgenograms showed a poorly developed right frontal sinus, widening of the right superior orbital rim, and an increase in density of the superior lateral portion of the orbital rim consistent with bony sclerosis (*Fig. 1 A and B*).

A diagnosis of right orbital tumor was made, and the patient was admitted to the ophthalmology service of the Cleveland Clinic Hospital on January 1, 1969, to undergo operation.

First operation. On January 3, 1969, the patient underwent surgery for exploration of the right orbit. Through a lid incision in the superior lateral portion of the orbit, a firm mass was found wedged between the orbital roof and the lateral wall and the globe. The

* *Fellow, Department of Neurological Surgery.*

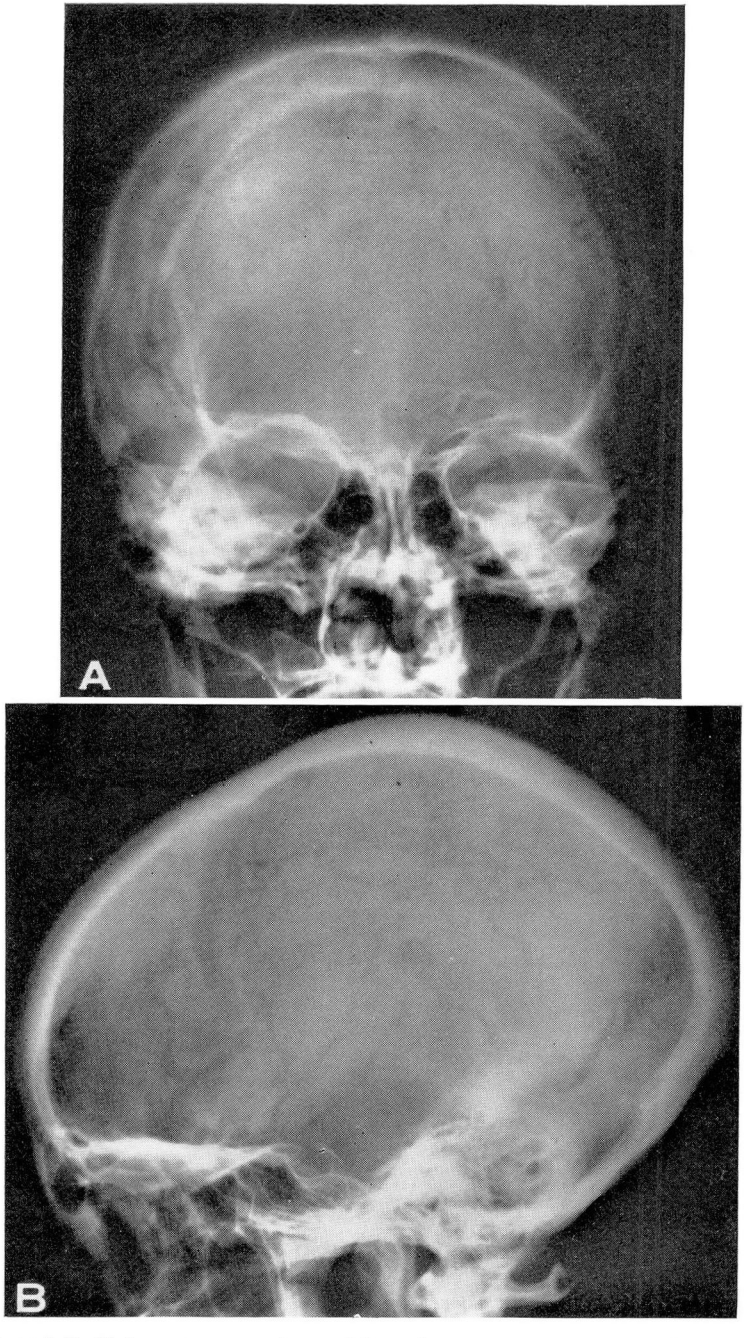

Fig. 1 A and B. Plain anteroposterior and lateral roentgenograms show the increase in density of the superior lateral portion of the right orbital roof.

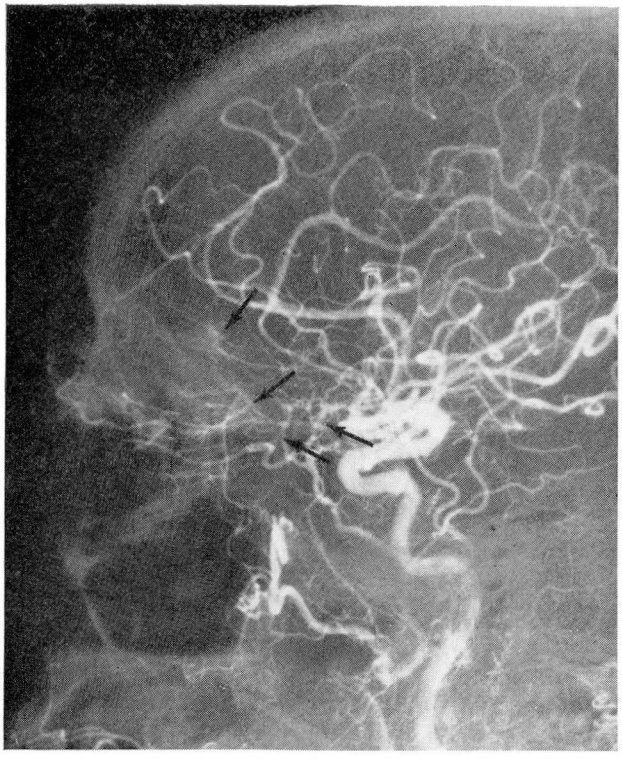

Fig. 2. Right lateral carotid angiogram demonstrates meningeal feeders (lower arrows) to tumor stain in superior portion of the orbit (upper arrow).

tumor was large and extended deeply into the orbit. Complete removal was impossible from the orbital approach. Microscopic sections were diagnosed as meningothelial meningioma.

Immediately after the operation there was almost complete ptosis of the right eye. Neurosurgical examination also showed proptosis, superior rectus and inferior oblique paresis of the right eye. A right carotid angiogram showed evidence of a downward displacement of the ophthalmic artery (*Fig. 2*). Subtraction technic demonstrated numerous hypertrophied branches of the anterior portion of the middle meningeal artery feeding the tumor area in the roof of the orbit (*Fig. 2 and 3*). The retinal stain of the posterior portion of the globe was displaced forward and downward (*Fig. 4*). No intracranial extension was noted on the angiogram. The brain scan was normal.

Second operation. On January 9, 1969, a temporary tarsorrhaphy, a right frontal craniotomy, and orbital decompression were performed. After removal of the frontal bone flap the dura was separated from the orbital plate. There was no visible tumor but the orbital plate did have a hyperostotic appearance suggestive of meningioma. A trephine was made into the lateral wall of the orbit, and the lateral and posterior walls were removed. There was considerable vascularity. Upon removing the roof of the orbit it was evident that there was a tumor arising from the supraorbital fascia. Lateral to the tumor, an incision was made into the fascia; a circumscribed mass was easily separated from the underlying orbital contents and was totally removed. The tumor was entirely outside the muscle cone, and there was no evidence of intracranial extension. The optic nerve was not involved, and all underlying orbital structures were preserved. Histologic examination showed the tumor to be a meningothelial meningioma (*Fig. 5 and 6*). Microscopic sections of the bone from the posterolateral wall of the orbit showed involvement by the meningioma (*Fig. 7*).

Fig. 3. Angiogram shows tumor stain of right orbital roof.

Postoperative course. Recovery was uneventful. On the fourth postoperative day when the tarsorrhaphy suture was removed, marked regression of the proptosis was noted, though ptosis and weakness of the superior rectus and inferior oblique muscles persisted. One month postoperatively the patient had blurred vision, and Lancaster red-green testing revealed an increase in the paresis of the right superior rectus and inferior oblique muscles as compared to results of preoperative testing. No proptosis was present, but there still was ptosis.

Four months after operation there was regression of diplopia, which disappeared when the patient tilted her head backward. The ptosis had not regressed. Eye movements were full except for the patient's inability to elevate completely the right eye.

One year postoperatively the ptosis still persisted. There was further regression of diplopia and improvement in the ability to elevate the eye; no proptosis was present; visual fields were normal.

Discussion

Probably the first report of what may have been an intraorbital meningioma was that of Scarpa in 1816 (as cited by Byers[5]). He described an intraorbital growth that had its origin within the sheath of the optic nerve. In 1874, Knapp[6] reported a case of carcinoma of the outer sheath of the optic nerve. Byers,[5] in 1901, collected reports of 102 intradural orbital tumors from the literature of the nineteenth century. Knowledge of the

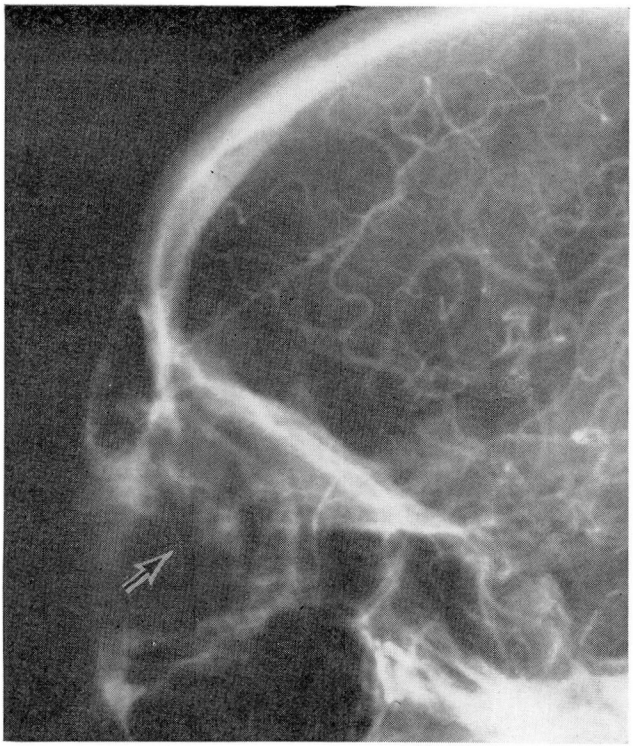

Fig. 4. Coned down view of right lateral carotid angiogram reveals retinal stain (arrow) that is displaced forward and downward.

frequency of these tumors was precluded by the then existent confusion in the histopathologic identity of various neoplasms. Parsons,[7] in 1903, suggested that some tumors were primarily extradural neoplasms of the optic nerve, arising from the sheath of Schwalbe.

In 1912, Hudson[8] grouped primary tumors of the optic nerve into three categories: gliomas, endotheliomas, and fibromas. With increasing recognition of the meningioma, reports of cases of intraorbital meningioma subsequently were reported with greater frequency.[9-17] Goar,[18] in 1926, and Mayer,[19] in 1928, calculated the total number of intraorbital meningiomas reported in the literature at approximately 40. In 1939, Schreck[20] described 15 more. Cushing and Eisenhardt[21] saw only one in their series of 313 meningiomas.

Craig and Gogela,[22] in 1949 were the first to classify intraorbital meningioma into three groups: (1) foraminal meningiomas; (2) meningiomas attached to the optic nerve sheath; and (3) meningiomas not attached to the sheath. Their group of 17 cases included three which were foraminal; nine arose from the optic sheath, and five were not attached to the sheath. Meningo-

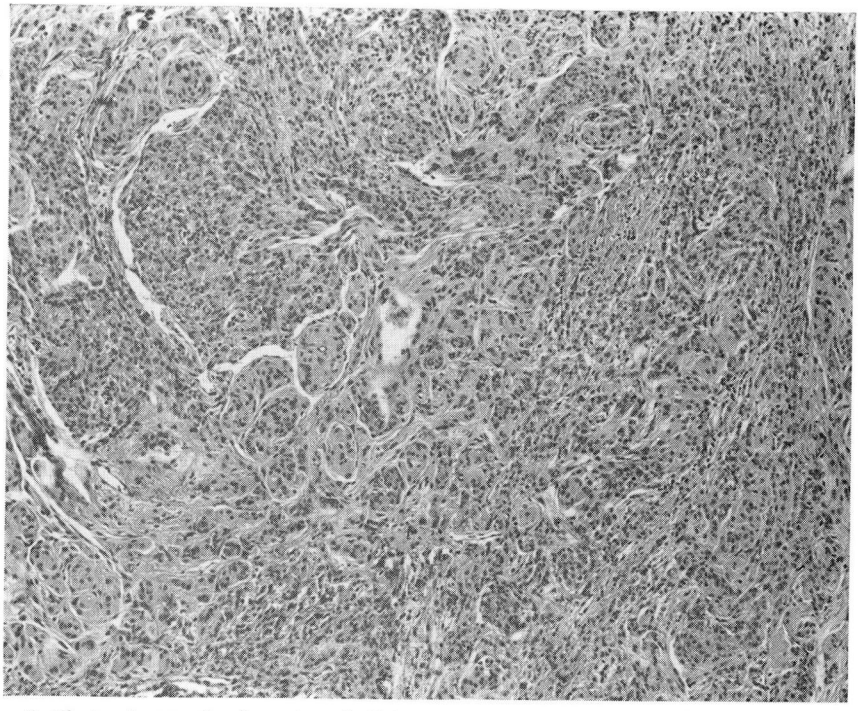

Fig. 5. Photomicrograph of meningothelial meningioma shows typical whorled pattern and sheetlike arrangement of cells. Hematoxylin-eosin stain; magnification × 80.

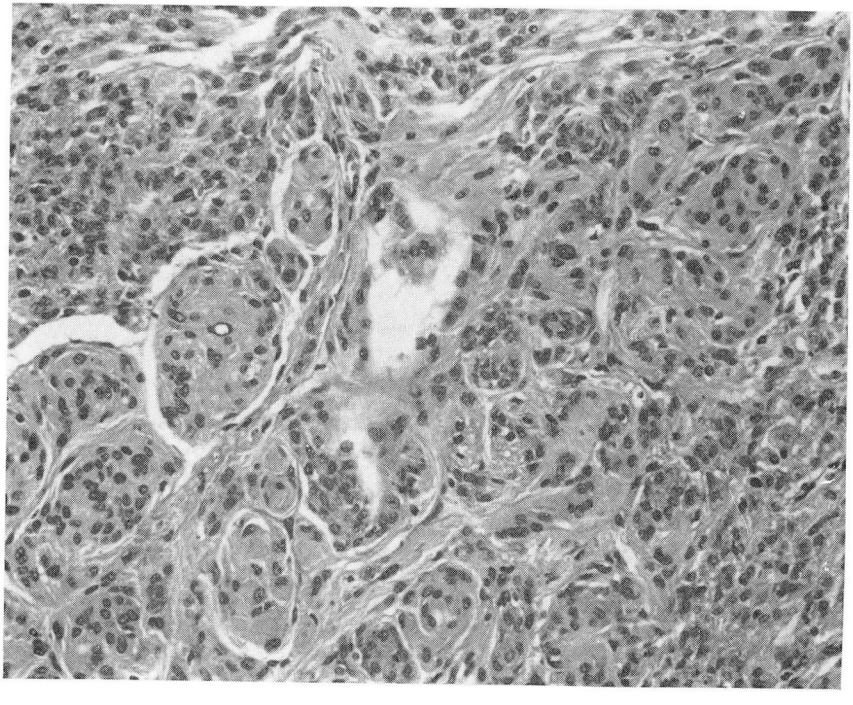

Fig. 6. Higher magnification of *Figure 5*. Hematoxylin-eosin stain; magnification × 200.

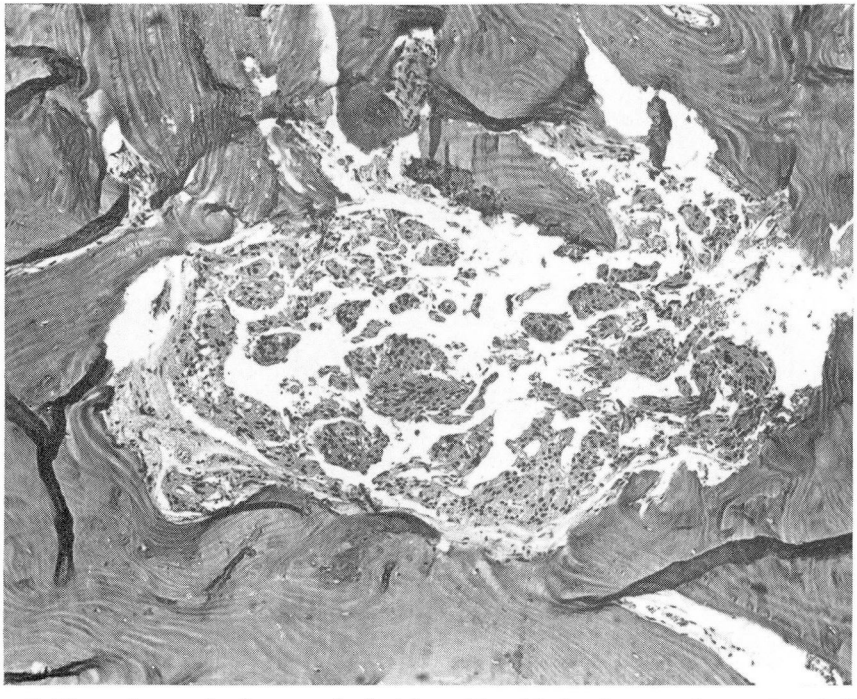

Fig. 7. Photomicrograph shows roof of right orbit with involvement by meningothelial meningioma. Hematoxylin-eosin stain; magnification × 80.

thelial meningiomas would seem to be the rarest type of intraorbital meningioma found unattached to the optic nerve sheath.[22]

A review of the literature of the last 20 years reveals 22 reports of orbital meningiomas.[2, 3, 23-42] Only three were primary intraorbital meningiomas with no attachment to the optic nerve sheath.[2, 3, 26] We believe that the case we report is the fourth one to be reported during the last 20 years. It was a rare meningothelial meningioma in that it was not attached to the optic nerve sheath.

Probably the most challenging problem of primary intraorbital meningioma is the elucidation of the site of origin. Meningiomas are thought to arise from arachnoid "cap cells" within the meninges.[22] The majority of primary intraorbital meningiomata arise from the optic nerve sheath and are therefore no exception insofar as there are arachnoid villi within the optic nerve sheath.

A meningioma with no attachment to the optic nerve sheath has a less obvious site of origin. There are four possible mechanisms: (1) the tumor was originally attached to the optic sheath but migrated away from it;[22] (2) the tumor arises from arachnoid clusters of cells either along orbital nerves or in the interstitial tissues of the orbit;[3] (3) the tumor arises from meninges that

have herniated through the sutures of the orbital bones;[43] and (4) the tumor arises from the dura lining the orbit.[2] It is possible that at least the fibroblastic type of meningioma may be derived from the periorbita. Although we cannot readily explain the site of origin of meningothelial meningiomas not attached to the optic sheath by any of the above possible mechanisms, in the present case the tumor arose from the supraorbital fascia. In this patient, it may be that arachnoid cap cells were present in the periorbital fascia. At present we can only theorize, since the pathogenesis of these tumors is still not known.

Summary

The case data of a 55-year-old woman with a primary intraorbital extradural meningothelial meningioma are reported. Surgical excision was performed and results have been satisfactory. A review of the literature is presented and the postulated methods of pathogenesis are discussed.

References

1. Russell, D. S.; Rubinstein, L. J., and Lumsden, C. E.: Pathology of Tumours of the Nervous System. 2d ed. London: Edward Arnold Ltd., 1963, p. 43.
2. Macmichael, I. M., and Cullen, J. F.: Primary intraorbital meningioma. Brit. J. Ophthal. **53:** 169–173, 1969.
3. Tan, K. K., and Lim, A. S.: Primary extradural intra-orbital meningioma in a Chinese girl. Brit. J. Ophthal. **49:** 377–380, 1965.
4. Van Buren, J. M.; Poppen, J. L., and Horrax, G.: Unilateral exophthalmos: a consideration of symptom pathogenesis. Brain **80:** 139–175, 1957.
5. Byers, W. G.: The primary intradural tumors of the optic nerve. Stud. Roy. Victoria Hosp., Montreal **1:** 1–82, 1901.
6. Knapp, H.: A case of carcinoma of the outer sheath of the optic nerve, removed with preservation of the eyeball. Arch. Ophthal. **4:** 323–354, 1874.
7. Parsons, H. J.: Primary extradural tumors of the optic nerve. Trans. Ophthal. Soc. U. K. **23:** 116–134, 1903.
8. Hudson, A. C.: Primary tumours of the optic nerve. Roy. London Ophth. Hosp. Rep. **18:** 317–439, 1912.
9. Benedict, W. L.: Tumors and cysts arising near the apex of the orbit. Amer. J. Ophthal. **6:** 183–201, 1923.
10. DeSchweinitz, G. E.: Psammosarcoma of the orbit in a girl of thirteen. Trans. Amer. Ophth. Soc. **13:** 770–777, 1914.
11. Earle, K. M., and Richany, S. F.: Meningiomas. A study of the histology, incidence and biologic behavior of 243 cases from the Frazier-Grant collection of brain tumors. Med. Ann. DC **38:** 353–356, 1969.
12. Elsberg, C. A.; Hare, C. C., and Dyke, C. G.: Unilateral exophthalmos in intracranial tumors with special reference to its occurrence in the meningiomata. Surg. Gynec. Obstet. **55:** 681–699, 1932.
13. Gilchrist, J.: Case of endothelioma of the right orbit. Trans. Ophthal. Soc. U. K. **44:** 196–197, 1924.
14. Heed, C. R.: A case of primary intradural tumor of the optic nerve. Trans. Amer. Ophthal. Soc. **14:** 331–335, 1915.

15. Mathewson, G. A.: Primary tumors of the optic nerve: report of a case. Amer. J. Ophthal. **13:** 880–883, 1930.

16. Stallard, H. B.: A case of endothelioma of the optic nerve sheaths. Brit. J. Ophthal. **19:** 576–583, 1935.

17. Thompson, H. E.: Intra-orbital meningioma (endothelioma) of the optic nerve sheath. J. Iowa Med. Soc. **25:** 347–349, 1935.

18. Goar, E. L.: Primary endothelioma of the optic nerve sheath, p. 282–285, *in* Contributions to Ophthalmic Science: Dedicated to Dr. Edward Jackson in Honor of His Seventieth Birthday, by W. H. Crisp and W. C. Finnoff. Menosha, Wis.: Banta, 1926.

19. Mayer, L. L.: Endothelioma of the orbit: report of a case. Amer. J. Ophthal. **11:** 617–622, 1928.

20. Schreck, E.: Zur Klinik und pathologischen Anatomie der Orbitaltumoren. Klin. Monatsbl. f. Augenh. **103:** 1–44, 1939.

21. Cushing, H., and Eisenhardt, L.: Meningiomas: their classification, regional behavior, life history, and surgical end results. Springfield, Ill.: Charles C Thomas, 1938, p. 238–297.

22. Craig, W. M., and Gogela, L. J.: Intraorbital meningiomas; a clinicopathologic study. Amer. J. Ophthal. **32:** 1663–1680, 1949.

23. Anastasio, J. V., and Sanjuanbenito, L.: Intraorbital calcified meningioma treated with radical extirpation. Rev. Clin. Esp. **74:** 325–327, 1959.

24. Bourgeois, L., and Jost, J.: Orbital meningioma of the osteolytic type. Ann. Oto-laryng. **72:** 810–812, 1955.

25. Crudelli, R.: Considerations on a case of meningioma of the optic foramen. Minerva neurochir. **2:** 21–22, 1958.

26. D'Alena, P.: Primary orbital meningioma. Arch. Ophthal. **71:** 832–833, 1964.

27. Dejean, C.; Gros, C.; Viallefont, H.; Boudet, C., and Boulad, L.: Intradiploic meningioma of the roof of the orbit in a child. Bull. Soc. Ophthal. Franc. **6:** 517–522, 1959.

28. Djacos, C., and Taptas, J. N.: A case of meningioma of the orbit. Arch. Ophthal. (Par.) **20:** 171–175, 1960.

29. Dunn, S. N., and Walsh, F. B.: Meningioma of the optic nerve. A.M.A. Arch. Ophthal. **56:** 702–707, 1956.

30. Edwards, T. S., and Finley, J. R.: Meningioma of the optic nerve of one month's clinical duration. Amer. J. Ophthal. **46:** 745–747, 1958.

31. Jenson, I. K.: Orbital meningioma. A monstrous case with a 30 years' history of disease. Acta Ophthal. **44:** 684–688, 1966.

32. Loiselier, F., and Bernard, P.: Two cases of meningioblastoma of the optic nerve. Bull. Soc. Ophthal. **1:** 175–177, 1959.

33. Merei, F. T.: Meningioma of the optic foramen. Zentralbl. Neurochir. **15:** 25–30, 1955.

34. Oguri, M.: A case of orbital meningioma. Folia Ophthal. Jap. **19:** 601–603, 1938.

35. Ponnarale, C., and Raznetti, E.: On a case of orbital meningioma associated with satellite sarcoidosic lymphadenitis. Minerva oftal. **6:** 130–137, 1964.

36. Razumikhina, N. P.: Meningioma of the optic nerve. Vestnik. Oftal. **34:** 27–30, 1955.

37. Ryan, H.: Intraorbital meningioma of the optic nerve. Brit. J. Ophthal. **37:** 506–507, 1953.

38. Sanders, M. D., and Falconer, M. A.: Optic nerve compression by an intracanalicular meningioma. Brit. J. Ophthal. **48:** 13–18, 1964.

39. Sempere, L. J.: Primary meningiomas of the orbit. Rev. Esp. Oto-neuro-oftal. **18:** 390–393, 1959.

40. Shrivastava, R. K.; Nahata, M. C., and Singh, R.: Orbitotemporofacial meningioma. A case report. Amer. J. Ophthal. **57:** 847–849, 1964.

41. Sood, G. C.; Malik, S. K.; Gupta, D. K., and Gupta, A. N.: Bilateral meningiomas of the orbit. Amer. J. Ophthal. **61:** 1533–1535, 1966.

42. Watson, A. G., and Greenwood, W. R.: Meningioma of the optic nerve. Canad. J. Ophthal. **3:** 181–183, 1968.

43. Kernohan, J. W., and Sayre, G. P.: Atlas of Tumor Pathology, Sect. X, Fasc. 35 and 37, Tumors of the Central Nervous System. Armed Forces Institute of Pathology, Washington, D. C., 1952.