

CME CREDIT EDUCATIONAL OBJECTIVE: Readers will suspect a variety of conditions when patients present with peripheral lymphadenopathy

HOLLEH HUSSEINZADEH, MD
Department of Translational Hematology
and Oncology, Cleveland Clinic

CLAUDIU V. COTTA, MD, PhD
Robert J. Tomsich Pathology and Laboratory
Medicine Institute, Cleveland Clinic

STEVEN GORDON, MD
Department of Infectious Disease,
Cleveland Clinic

ALAN LICHTIN, MD
Department of Hematologic
Oncology and Blood Disorders,
Cleveland Clinic

A young woman with enlarged lymph nodes

A PREVIOUSLY HEALTHY 25-YEAR-OLD WOMAN presents to her primary care physician with a “lump in the neck”—a painless, swollen area under the lower part of her left jaw that she noticed several weeks ago and that continues to enlarge. She has also noted a recent increase in fatigue, as well as the onset of generalized headaches and mild sinus congestion. Presumed by another physician to have sinusitis, she had already received a 2-week course of an antibiotic (she could not recall which antibiotic), with no improvement in her symptoms. She has been trying to lose weight and has lost 5 pounds in the last 4 months. She reports no fevers, chills, or night sweats.

She works as a special-education teacher and lives in a rural area. She has not travelled during the past year, inside or outside the United States. When she was an adolescent, she underwent tonsillectomy and had her wisdom teeth extracted. Her family has no history of hematologic dyscrasia or malignancy. She has two dogs, which are indoor pets, and she utilizes a city water supply.

1 Which of the following causes of a lump in the neck is most important to exclude?

- Viral or bacterial infection
- Lymphoma
- Oral cavity abscess
- Infectious mononucleosis
- Congenital anomaly

A lump in the neck can be broadly categorized as congenital, inflammatory, or malignant. Congenital causes include branchial cleft cyst (anterior to the sternocleidomastoid muscle)

doi:10.3949/ccjm.80a.12086

and thyroglossal duct cyst (usually in the midline between the hyoid bone and the isthmus of the thyroid gland). Other possibilities include lipoma and, less frequently, a salivary gland disorder such as sialadenitis.

A complaint of a neck lump very often correlates with the physical finding of lymphadenopathy, and a standard approach in evaluation should be undertaken, based on the mnemonic “PAAA”—ie, palpation, age, area, and associated symptoms.

Palpation. In palpation of the lymph node group, one should note the size and tactile quality of the lymph nodes and assess for abnormal temperature, tenderness, fluctuance, and mobility. In general, lymph nodes larger than 1.5 cm by 1.5 cm are more likely to be of granulomatous or neoplastic origin.¹ Nodes that are tender, warm, or fluctuant are likely reactive to a local infectious process; nodes that are firm, matted, and fixed are most characteristic of malignancy; and rubbery, mobile nodes may represent either granulomatous disease or lymphoma.²

Age helps stratify the risk of malignancy as an underlying cause, which is increased in people over age 50 presenting with lymphadenopathy.¹

Area. An assessment of the extent of the lymphadenopathy can guide the search either for a cause of generalized lymphadenopathy or for pathology in the anatomic area drained by the particular lymph node group, including the scalp (occipital or preauricular); external ear (posterior auricular); oral cavity (submandibular, submental); soft tissues of the face and neck (superficial cervical); upper respiratory tract and thyroid (deep cervical); and thoracic cavity and abdominal cavity (supraclavicular).

For swollen lymph nodes, use the mnemonic ‘PAAA’: palpation, age, area, and associated symptoms

Asking the patient about occupational, environmental, and behavioral risk factors and **associated signs and symptoms** such as fever, rash, diaphoresis, unintentional weight loss, and splenomegaly helps to narrow the differential diagnosis. Common diagnoses to consider in the evaluation of peripheral lymphadenopathy are listed in **TABLE 1**.

A viral or bacterial upper respiratory infection is one of the most common causes of cervical lymphadenopathy, although this usually does not persist for many weeks. Mononucleosis more commonly involves the posterior cervical chain and is often accompanied by splenomegaly. Because of the prolonged presence of the lump, malignancy, including lymphoma, is the most important of the answer choices to consider and rule out in a timely fashion.

■ INITIAL PHYSICAL EXAMINATION

The woman appears to be well and is in no acute distress. Her oral temperature is 98.1°F (36.7°C), blood pressure 119/72 mm Hg, heart rate 86 beats per minute, and respiratory rate 18 breaths per minute.

The head and neck appear normal. The nares are patent with normal mucosa and no visible drainage. There is no tenderness during palpation of the facial sinuses. The ear canals, tympanic membranes, oropharynx, and tongue appear normal. Several firm, mobile, nontender lymph nodes about 1 cm in diameter are palpable in the left submandibular and right supraclavicular area. No other occipital, submental, axillary, or inguinal lymphadenopathy is noted. There is no overlying erythema or warmth. The cardiac examination is normal, and the lungs are clear on auscultation. The abdomen is soft, nontender, and nondistended, with no organomegaly. The skin appears normal, and the neurologic examination is normal.

■ INITIAL LABORATORY TESTS

Results of initial laboratory tests are as follows:

- White blood cell count $5.74 \times 10^9/L$ (reference range 3.70–11.00)
- Red blood cell count $4.49 \times 10^9/L$ (3.90–5.20)

TABLE 1

Differential diagnosis of peripheral lymphadenopathy

Infections

Bacterial: sinusitis, otitis externa, cellulitis, abscess, tonsillitis, pharyngitis, cat-scratch disease
 Viral: Epstein-Barr virus, cytomegalovirus, human immunodeficiency virus, common respiratory viruses
 Fungal: sporotrichosis, cryptococcosis
 Mycobacterial: tuberculosis
 Parasitic: toxoplasmosis

Immunologic conditions

Sarcoidosis, systemic lupus erythematosus

Neoplasms

Primary hematologic malignancy: Hodgkin lymphoma, non-Hodgkin lymphoma
 Melanoma or squamous cell skin cancers
 Oropharyngeal tumor: submental, submandibular, cervical
 Upper-airway tumor: cervical, supraclavicular
 Breast cancer (axillary)
 Esophageal, lung, or intrathoracic tumor (right supraclavicular)
 Intraabdominal tumor (left supraclavicular, Virchow node)
 Inguinal tumor (vulvar or penile cancer)

Miscellaneous conditions

Castleman disease
 Histiocytic necrotizing lymphadenitis (Kikuchi-Fujimoto disease)
 Foreign body, including silicone breast implant

- Hemoglobin 13.0 g/dL (11.5–15.5)
- Hematocrit 38.4% (36.0–46.0)
- Platelet count $210 \times 10^9/L$ (150–400)
- Mean corpuscular volume 85 fL (80–100)
- Absolute neutrophil count $3.26 \times 10^9/L$ (1.45–7.50)
- Blood urea nitrogen 8 mg/dL (8–25)
- Creatinine 0.65 mg/dL (0.70–1.40)
- Lactate dehydrogenase 146 U/L (100–220)
- Uric acid 4.0 mg/dL (2.0–7.0)
- Thyrotropin (thyroid-stimulating hormone) 1.86 $\mu IU/mL$ (0.4–5.5).

A recent tuberculin skin test obtained as part of her employment screening was negative, and so was a test for antibody to human immunodeficiency virus (HIV), obtained recently before donating plasma. A urine pregnancy test done in the office was also negative. A peripheral blood smear showed slight toxic granulation with rare reactive lymphocytes.

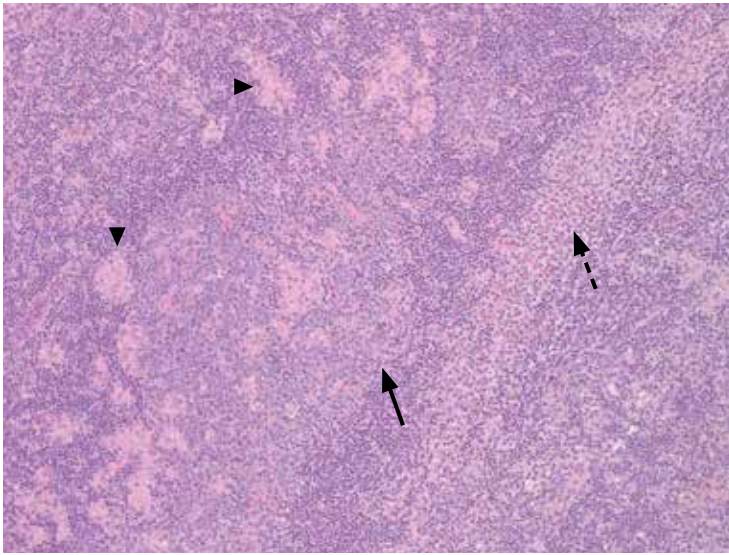


FIGURE 1. The lymph node biopsy specimen showed follicular hyperplasia (solid arrow), monocytoid B-cell hyperplasia (dashed arrow), and increased epithelioid histiocytes (arrowheads). This is a morphologic triad characteristic of *Toxoplasma gondii* lymphadenitis. There was no evidence of a clonal B-cell population or malignant neoplasm (hematoxylin and eosin, × 100).

Gardening can expose humans to oocysts in contaminated water and soil

2 Which test would provide the greatest diagnostic yield at this point?

- Needle aspiration biopsy of lymph node
- Excisional lymph node biopsy
- Polymerase chain reaction (PCR) testing for HIV
- Antistreptolysin-O (ASO) titer

Because of the persistent enlargement of the patient’s lymph nodes despite several weeks of antibiotic treatment, and because submandibular and supraclavicular nodes were involved, excisional lymph node biopsy would be the best of these choices to evaluate for malignancy. Compared with needle aspiration biopsy, it is the gold standard, preserving the nodal architecture and providing ample tissue for immunostaining and additional studies.

Needle aspiration biopsy is safe, inexpensive, and easy to do and can be useful in situations of limited resources, but it does not reliably distinguish between a reactive and a neoplastic process.¹ Its collection and interpretation are highly variable and personnel-dependent, and its sensitivity for detecting lymphoma is reported to be as low as 7.1% (95% confidence interval 0.9% to 23.5%).²

An acute retroviral syndrome can cause adenopathy, especially before seroconversion is evident, but it is usually associated with an influenza-like illness and monocytosis. Although this patient had no apparent risk factors for HIV, ordering PCR testing for HIV is also an important step when the clinical situation is suggestive. In the absence of an abnormal-appearing oropharynx, tonsillar exudate, or high fever, the pretest probability of streptococcal pharyngitis is low, and an ASO titer is unlikely to be diagnostic in this case.

■ CASE CONTINUED: BIOPSY PERFORMED

An incisional lymph node biopsy was obtained (FIGURE 1).

3 Which can confirm the suspected diagnosis?

- Tissue culture
- Test for immunoglobulin (Ig) G and IgM antibodies to *Toxoplasma gondii*
- Serum PCR testing for *T gondii*
- T gondii* IgG avidity testing

■ DIAGNOSIS OF TOXOPLASMOSIS

In this patient, acute toxoplasmosis was suspected based on recognition of the morphologic triad seen in *Toxoplasma* lymphadenitis—ie, follicular hyperplasia, abundance of monocytoid cells, and clusters of epithelioid lymphocytes.^{3,4}

Detection and measurement of IgM antibodies against *T gondii* is the most widely used serologic test for acute toxoplasmosis and is often considered the reference standard among the most common commercially available agglutination screening assays. It has a sensitivity between 93.7% and 100% and a specificity of 97.1% to 99.2%.⁵ Confirmation is generally done with enzyme-linked immunoassay or chemiluminescent-based tests, which can detect lower levels of IgG and IgM.⁵

A positive serum IgG confirms seroconversion but by itself cannot distinguish between acute and chronic infection, although it is commonly obtained in conjunction with IgM levels.⁶ Since both IgG and IgM can be elevated months after initial infection, se-

rum IgA and IgE levels can more accurately suggest the timing of infection if clarification is needed.^{6,7} In addition, IgG avidity testing can distinguish acute infection from chronic infection: a high avidity index suggests the acute infection occurred at least 3 to 5 months ago, whereas the avidity index may be low or zero if acute infection occurred within the past 4 weeks.⁷ The sensitivity of avidity testing is 91.3% to 94.4%, and the specificity 87.8% to 98.5%.⁷

Serum PCR testing for *T gondii* is useful when toxoplasmosis is suspected in patients whose immune system may not be able to mount an adequate antibody response or in patients in the hyperacute phase of infection, even before a detectable antibody response can be formed.^{8,9} However, because of limitations of equipment, expertise, and overall cost, this method is not universally available. Additionally, blood cultures and PCR testing or tissue culture of pathologic specimens cannot routinely be relied on for diagnosis, as often the burden of microorganisms present in these specimens is low. When positive, culture specimens may yield bradyzoites or tachyzoites, but only after considerable latency of many days to weeks.¹⁰

How people acquire acute toxoplasmosis

T gondii is an obligate intracellular protozoan parasite. Sexual replication of the organism takes place within the intestines of cats (the definitive host), with subsequent excretion of infective oocysts in feces.¹¹ These hardy oocysts can contaminate soil or water supplies and can survive for months, depending on ambient temperature and humidity. Ingestion of oocysts can lead to infection of a variety of mammals, including sheep, pigs, chicken, and cattle.

Infection in humans can occur with consumption of raw or undercooked foods contaminated with oocysts, and inadequate hand-washing and poor kitchen hygiene substantially increase the risk of infection.¹² Activities such as gardening can expose humans to oocysts in contaminated water and soil. In addition, direct contact with cat feces, such as when cleaning the litterbox, is a known exposure risk. Vertical transmission can manifest as congenital toxoplasmosis in a fetus when transmitted from an infected pregnant mother.

Eating raw or undercooked food is considered to be the greatest risk factor for acquired toxoplasmosis and is believed to be responsible for about 50% of all cases.¹² However, in pooled data from 14 case-control studies, no clear risk factor for *Toxoplasma* infection could be identified in up to 60% of affected people, leading many experts to believe contaminated water may play a larger role in acquisition than previously surmised.¹²

Toxoplasma cysts have a predilection for muscle and neural tissue, resulting in myositis, myocarditis, encephalitis, and chorioretinitis. Severe systemic manifestations are seen in people with impaired T-cell immunity, such as those with HIV infection and acquired immunodeficiency syndrome; or hematologic malignancy; in recipients of solid-organ transplants; or in people taking corticosteroids or cytotoxic drugs. Congenital infection can result in stillbirth, microcephaly, developmental delay, or deafness in the developing fetus and is an important cause of infant morbidity and death worldwide.¹³

Infection in immunocompetent people is usually asymptomatic.¹⁴ However, up to 20% of immunocompetent patients develop symptoms that tend to be nonspecific and include muscle aches and lymphadenopathy, and these are often mistaken for an influenza-like illness.^{14,15} Other symptoms include malaise, fevers, night sweats, pharyngitis, abdominal pain, hepatosplenomegaly, maculopapular rash, and atypical lymphocytosis (less than 10% of peripheral blood).¹¹ The most common physical manifestation of acute toxoplasmosis is isolated cervical lymphadenopathy, although any lymph node group can be affected.¹⁴ Lymph nodes are not fixed or matted and generally are neither tender nor suppurative.¹⁶

Her fatigue gradually resolved over the next year without antimicrobial treatment

4 What is the correct treatment strategy for acute toxoplasmosis in this case?

- Symptomatic treatment only
- Trimethoprim 160 mg and sulfamethoxazole 800 mg daily
- Combination of atovaquone and clindamycin
- Combination pyrimethamine, sulfadiazine, and folinic acid

TREATMENT AND PROGNOSIS OF ACUTE TOXOPLASMOSIS

No antimicrobial treatment is required for most immunocompetent patients. Symptoms are self-limited and resolve within 1 to 2 months in 60% of patients.¹⁴ A substantial proportion of patients—25%—will have lingering symptoms at 2 to 4 months, and some (10%) can have mild symptoms for 6 months or longer.¹⁶

Symptomatic treatment with analgesics such as nonsteroidal anti-inflammatory drugs (NSAIDs) is appropriate.

Immunocompromised and critically ill patients and those with ocular manifestations require combination therapy with pyrimethamine, sulfadiazine, and folinic acid.¹⁷ Trimethoprim-sulfamethoxazole is effective as prophylaxis against *T gondii* infection in immunocompromised patients at a dosage of 160 mg trimethoprim/800 mg sulfamethoxazole daily, but it is also an alternative for treatment at higher dosages (5 mg/kg trimethoprim and 25 mg/kg sulfamethoxazole twice daily).

Atovaquone and clindamycin can be used in sulfa-sensitive patients¹⁷ and also in those with latent toxoplasmosis for better penetration of tissue cysts. Corticosteroids are used as adjuncts in those with ocular involvement.

Spiramycin is the treatment of choice in

pregnant women and can be given throughout the pregnancy.^{17,18} A recent comparative study by Hotop et al¹⁸ reported a reduction in the rate of fetal transmission (1.6% vs 4.8%) when spiramycin was given from the time of diagnosis through the 16th week of pregnancy, followed by a minimum of 4 weeks of combination therapy with pyrimethamine, sulfadiazine, and folinic acid.¹⁸

CASE CONCLUDED

Serologic testing was positive for IgM and IgG antibodies to *T gondii*, which suggested subacute infection. The patient received no antimicrobial therapy and her lymphadenopathy eventually resolved. Her generalized fatigue gradually resolved over the next year without antimicrobial treatment.

A thorough re-review of potential exposures was done at subsequent office visits to help elucidate how she may have acquired the infection. She recalled no recent exposure to cats or rodents, nor consumption of raw meat. We could only suppose that there may have been inadvertent exposure to oocyst-containing soil or water or to undercooked meat products. Thus, the diagnosis of acute toxoplasmosis should be kept in mind in the evaluation of lymphadenopathy, even in the absence of a clear history of exposure. ■

REFERENCES

- Habermann TM, Steensma DP. Lymphadenopathy. *Mayo Clin Proc* 2000; 75:723–732.
- Khillan R, Sidhu G, Axiotis C, Braverman AS. Fine needle aspiration (FNA) cytology for diagnosis of cervical lymphadenopathy. *Int J Hematol* 2012; 95:282–284.
- Dorfman RF, Remington JS. Value of lymph-node biopsy in the diagnosis of acute acquired toxoplasmosis. *N Engl J Med* 1973; 289:878–881.
- Eapen M, Mathew CF, Aravindan KP. Evidence based criteria for the histopathological diagnosis of toxoplasmic lymphadenopathy. *J Clin Pathol* 2005; 58:1143–1146.
- Villard O, Cimon B, Franck J, et al; Network from the French National Reference Center for Toxoplasmosis. Evaluation of the usefulness of six commercial agglutination assays for serologic diagnosis of toxoplasmosis. *Diagn Microbiol Infect Dis* 2012; 73:231–235.
- Suzuki LA, Rocha RJ, Rossi CL. Evaluation of serological markers for the immunodiagnosis of acute acquired toxoplasmosis. *J Med Microbiol* 2001; 50:62–70.
- Lachaud L, Calas O, Picot MC, Albaba S, Bourgeois N, Pralong F. Value of 2 IgG avidity commercial tests used alone or in association to date toxoplasmosis contamination. *Diagn Microbiol Infect Dis* 2009; 64:267–274.
- Rahumatullah A, Khoo BY, Noordin R. Triplex PCR using new primers for the detection of *Toxoplasma gondii*. *Exp Parasitol* 2012; 131:231–238.
- Contini C, Giuliodori M, Cultrera R, Seraceni S. Detection of clinical-stage specific molecular *Toxoplasma gondii* gene patterns in patients with toxoplasmic lymphadenitis. *J Med Microbiol* 2006; 55:771–774.
- Silveira C, Vallochi AL, Rodrigues da Silva U, et al. *Toxoplasma gondii* in the peripheral blood of patients with acute and chronic toxoplasmosis. *Br J Ophthalmol* 2011; 95:396–400.
- Montoya JG, Liesenfeld O. Toxoplasmosis. *Lancet* 2004; 363:1965–1976.
- Petersen E, Vesco G, Villari S, Buffolano W. What do we know about risk factors for infection in humans with *Toxoplasma gondii* and how can we prevent infections? *Zoonoses Public Health* 2010; 57:8–17.
- Feldman DM, Timms D, Borgida AF. Toxoplasmosis, parvovirus, and cytomegalovirus in pregnancy. *Clin Lab Med* 2010; 30:709–720.
- Weiss LM, Dubey JP. Toxoplasmosis: a history of clinical observations. *Int J Parasitol* 2009; 39:895–901.
- Remington JS. Toxoplasmosis in the adult. *Bull NY Acad Med* 1974; 50:211–227.
- McCabe RE, Brooks RG, Dorfman RF, Remington JS. Clinical spectrum in 107 cases of toxoplasmic lymphadenopathy. *Rev Infect Dis* 1987; 9:754–774.
- Toxoplasmosis. The Medical Letter, Drugs for Parasitic Infections. New Rochelle, NY: The Medical Letter Inc, June 1, 2010:57–58.
- Hotop A, Hlobil H, Gross U. Efficacy of rapid treatment initiation following primary *Toxoplasma gondii* infection during pregnancy. *Clin Infect Dis* 2012; 54:1545–1552.

ADDRESS: Alan Lichtin, MD, Department of Hematologic Oncology and Blood Disorders, R35, Cleveland Clinic, 9500 Euclid Avenue, Cleveland, OH 44195; e-mail: lichtia@ccf.org