



DAVID L. LONGWORTH, MD, EDITOR
JAMES K. STOLLER, MD, EDITOR

KAVITA R. KOLLURI, MD

Dr. Kolluri is a fellow in the Cleveland Clinic Department of Gastroenterology. Her special areas of interest include esophageal diseases and endoscopy.

DARWIN L. CONWELL, MD

Dr. Conwell is an assistant staff member of the Cleveland Clinic Department of Gastroenterology. His special research interests include diseases of the pancreas and gastrointestinal endoscopy.

A 34-year-old woman with odynophagia and weight loss

A 34-year-old woman came to the emergency department complaining of fever, chest pain, odynophagia (pain on swallowing), and anorexia, all lasting 1 week. She had passed “dark” stools for 2 days and had lost 60 lb in the past 6 months. She denied any significant past medical history or surgeries.

Her temperature was 38.3°C and blood pressure 95/64 mm Hg. A physical examination in the emergency department disclosed nothing remarkable. An electrocardiogram was normal. Her electrolyte levels were normal, but her albumin level was 2.6 g/dL, hematocrit 30%, and mean corpuscular volume 87 fL. A plain roentgenogram of the abdomen was normal.

The patient received intravenous fluids in the observation unit and was scheduled for a gastroenterologic consultation as an outpatient. When seen in the gastroenterology clinic that week she still complained of odynophagia but denied dysphagia. She said that she had to chew food very well to avoid “sticking.” She admitted to abusing multiple substances, including alcohol, tobacco, and “crack” cocaine, but denied intravenous drug use or sexual promiscuity.

■ WHAT IS THE DIAGNOSIS?

1 On the basis of these findings, what is the most likely diagnosis?

- Gastroesophageal reflux disease
- Oral candidiasis
- Peptic ulcer disease
- Idiopathic HIV-associated esophageal ulcer
- Cytomegalovirus esophagitis

This young woman’s history of polysubstance abuse and weight loss makes human immunodeficiency virus (HIV) infection a strong possibility. In fact, a serologic test for anti-HIV antibodies was positive in this patient.

Esophageal disease is common throughout the course of HIV infection: approximately 30% of HIV-positive patients acquire it.¹ Patients usually present with dysphagia or odynophagia or both. The most common form is esophagitis due to infections with *Candida*; other infecting organisms are cytomegalovirus and herpes simplex virus.

Ulcers produce more-severe symptoms

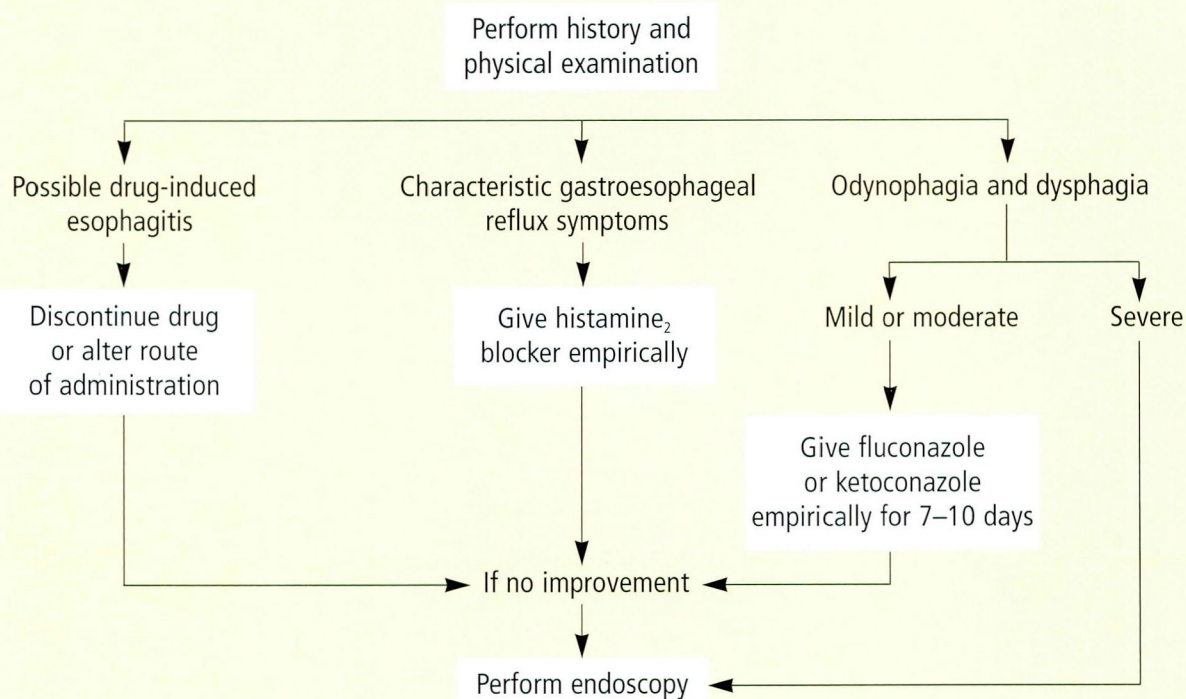
Cytomegalovirus and herpes simplex virus infections in the esophagus produce more-severe symptoms than do candidal infections because they cause ulcers, whereas *Candida* produces discrete plaques. Cytomegalovirus is much more common than herpes simplex virus as a cause of HIV-associated esophageal ulcers.¹

Medications can also cause esophageal ulcers in patients with HIV infection.² Many patients with HIV infection take ulcerogenic



FIGURE 1

SUGGESTED ALGORITHM FOR MANAGING ESOPHAGEAL SYMPTOMS IN PATIENTS WITH HIV INFECTION



From Wilcox, reference 3

medications such as zidovudine (AZT), zalcitabine (ddC), and doxycycline. However, this patient does not take any medications.

Gastroesophageal reflux disease could cause esophageal ulcers in patients with HIV infection, but it is much less likely than in uninfected persons, because HIV infection often causes gastric secretory failure and hypochlorhydria.¹

Idiopathic esophageal ulcers also occur in HIV disease, as has been recently reported.³ In fact, they may be second only to cytomegalovirus as a cause of esophageal disease in HIV-infected patients.¹ Most idiopathic ulcers are large. They most commonly afflict patients with advanced HIV disease, but can occur at any stage of the illness.

This patient's symptoms are not compati-

ble with peptic ulcers.

■ WHAT IS THE NEXT STEP?

2 What is the next step in the care of this patient?

- Barium swallow
- Upper endoscopy
- Empiric medical therapy
- Reassurance

Because the most common cause of esophageal symptoms in patients with HIV infection is candidal esophagitis,³ a patient presenting with mild esophageal symptoms could be treated empirically with fluconazole. If symptoms abate within 1 week, the diagnosis of candidal esophagitis can be pre-

sumptively; if the symptoms do not respond within 10 days, endoscopy is recommended to rule out other common causes of esophageal symptoms (FIGURE 1).

However, this patient has severe odynophagia, dehydration, and weight loss. Candidal infection does not usually cause such symptoms, but esophageal ulcers can. Esophageal ulcers are best diagnosed by endoscopy; histopathologic and cytologic examination of the ulcer determines whether it has an infectious, or idiopathic cause.

The patient therefore underwent endoscopy, which revealed a 13-cm esophageal ulcer (FIGURE 2). Biopsy specimens of the ulcer showed inflammatory changes; specimens obtained by brushing were negative for *Candida*, and no viral inclusions or malignant cells were noted. A barium esophagram also showed esophagitis and an ulcer approximately 12 to 13 cm long (FIGURE 3).

One could argue that treating heartburn empirically with histamine₂ receptor antagonists would be more cost-effective than performing endoscopy. However, as stated above, gastroesophageal reflux disease infrequently causes ulcers in HIV-infected patients.

■ WHAT TREATMENT IS INDICATED?

3 Which of the following is the appropriate therapy for this patient?

- Prednisone
- Lansoprazole
- Ketoconazole
- Observation
- Metoclopramide

Corticosteroids are the treatment of choice for idiopathic esophageal ulcers. The exact mechanism of action of these drugs is unclear, but they are thought to blunt the inflammatory process by affecting arachidonic acid metabolism through inhibition of phospholipase A₂.⁴

Wilcox and Schwartz⁵ recently compared the outcomes of patients with HIV-associated idiopathic esophageal ulcers who received prednisone for either 2 or 4 weeks. Of patients who received the 2-week regimen, 52% experienced a relapse, compared with 22% who received prednisone for 4 weeks; the difference was not statistically significant, due to the small number of patients in the study (TABLE). The most common complications of treatment were cytomegalovirus infections,

FIGURE 2

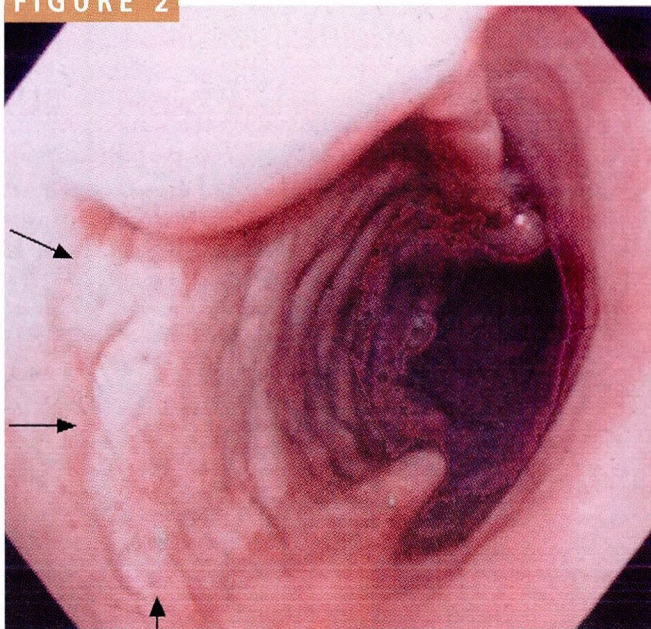


FIGURE 2. Endoscopic view of the esophagus. Arrows mark the margin of the ulcer.

FIGURE 3

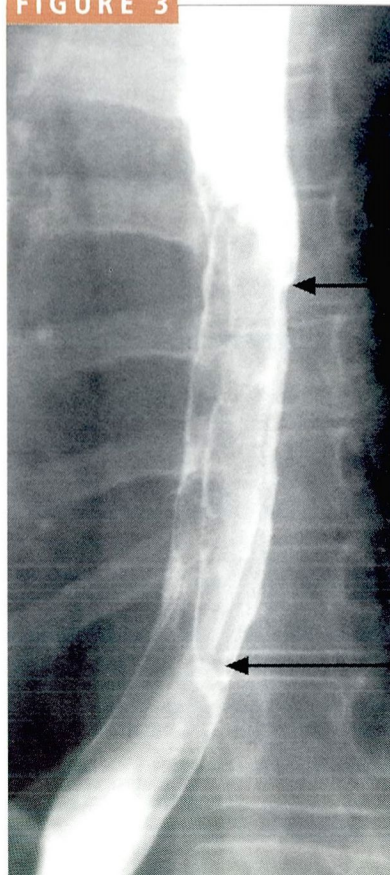


FIGURE 3. Barium esophagram. Arrows mark the top and bottom of the ulcer.



TABLE

**PREDNISONE THERAPY
FOR IDIOPATHIC HIV-RELATED
ESOPHAGEAL ULCERS**

Variable	2 weeks	4 weeks
No. of patients	12	24
Response, N (%)	11 (92)	23 (96)
None	1	1
Partial	1	5
Complete	10	18
Relapse, N (%)	2 (22)	12 (52)
Median time to relapse, weeks	6	7
Range of follow-up, months	1 to 30	1 to 28
No. lost to follow-up	1	0

None of the differences were statistically significant
From Wilcox, reference 5

**GERD rarely
causes
esophageal
ulcers in
HIV-infected
patients**

Pneumocystis carinii pneumonia, *Candida* esophagitis, and herpes simplex virus infections. It is unclear whether cytomegalovirus was missed on the original biopsy specimens or if the corticosteroid led to reactivation of latent cytomegalovirus infection. There were no deaths.

The optimal regimen that balances effica-

cy, relapse rate, and complication rate is prednisone 40 mg daily, tapered over 4 weeks. Prednisone may not alter the mortality rate, but it has shown to decrease the odynophagia, chest pain, and weight loss that occurs as a result of this condition and thereby improve the quality of life, as it did in the case of our patient.

Studies have shown a high rate of concomitant *Candida* infections in patients with idiopathic esophageal ulcers and in patients who were treated with prednisone who had relapsed.¹ Therefore, it is prudent to give fluconazole as well. Ketoconazole, which requires an acidic gastric pH to be effective, has been reported to be less effective in patients with HIV, since as many as 50% are hypochlorhydric.³ We added fluconazole to our patient's regimen.

A proton-pump inhibitor such as lansoprazole or omeprazole, or a gastric motility drug such as metoclopramide, would not help unless the patient had gastroesophageal reflux disease.

A few patients do not respond to prednisone. Two case reports describe using thalidomide in this situation with some success; however, its side effects (peripheral neuropathy and hypersensitivity) may preclude its use in this patient population until larger studies are done.^{6,7} ■

REFERENCES

1. Wilcox CM, Schwartz DA, Clark WS. Esophageal ulceration in human immunodeficiency virus infection. Causes, response to therapy, and long-term outcome. *Ann Intern Med* 1995; 123:143-149.
2. Indorf AS, Pegram PS. Esophageal ulceration related to zalcitabine (ddC). *Ann Intern Med* 1992; 117:133-134.
3. Wilcox CM. Esophageal disease in the acquired immunodeficiency syndrome: etiology, diagnosis, and management. *Am J Med* 1992; 92:412-421.
4. Kotler DP, Reka S, Orenstein JM, Fox CH. Chronic idiopathic esophageal ulceration in the acquired immunodeficiency syndrome. Characterization and treatment with corticosteroids. *J Clin Gastroenterol* 1992; 15:284-290.
5. Wilcox CM, Schwartz DA. Comparison of two corticosteroid regimens for the treatment of HIV-associated idiopathic esophageal ulcer. *Am J Gastroenterol* 1994; 89:2163-2167.
6. Ryan J, Colman J, Pedersen J. Thalidomide to treat esophageal ulcer in AIDS. *N Engl J Med* 1992; 327:208-209.
7. Naum SM, Molloy PJ, Kania RJ, McGarr J, Van Thiel DH. Use of thalidomide in treatment and maintenance of idiopathic esophageal ulcers in HIV+ individuals. *Dig Dis Sci* 1995; 40:1147-1148.

ADDRESS RERINT REQUESTS to Kavita R. Kolluri, MD, Department of Gastroenterology, S40, The Cleveland Clinic Foundation, 9500 Euclid Avenue, Cleveland, OH 44195.