

## Diagnostic approach to androgen disorders in women: acne, hirsutism, and alopecia

GEOFFREY P. REDMOND, MD AND WILMA F. BERGFELD, MD

■ The most common signs of androgen excess in women are acne, alopecia, and hirsutism. Less common manifestations include android obesity, virilization, and acanthosis nigricans. These changes appear to be the result of excessive androgen production or increased target organ sensitivity. To evaluate excessive androgen production, an androgen screening protocol is recommended that includes measurement of dehydroepiandrosterone sulfate, testosterone, androstenedione, prolactin, follicular stimulating hormone, and luteinizing hormone. When androgen excess is confirmed, dexamethasone suppression is recommended to determine the source of the androgen(s). Once excessive androgen production is confirmed, more specific therapies can be administered.

□ INDEX TERM: ANDROGENS □ CLEVE CLIN J MED 1990, 57:423-427

**E**XCESSIVE ANDROGEN activity in women causes unwanted cosmetic and physical changes, such as acne, hirsutism, alopecia, hypertrophy of the clitoris, and other manifestations of virilization (Table 1). These changes have a devastating impact on the patient's self-image, since most affected women perceive of themselves as nonfeminine or masculine, with depression and neurosis being common sequelae. Occasionally, psychosis develops.

Most of these androgen-excess manifestations begin at puberty and appear to exacerbate at menopause. They usually develop slowly and insidiously; when changes are abrupt in onset, an underlying endocrine dysfunction or tumor is likely.

Today, we have the benefit of advanced scientific technology to aid in the accurate diagnosis and treat-

ment of these complex endocrine and target organ disorders caused by androgen excess. In most cases, a few simple tests can rule out serious underlying disease and permit a rational selection of therapy. This paper, the first of two parts, reviews the clinical evaluation of subtle androgen abnormalities and current diagnostic techniques. The second part, which follows, reviews the treatment options currently available to these patients.

### CLINICAL FEATURES AND COURSE

Androgen levels rise normally in women with the onset of adolescence, and promote increased sebum and the development of axillary and pubic hair. The manifestations of excessive androgen levels in women are first evident at this time, with seborrhea, teenage acne, and the rapid growth of body hair (Figure 1).<sup>1-12</sup> Minor forms of acne are common, including comedones, milia, papules, and pustules. Cystic nodular acne develops in only a few adolescent women. It may or may not be severe, and it may persist from adolescence or have an abrupt onset later in life.

From the Departments of Endocrinology (G.P.R.) and Dermatology (W.F.B.), The Cleveland Clinic Foundation.

Address reprint requests to W.F.B., Department of Dermatology, The Cleveland Clinic Foundation, 9500 Euclid Avenue, One Clinic Center, Cleveland, Ohio 44195.

**TABLE 1**  
CUTANEOUS MANIFESTATIONS OF ANDROGEN EXCESS

Seborrhea
Acne
Hirsutism
Alopecia
Acanthosis nigricans
Android-type obesity
Clitoral hypertrophy
Virilization

### Acne

A significant number of acne patients demonstrate measurable elevations of androgens.<sup>3</sup> Therefore, an androgen screen that includes measurement of dehydroepiandrosterone sulfate (DHEAS) and testosterone is indicated in the evaluation of all forms of acne in women in order to rule out androgen excess disorders.

### Hirsutism

Localized or generalized hirsutism is an increase in terminal pigmented hair in a male hair distribution (Figures 2 and 3). Normally, growth of facial and body hair increases at puberty and progresses slowly. The abrupt onset of hirsutism after puberty indicates a need for prompt evaluation for androgen excess. Hirsutism also may develop with the approach of menopause and in the postmenopausal years.

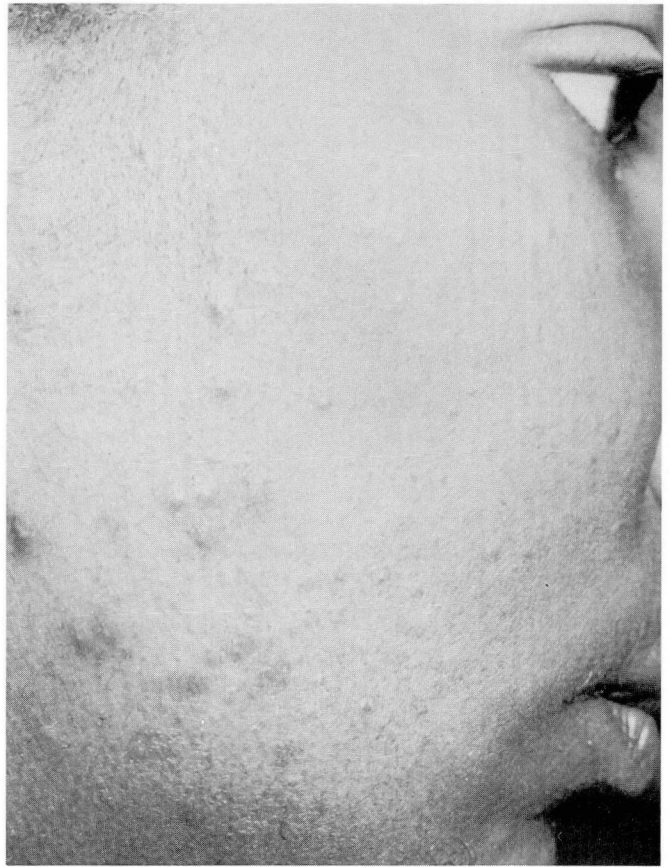
Unusual causes of hirsutism include ovarian, adrenal, or pituitary tumors. Hirsutism may be accompanied by other clinical signs of androgen excess with or without a history of menstrual irregularity, amenorrhea, infertility, and obesity.

### Alopecia

Like acne and hirsutism, alopecia may have either an insidious or abrupt onset that begins at puberty. It is frequently characterized by thinning of scalp hair, especially within the central scalp, which involves the frontal, parietal, and vertex areas. Body hair may be either excessive or decreased (Figure 4). The patient may have other clinical and laboratory evidence of androgen excess. Most women experience some degree of frontal hairline recession over time, but marked thinning of the central scalp hair with retention of the frontal hairline is most commonly associated with measurable androgen abnormalities.

### Influences of pregnancy

Acne, hirsutism, or alopecia may either improve or worsen during pregnancy. Women with androgen-



**FIGURE 1.** Hirsute female with acne. These manifestations of excessive androgen are evident at adolescence.

driven disorders frequently experience an exacerbation of their acne or alopecia 6 weeks to 3 months post-delivery. One explanation is the precipitous drop in high estrogen levels that occurs after birth.

Similar changes may occur after discontinuation of estrogen-dominant birth control pills. Both situations disrupt the stimulatory effects of estrogen excess. Increased progesterone also is associated with a drop in estrogen, and can produce hair loss.

### EVALUATING THE PATIENT

A major problem in the evaluation of female androgen excess is the lack of precise standards of normal. This causes difficulty particularly at puberty and menopause because androgens normally rise at puberty and are depressed at menopause. In both settings, clinical and laboratory evidence of androgen excess can be demonstrated.

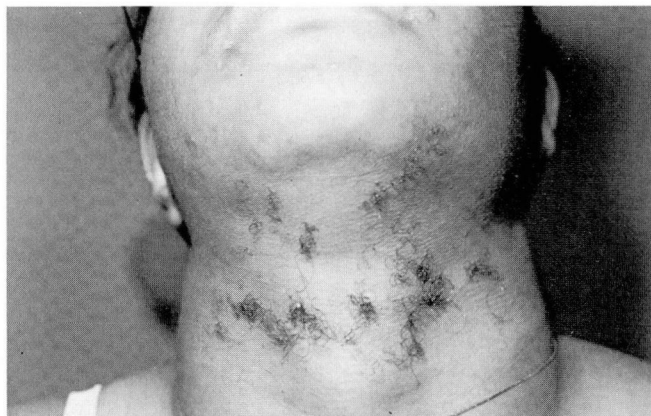

FIGURE 2. Hirsute female, face and neck.

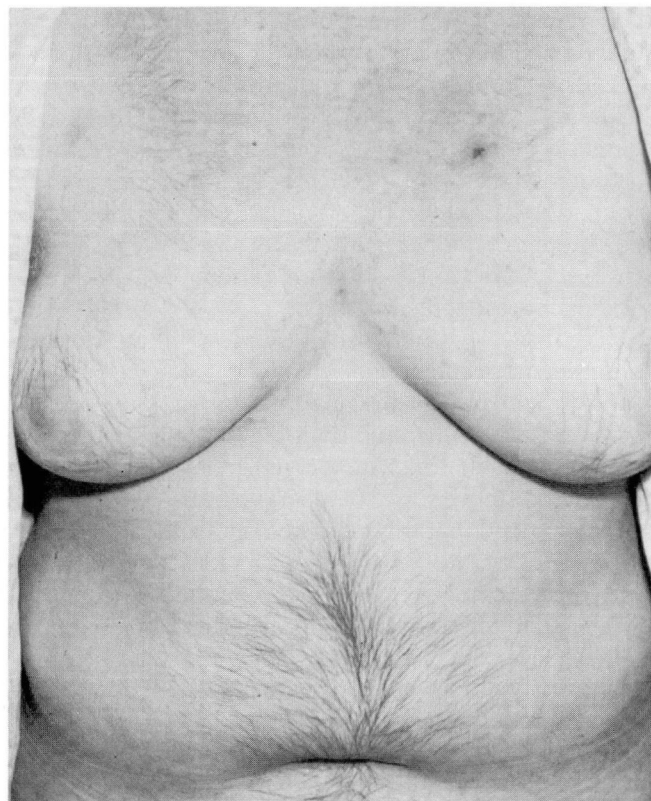


FIGURE 3. Hirsute, obese female, trunk and abdomen.

### History

Patients who have clinical evidence of androgen excess should be queried regarding the age of onset of symptoms, rate of progression, time of exacerbation, menstrual and pregnancy history, medical history, and

TABLE 2  
SOURCES OF ANDROGEN EXCESS

Adrenal
Exaggeration of normal secretion
Late-onset or congenital adrenal hyperplasia
Cushing's syndrome
Steroid- or testosterone-secreting tumors
Ovarian
Polycystic ovaries
Ovarian hyperthecosis
Tumors or hyperplasia
Luteoma pregnancy
Ovarian hilus cell hyperplasia
Ovarian stromal hyperplasia
Combined adrenal and ovarian disorders
Other
Pituitary hyperplasia or adenoma
Exogenous neoplasms
Carcinoid
Choriocarcinoma
Metastatic lung disease

medications—especially birth control methods. A family history of endocrine disorders also should be identified or ruled out.

If the patient reports a history of abrupt onset of cutaneous androgenic changes or menstrual cycle changes, an endocrine dysfunction or tumor should be suspected (Table 2). The patient who has an unevaluated menstrual abnormality should be referred for a complete endocrine work-up. Anovulation is often associated with androgen disorders. It has great clinical significance because it is an important risk factor for endometrial carcinoma.

### Physical examination

The triad of acne, hirsutism, and alopecia of course raises the index of suspicion for an androgen excess disorder. Other changes, such as acanthosis nigricans and android-type obesity, also indicate the need for a physical examination that should include a cutaneous evaluation, genital examination, and pelvic examination with special attention given to the size of the ovaries.

### Laboratory evaluation

Selection and interpretation of laboratory tests in androgenic disorders are frequent sources of confusion.<sup>13-18</sup> The most common laboratory abnormality is elevation of DHEAS and the second most common is elevated total testosterone. Less common, but still occurring in some patients, are abnormalities in free testosterone and androstenedione. A minimal, cost-effective laboratory workup, therefore, consists of measurements of total testosterone and DHEAS.

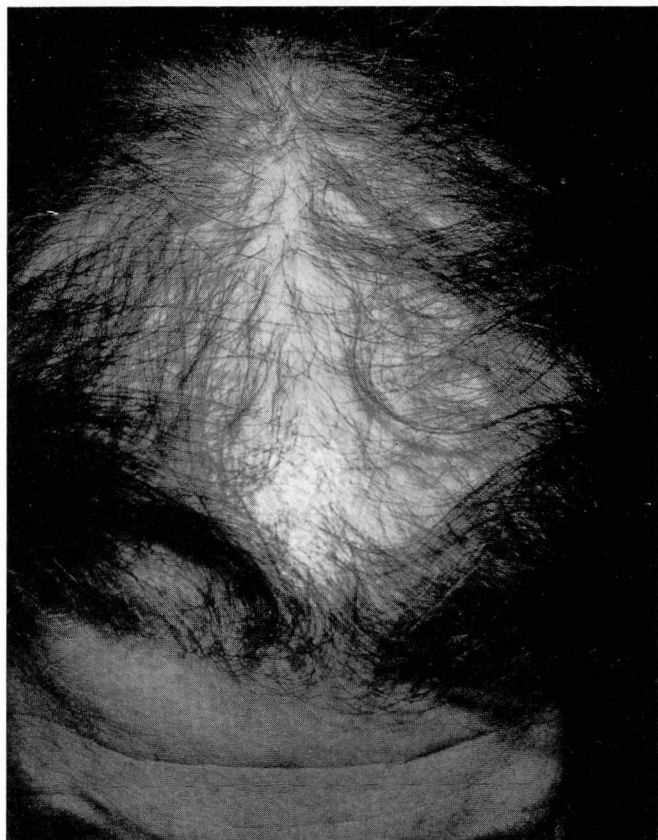


FIGURE 4. Severe androgenic alopecia in a middle-aged female.

DHEAS levels greater than 600 ng/dL and free testosterone levels above 200 ng/dL suggest a possible tumor. Elevated androgens associated with abrupt onset of clinical signs of androgen excess also suggest a tumor.

A complete laboratory profile includes measurement of luteinizing hormone (LH) and follicle-stimulating hormone (FSH), the LH to FSH ratio, and 3- $\alpha$  androstenedione glucuronide. The traditional 24-hour measurement of urinary 17-ketosteroid and 17-ketotic androgenic steroids has been replaced by serum measurements of dehydroepiandrosterone (DHEA) and DHEAS (Table 3).

In the presence of menstrual abnormalities or galactorrhea, a prolactin level should be obtained. If it is elevated, imaging studies such as computed tomography or magnetic resonance are indicated to rule out a prolactinoma. Some literature suggests that hyperprolactinemia may be a factor in hirsutism or a result of birth control pills or estrogen therapy, but this has not been our experience.

TABLE 3  
LABORATORY EVALUATION OF ANDROGEN EXCESS

Dehydroepiandrosterone sulfate
Testosterone
Androstenedione
Prolactin
Follicular-stimulating hormone
Luteinizing hormone
8-day dexamethasone suppression test

Measurement of FSH is used to rule out premature menopause.

Since hypothyroidism is an occasional cause of hair shedding and acne, measurements of  $T_4$ , thyroid-stimulating hormone, and microsomal antibodies are helpful screening tests. Iron stores, which are frequently depressed in patients with alopecia, can be screened by measurement of ferritin or percent saturated iron. Auto-immune causes can be ruled out by measurement of antinuclear factor.

There has been considerable interest in late-onset or attenuated forms of congenital adrenal hyperplasia. A marked rise in 17-hydroxyl progesterone after ACTH stimulation is diagnostic of 21-hydroxylase deficiency but, in our experience, only 2% of women with androgen excess have this condition. Therefore, this would not be a routine screening test.

Diagnosis of 11-hydroxylase deficiency requires measurement of compound S in blood or tetrahydro compound S in the urine. This measurement has limited utility because of the short serum half-life of compound S. We have been unable to locate a commercial laboratory that can measure tetrahydro compound S reliably and would not recommend that this measurement be used.

Serum assays for 17-hydroxy pregnenolone have recently become commercially available, but experience is too limited to assess their usefulness in the diagnosis of partial 3- $\beta$  hydroxyl steroid dehydrogenase deficiency.

Currently under investigation is a 24-hour urine study for steroid metabolite. The study is run by a gas chromatography technique that permits the diagnosis of a variety of enzyme defects, including increased 5- $\alpha$  reductase activity as well as adrenal hyperplasia. The test has promise for improved diagnosis of androgen excess disorders.

#### Adrenal v ovarian origin of androgens

The role of the adrenal gland relative to the ovary in producing excessive circulating levels of androgen is controversial. Several studies suggest that ACTH may stimulate ovarian androgen production<sup>17</sup> and that LH may affect

the adrenal gland.<sup>18</sup> For this reason, successful androgen suppression with dexamethasone does not rule out the ovary as a source of elevated testosterone or androstenedione. Dexamethasone is clinically useful in suppressing androgens, regardless of their anatomical source.

Dexamethasone suppression testing is indicated in women who have elevated testosterone or androstenedione. This test should be part of the workup for most women with androgenic disorders.<sup>19-21</sup>

In our dexamethasone suppression test protocol, we administer the drug in a daily dosage of 1.5 mg, divided into four 0.375-mg doses, for 8 days. Such a prolonged suppression test is necessary because the production of

adrenal androgens is suppressed more gradually than that of glucocorticoids—cortisol, for example. Since dexamethasone may restore ovulation in some women with androgenic disorders, the patient should be advised to use an effective method of birth control during a dexamethasone suppression test.

When testosterone and androstenedione are elevated, a therapeutic course of dexamethasone may help to determine the organ specificity of the androgen. DHEAS elevation is caused primarily by the adrenal gland and is easily suppressed by dexamethasone. When DHEAS is the sole androgen that is elevated, dexamethasone suppression testing is not generally needed.

#### REFERENCES

- Venning VA, Dawber RPR. Patterned androgenic alopecia in woman. *J Acad Dermatol* 1988; **18**:1073-1077.
- Bergfeld WF. Skin biopsy findings in androgenic alopecia. *Cutis* 1978; **22**:1.
- Redmond GP, Bergfeld WF, Gupta M, Parker P, Subichin S, Bedocs N, Gidwani G. Comparison of hormonal abnormalities in women with different manifestations of androgen excess. [In] Gerazzani AR, Volpe A, Facchinetti F, eds. *Research on Gynecologic Endocrinology*. Park Ridge, NJ, Parthenon Publishing Group Ltd. 1986, p 187.
- Marynick SP, Chakmakjian ZH, McCaffree DL, Herndon JH Jr. Androgen excess in cystic acne. *N Engl J Med* 1983; **308**:981-986.
- Bergfeld WF, Redmond GP. Hirsutism. *Dermatologic Clinics* 1987; **5**:501-507.
- Hatch R, Rosenfield RL, Kim MH, Tredway D. Hirsutism: implications, etiology and management. *Am J Obstet Gynecol* 1981; **140**:815-830.
- Lobo RA, Paul WL, Goehelmann U. Dehydroepiandrosterone-sulfate as an indicator of adrenal androgenic functions. *Obstet Gynecol* 1981; **59**:69-73.
- Maroulis GB. Evaluation of hirsutism and hyperandrogenemia. *Fertil Steril* 1981; **36**:273-305.
- Smith RD, Steinberger E, Perloff WH. Polycystic ovarian disease: a report of 301 patients. *Am J Obstet Gynecol* 1987; **93**:994.
- Kvedar JC, Gibson M, Krusinski PA. Hirsutism: evaluation and treatment. *J Am Acad Dermatol* 1985; **12**:215-225.
- Bergfeld WF and Redmond GP. Androgenic alopecia. *Dermatol Clin* 1987; **5**:491-500.
- Ferriman D, Gallwey JD. Clinical assessment of body hair growth in women. *J Clin Endocrinol Metab* 1961; **21**:1440-1447.
- Redmond GP, Bergfeld WF, Gupta M, Bedocs NM, Skibinski C, Gidwani G. Menstrual dysfunction in hirsute women. *J Am Acad Dermatol* 1990; **22**:76-78.
- Barbieri RL, Ryan KJ. Hyperandrogenism, insulin resistance, and acanthosis nigricans syndrome: a common endocrinopathy with distinct pathophysiological features. *Am J Obstet Gynecol* 1983; **147**:90-101.
- Kirschner MA, Samojlik E, Szmal E. Clinical usefulness of plasma androstenediol glucuronide measurements in women with idiopathic hirsutism. *J Clin Endocrinol Metab* 1987; **65**:597-601.
- Redmond GP, Bedocs N, Skibinski C, Bergfeld WF. Attenuated adrenal hyperplasia in women with androgenic disorders. [abstract] *Endocrine Society 70th Meeting Program and Abstracts* 1987, p 205.
- Kirschner MA, Jacobs JB. Combined ovarian and adrenal vein catheterization to determine the site(s) of androgen overproduction in hirsute women. *J Clin Endocrinol Metab* 1971; **33**:199-209.
- Mellis GB, Mais V, Gambacciani M, Paoletti AM, Antinori D, Fioretti P. Dexamethasone reduces the postcastration gonadotropin rise in women. *J Clin Endocrinol Metab* 1987; **65**:237-241.
- Redmond G, Gidwani G, Bergfeld WF, Skibinski C, Gupta M, Parker R, Bedocs N. Regulation of excessive androgen secretion in women: Role of ACTH responsive endocrine tissue. *Fertil Steril* 1987; **48**(suppl):83.
- Futterweit W. *Polycystic Ovarian Disease*, New York, Springer-Verlag, 1984.
- Yen SCC. Chronic Anovulation caused by peripheral endocrine disorders [In] Yen SCC and Jaffee RB, eds. *Reproductive Endocrinology*, 2nd ed. Philadelphia, Saunders, 1986, pp 441-499.