

# Empyema necessitatis: review of the manifestations of thoracic actinomycosis

THOMAS P. HOOKER, DO; MICHAEL HAMMOND, MD; KENT CORRAL, MD

■ Actinomycosis is a relatively uncommon infectious process involving the chest. A case of thoracic actinomycosis mimicking an inflammatory breast carcinoma in an elderly woman is presented with a review of the literature. The authors suggest that considering this disease in the differential diagnosis of indolent pulmonary parenchymal and pleural lesions is essential if appropriate diagnostic tests are to be obtained and proper therapy initiated, thus avoiding unnecessary invasive procedures.

□ INDEX TERMS: ACTINOMYCOSIS; EMPYEMA; THORACIC DISEASES □ CLEVE CLIN J MED 1992; 59:542-548

**A**CTINOMYCOSIS is a relatively uncommon infectious process involving the chest. We present a case of thoracic actinomycosis mimicking an inflammatory breast carcinoma in an elderly woman, followed by a review of the literature on this interesting bacterial process. Finally, the importance of considering this disease in the differential diagnosis of indolent pulmonary parenchymal and pleural lesions is discussed.

## CASE REPORT

A 62-year old white woman was admitted for evaluation of a left breast mass which was believed clinically to represent a breast carcinoma. She had complained of fatigue, malaise, and a 30-lb weight loss in the preceding 6 months. Three weeks prior to admission, she noticed swelling and tenderness of the left breast. About the same time, she developed a cough with clear sputum production, as well as subjective

fevers and chills. She had previously been employed as a housekeeper, and had smoked one pack of cigarettes per day, stopping 3 months prior to admission. On examination, the blood pressure was 100/70 mm Hg, pulse was 120 beats per minute, oral temperature was 37.5°C, and respiratory rate was 20 per minute. She appeared chronically ill, weak, and dehydrated. She had poor dentition, but there were no obvious dental abscesses. No cervical or axillary adenopathy was noted. The left breast revealed soft tissue swelling with fluctuance, erythema, and warmth over the medial aspect of the breast. The lungs were clear to auscultation and percussion. Heart examination revealed a sinus tachycardia without any gallops or murmurs. No finger clubbing was seen.

Laboratory studies revealed the following: hemoglobin, 106 g/L; platelet count, 457,000; and white blood cell count, 18,200 (with 93% polymorphonuclear leukocytes and 6% lymphocytes). Electrolytes were within normal limits. Alkaline phosphatase was elevated at 581 U/L (normal 36 to 125 U/L), and serum albumin was low at 26 g/L (normal 36 to 51 g/L). Chest roentgenography revealed an ill-defined extrapleural soft tissue density on the left, as well as right hilar fullness with a perihilar infiltrate extending to the anterior segment of the right upper lobe (*Figure 1*). Purified protein derivative and mumps skin tests were nonreactive. Sputum Gram's stain and

From the Division of Pulmonary, Critical Care, and Occupational Medicine, Department of Internal Medicine, University of South Florida College of Medicine, and James A. Haley Veterans Hospital, Tampa.

Address reprint requests to T.P.H., Section of Pulmonary and Critical Care Medicine, James A. Haley Veterans Hospital, 13000 Bruce B. Downs Blvd. (111C), Tampa, FL 33612.

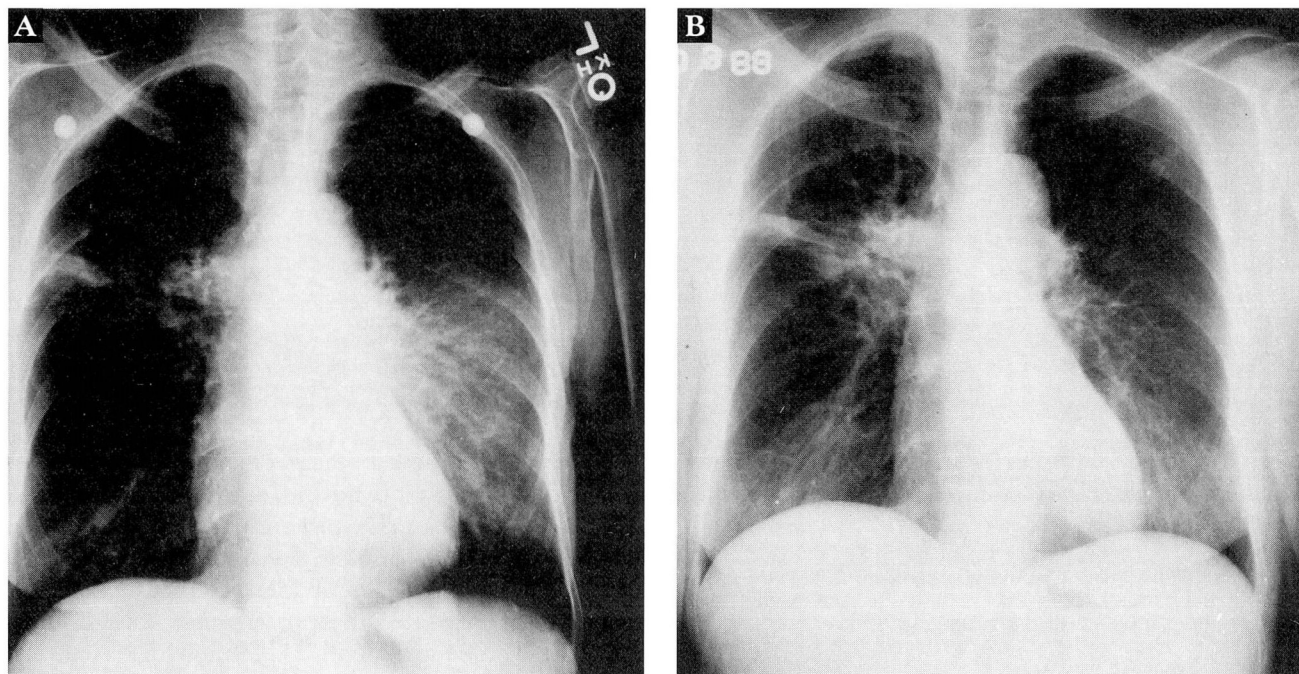


FIGURE 1. (A) Posteroanterior chest x-ray upon admission revealing an extrapleural soft tissue density on the left, right hilar fullness, and perihilar infiltrate. (B) Repeat posteroanterior chest x-ray following aspiration of 330 cc of purulent material from the left breast/chest wall.

culture revealed only normal flora. Acid-fast bacillus smear was negative, and cytology was class I. Mammography revealed a deep-seated soft tissue mass of the left breast with a fluid collection anterior and medial to it, suggesting inflammatory breast carcinoma with abscess formation. Computed tomographic scan of the chest demonstrated consolidation in the anterior segment of the right upper lobe and the superior segment of the right lower lobe, pleural thickening of both bases without effusion, and a soft tissue density over the left anterior chest wall, as well as swelling of the left breast. This process extended to the extrapleural space with evidence of early rib destruction (Figure 2).

The day following admission, 330 mL of purulent material was drained from the left breast, and cephalexin was started empirically. Gram stain of the fluid showed many polymorphonuclear leukocytes, but no microorganisms were observed. Cytology was again class I. Several days later, anaerobic cultures grew *Actinomyces odontolyticus*. At this point, cephalexin was changed to intravenous penicillin G, 12 million units per day, which continued for 6 weeks, followed by oral penicillin V potassium for a total of 1 year. In the hospital, fiberoptic bronchoscopy was performed to evaluate the right hilar fullness and rule out co-exist-

ing malignancy. No endobronchial lesions were observed, and brushings and washings of the right upper lobe were unremarkable. The patient improved dramatically with penicillin therapy, and she noted a subjective sense of well-being with less fatigue and malaise in the first month following initiation of therapy. Her left breast swelling resolved, and she regained weight (about 15 lb). Follow-up chest roentgenography 11 months after initiation of therapy revealed interval resolution of the right hilar fullness and right upper lobe infiltrate.

#### DISCUSSION

##### Historical background

Actinomycosis is an acute or chronic granulomatous disease that features the development of suppurative abscesses, sinus tracts, and eventually fibrosis and scarring.<sup>1,2</sup> It is caused by a gram-positive anaerobic bacterium that upon culture develops branching colonies resembling mycelia; hence its name *Actinomyces* or "ray fungus." It was originally classified as a fungus, due to its morphologic appearance and tendency to produce a clinical spectrum of disease resembling other fungal infections.

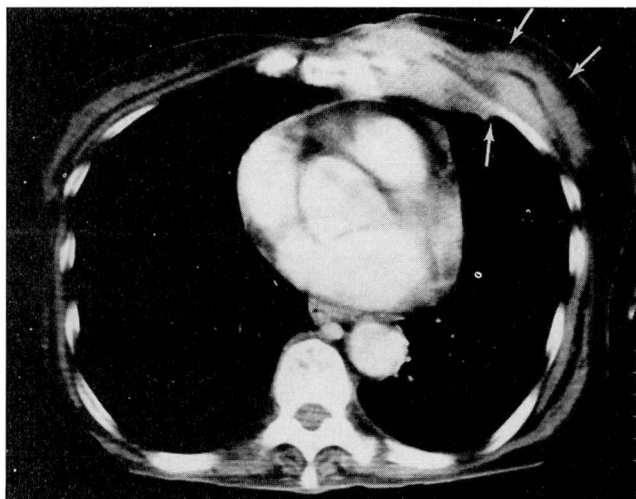


FIGURE 2. CT scan section of the chest depicting a soft tissue density over the left anterior chest wall with associated swelling of the breast. This process can be seen to extend to the pleural space (empyema necessitatis).

In 1877 Harz, a pathologist, described what he believed was a fungal infection of cattle, commonly known as "lumpy jaw," and called the organism responsible for the infection *A bovis* or "Strahlenpilz" (ray fungus). In 1878, Israël identified similar material in human necropsy specimens and, in 1885, reported a clinical series of 38 such patients. In 1882, Ponfick described the first case of thoracic actinomycosis. In 1891, the organism was cultured anaerobically by Wolf and Israël. However, it was not until 1949 that the British Medical Research Council reported that the anaerobic organism was responsible for clinical disease in humans and gave the organism the name *A israeli*.<sup>2,4</sup>

### Etiology

Several species of actinomycetes are capable of producing the clinical spectrum of actinomycosis in man: *A israeli*, *A naeslundii*, *A odontolyticus*, *Bifidobacterium eriksonii*, and *Arachnia propionicus*. Among these, *A israeli* is the organism responsible for most actinomycosis in man.<sup>5</sup> It is a common inhabitant of the mouth and gastrointestinal tract, particularly in those with poor dental hygiene.<sup>6</sup> It is also commonly found in the bronchi of those with chronic lung disease, such as bronchiectasis.<sup>7</sup> The anaerobic environment favorable for its growth is usually created by a synergistic relationship with other bacteria, eg, anaerobic *Streptococcus* and *Bacteroides* species. Only infrequently is it isolated as a sole pathogen,<sup>5-7</sup> and it should therefore

probably be considered an opportunistic pathogen which may become invasive in the setting of preceding bacterial infection or tissue injury.<sup>2</sup>

Four common forms of actinomycosis have been observed: cervicofacial disease (50% of cases), abdominal disease (30% of cases), thoracic disease (15% to 20% of cases), and cutaneous disease (usually associated with one of the three preceding types of infection).<sup>5-8</sup> Rarely, it may cause abscess formation in the brain or liver, and an osseous form of the disease can result from surrounding soft tissue infection. The mandible and vertebrae are particularly prone to this latter manifestation.<sup>9,10</sup> Males are predisposed to the disease by a 3 to 1 ratio.<sup>1,4,8</sup>

Typically, the development of invasive disease requires trauma or a preexisting lesion to initiate the infection and a favorable host environment for growth. Thus, cervicofacial disease is usually precipitated by dental caries or gingivitis; abdominal disease by peptic ulcer disease, diverticulitis, or trauma; and thoracic disease by oral aspiration.<sup>5</sup> The following discussion focusses on thoracic actinomycosis, although there is considerable overlap between the various forms of this disease.

### Pathophysiology

Thoracic actinomycosis occurs primarily by aspiration of the organism from the oropharyngeal cavity; it occurs secondarily by direct extension from areas of cervicofacial, esophageal, or abdominal involvement, or by hematogenous spread.<sup>1,2,6,7,11-13</sup>

It has generally been thought that hematogenous dissemination is a rare occurrence with actinomycosis, as pointed out in Bates' series of 85 patients, in which only 2 had evidence of dissemination. Cutaneous involvement in the form of multiple subcutaneous abscesses was formerly felt to be more consistent with *Nocardia* or fungal infection such as blastomycosis; however, recent series identifying more cases indicate that dissemination in thoracic actinomycosis may in fact be more common than thought.<sup>2,8,11,14</sup> In 1969, Graybill and Silverman reviewed seven cases of culture-proven thoracic actinomycosis in which three had hematogenous dissemination.<sup>11</sup> Varkey et al published a series of six patients with thoracic actinomycosis in 1974; three had dissemination in the form of multiple lesions involving the skin, muscle, and subcutaneous tissue.<sup>14</sup> It has been postulated that dissemination is more common with thoracic infection due to delay in diagnosing this form of the disease.

The most characteristic identifying feature of ac-

tinomycosis is its ability to spread without regard to tissue boundaries, which accounts for the various manifestations of thoracic actinomycosis. Primary infection generally begins in the bronchioles or peribronchiolar tissue following aspiration of the organism. *A israeli* produces proteolytic enzymes that account for its ability to spread by extension through contiguous segments, forming multiple abscesses that may cross fissure lines and extend to the pleura, chest wall, mediastinum, pericardium, esophagus, and vertebrae.<sup>1,2,7,8,15</sup> In its wake, it leaves signs of residual fibrosis and scarring.

### Clinical presentation

The presenting signs and symptoms of actinomycosis are nonspecific. The onset of symptoms may be acute or chronic; however, due to the low virulence of the *Actinomyces* organism, it usually presents in an indolent fashion, often with a history of waxing and waning symptoms. The patient may offer a history of transient symptomatic improvement when antibiotics are prescribed, only to relapse when therapy is discontinued.<sup>7</sup> The most frequently occurring symptoms are constitutional complaints of anorexia, weight loss, fatigue, low-grade fevers (38.3°C to 40.0°C), and sweats. These, in conjunction with complaints of cough (usually dry, but occasionally purulent), dyspnea, chest pain, and rarely hemoptysis, suggest thoracic actinomycosis.<sup>1,2,4,6-8</sup> Spread to mediastinal and cardiac structures can cause presenting signs and symptoms of congestive heart failure, acute or chronic pericarditis, and rarely acute cardiac tamponade. The disease may on rare occasions present as an obstructing tracheal or bronchial lesion, sometimes eroding through to the esophagus with a resultant tracheo-esophageal fistula; or it may present as a superior vena cava syndrome.<sup>1,2,16</sup>

Findings on physical examination that should raise the index of suspicion include poor dentition, lymphadenopathy, painful chest mass, draining fistula or sinus tracts, pulmonary osteoarthropathy, hepatosplenomegaly of 10%, and cutaneous lesions (usually described as irregular violaceous lesions).<sup>4,7,17</sup>

### Radiologic findings

The roentgenographic signs of actinomycosis are also nonspecific. Primary pulmonary actinomycosis usually presents as a pneumonic infiltrate which tends to be peripherally located, with a predilection for the lower lobes. It may be unilateral or bilateral, frequently exhibits cavitation,<sup>1,6,7,13,18,19</sup> and can also manifest as

multiple bilateral pulmonary nodules simulating metastatic lesions.<sup>20</sup> Contiguous spread to the pleura may result in pleural thickening and fibrosis, pleural effusion, or empyema.<sup>1,18</sup> If actinomycosis extends further into the chest wall, it may cause soft tissue swelling, an entity called empyema necessitatis, ie, empyema thoracis eroding through the chest wall to the subcutaneous tissues.<sup>21</sup> Chest roentgenography may also show involvement of the bones, particularly of the ribs and vertebral bodies. These radiographic findings can be confused with bronchogenic carcinoma or tuberculosis.<sup>7,13,22</sup> CT and ultrasound may be valuable in defining the characteristics that are unique to actinomycosis, particularly the relationship of pulmonary parenchymal disease to chest wall involvement.<sup>23</sup> Dershaw<sup>24</sup> described a man with a parenchymal infiltrate, empyema, and a breast mass (empyema necessitatis) similar to our case. Ultrasound demonstrated the interruption of the normal tissue planes between the chest wall abscess and the pleural space.

Despite the fact that these roentgenographic signs are nonspecific, the classic presentation of a parenchymal infiltrate with extension to the pleura and chest wall with subsequent rib erosions and waxy periostitis is nearly diagnostic of actinomycosis.<sup>1,18,21,25</sup> In general, any infiltrate or mass that crosses lobar fissures and pleural or pericardial surfaces should prompt consideration of actinomycosis in the differential diagnosis.<sup>13</sup>

### Diagnostic challenges

The clinical diagnosis of actinomycosis is difficult because of the nonspecific nature of the signs and symptoms. Actinomycosis is most commonly confused with tuberculosis or malignancy; however, other diseases that should be considered in the differential diagnosis are fungal diseases (blastomycosis, cryptococcosis, histoplasmosis, and coccidioidomycosis); malignancies (eg, lymphoma, mesothelioma); Wegener's granulomatosis; and staphylococcal sepsis.<sup>4-7,9,18</sup> The key to the diagnosis is to consider actinomycosis in the appropriate clinical setting; in other words, it should be suspected with any indolent pulmonary infiltrate, especially those that cross fissure lines, involve the pleura or chest wall, or form cutaneous sinus tracts.<sup>1</sup> Because of the low index of suspicion and difficulty in culturing the organism (due to its anaerobic growth requirements), the diagnosis is rarely made before operative intervention and surgical excision.<sup>26</sup> In Prather's series, 9 of 12 patients arrived at a diagnosis as a result of a definitive surgical proce-

ture.<sup>2</sup> However, even at the time of surgery (thoracotomy), the gross appearance may resemble carcinoma and may require histologic evaluation for certainty.

Since *Actinomyces* is a saprophyte of the oral cavity and gastrointestinal tract, culture of the organism from sputum or bronchoscopic washings alone is not diagnostic.<sup>9,22,27</sup> Kay, in 1948, cultured *Actinomyces* in 109 of 240 patients with various bronchopulmonary conditions, particularly chronic obstructive pulmonary disease and bronchiectasis.<sup>8</sup> However, in a patient with a chest roentgenograph suggestive of bronchogenic carcinoma, a positive sputum culture for *Actinomyces* should at least raise the suspicion of actinomycosis and possibly warrant a course of empiric antibiotic therapy. However, Slade et al caution that *Actinomyces* may commonly co-exist with bronchogenic carcinoma.<sup>22</sup>

### Microbiologic clues

The term "sulfur granule" originally described a macroscopic mass of bacteria resembling a granule of elemental sulfur.<sup>27,28</sup> Its definition has since been extended to include masses of bacteria surrounded by eosinophilic staining rods, both of which are encompassed by inflammatory cells and fibrinous debris on hematoxylin-eosin stain.<sup>29</sup> Actinomycetes are gram-positive filamentous branching organisms that commonly give the appearance of a sulfur granule. At higher magnification, the characteristic radiating clubs along the periphery of the granules are observed for which *Actinomyces* derived its name.<sup>28,30</sup>

Sulfur granules are generally considered diagnostic of actinomycosis but are not entirely specific. Occasionally they are seen in *Nocardia* skin infections, but they are uncommon in visceral infections.<sup>23,27,28</sup> Thus, sulfur granules associated with visceral infection are pathognomonic of actinomycosis. Subcutaneous abscesses and sinus tracts are also uncommon with *Nocardia* infections. Other bacterial and fungal skin infections which rarely exhibit sulfur granules include botryomycosis (staphylococcal skin infections), streptomycosis, aspergillosis, and coccidioidomycosis.<sup>4,11,27,30</sup>

The gram-positive filamentous branching of actinomycetes may morphologically resemble *Nocardia asteroides*, and it is essential to differentiate the two organisms, since they require different therapy.<sup>7,11</sup> Acid-fastness is a property of specimens which retain dye despite attempts to remove it with a solution of acid and alcohol; in general, actinomycetes are not acid-fast, while *Nocardia* is acid-fast.<sup>7,11,30</sup> However, by the standard Ziehl-Neelsen carbolfuchsin stain, only

*Mycobacterium tuberculosis* is consistently acid-fast, while *Nocardia* is not. By the Fite-Faraco modification (decolorization with a weaker solution of 1% sulfuric acid in water or 1% hydrochloric acid in alcohol), *Nocardia* is often acid-fast; and by the Putt modification (decolorization with a solution of 5% acetic acid in ethyl alcohol), both *Actinomyces* and *Nocardia* may be acid-fast.<sup>12,23,28</sup> Therefore, it is important to consider the details of the staining methods for correct interpretation and proper identification of these organisms.

The investigation toward a definitive diagnosis should be directed at any primary or secondary lesions observed. The definitive means of diagnosis is by culture from a site not commonly colonized with *A israeli*. However, even this procedure may be problematic because of the organism's failure to grow when cultured aerobically. Strictly speaking, *Actinomyces* is an anaerobe, although on occasion it can demonstrate microaerophilic growth potential, and this property can also be used as an aid to differentiate it from the aerobic *Nocardia* species.<sup>18,23</sup> When investigating the possibility of actinomycetes infection, specimen material should be cultured both aerobically and anaerobically for at least 14 days.<sup>12</sup>

If there are no cutaneous lesions available to provide material for culture, then more invasive means are indicated. Drainage from sinus tracts or suppurative cutaneous lesions, if present, should be evaluated initially. When radiographic pulmonary lesions are present, fiberoptic bronchoscopy will occasionally reveal an endobronchial form of actinomycosis for biopsy.<sup>31</sup> If no endobronchial lesions are observed, transbronchial or transthoracic needle aspiration of the parenchymal lesion may be performed. Histologic examination is diagnostic when it reveals sulfur granules; however, it is not uncommon to find only nonspecific inflammation with polymorphonuclear leukocytes, lymphocytes, eosinophils, histiocytes, and giant cells forming granulomas.<sup>22,23</sup> If the diagnosis remains elusive at this point, diagnostic thoracotomy is usually recommended, primarily to exclude malignancy.

### Serologic testing

The Public Health Laboratory in Liverpool, England, has recently reported serologic tests to aid in the diagnosis of actinomycosis. Elevated levels of cytoplasmic and cell wall antigens of *A israeli*, as determined by counterimmunoelectrophoresis, have been reported in several cases of actinomycosis; these levels

subsequently declined with therapy.<sup>32</sup> However, antigen levels in actinomycosis have yet to be studied in a controlled fashion.

**THERAPY**

In the pre-antibiotic era, the therapy of thoracic actinomycosis was primarily surgical—usually involving resection of the primary lesion, often with rib resection, followed by radiation therapy. However, in 1941, Dobson, Holman, and Cutting described three cases successfully treated with sulfanilamide. In 1945, they reported six cases that responded to penicillin with or without sulfonamides. Since that time, actinomycosis has changed from a uniformly fatal disease to one with a high cure rate.<sup>9</sup> Antibiotics are the mainstay of therapy today; however, surgery retains an important adjunct role for drainage of abscesses and empyemas, resection of sinus tracts and fistulas, and resection of chronically infected lung tissue that does not clear with antibiotic therapy.<sup>4,7,9</sup>

*A israeli* is sensitive to penicillin, tetracycline, chloramphenicol, erythromycin, and clindamycin. Among these, penicillin consistently has the lowest minimum inhibitory concentrations.<sup>9</sup> Actinomycetes can cause dense fibrosis in the chest, making it difficult to achieve adequate antibiotic concentrations at the site of infection. For this reason, high doses of penicillin are frequently required for prolonged periods.<sup>22</sup> Most series report therapy with intravenous penicillin G, 1 million to 20 million units per day for 3 to 6 weeks, followed by penicillin V potassium for 6 to 18 months.<sup>2,3,9,16,22,33</sup> The disseminated and thoracic forms of actinomycosis generally require a longer course of therapy than the more commonly occurring cervicofacial form.<sup>14</sup> Patients who are allergic or intolerant to penicillin may use tetracycline, erythromycin, or clindamycin as alternatives.<sup>7,26</sup>

The prognosis is now generally good for this disease. Most cases respond promptly to antibiotics, with cure rates in excess of 90% with antibiotic therapy alone.<sup>1,4,7,8</sup> Without therapy, untreated lesions will progress to necrosis, cavitation, and lung abscess. Death, when it occurs, is usually secondary to brain abscess, amyloidosis, or disseminated infection.<sup>4</sup>

**SUMMARY**

This case is unique in that its presentation simulated inflammatory breast carcinoma. A review of the literature found no similar reports other than isolated cases of anterior inflammatory chest wall or sternal lesions caused by *A israeli*.<sup>1,8,9,13,24,32,34</sup> This case illustrates some common features of thoracic actinomycosis: it is an indolent pulmonary parenchymal infection associated with constitutional symptoms and subsequent spread to the pleural space, chest wall, and subcutaneous tissue (empyema necessitatis). This case also shows that chest roentgenography and CT can suggest the diagnosis of actinomycosis by demonstrating the relationship of the pulmonary parenchymal process to the extrapleural structures, while definitive diagnosis requires culture of the organism in an anaerobic growth medium. This patient had early symptomatic improvement and a full recovery with prolonged penicillin therapy.

Considering actinomycosis in the differential diagnosis of any indolent pulmonary parenchymal, chest wall, or breast lesion makes it possible to initiate appropriate diagnostic testing and therapy, thus avoiding unnecessary invasive procedures and improving patient outcome.

**ACKNOWLEDGMENT**

The authors wish to thank Judy Hodges for her assistance in the preparation of this manuscript.

**REFERENCES**

1. Flynn MW, Felson B. The roentgen manifestations of thoracic actinomycosis. *Am J Roentgenol* 1970; **110**:707-716.
2. Prather JR, Eastridge CE, Hughes FA, McCaughan JJ. Actinomycosis of the thorax. *Ann Thorac Surg* 1970; **9**:307-312.
3. Brennan M, Morgan HJ. A puzzling pulmonary infiltrate. *J Tenn Med Assoc* 1986;(Sept):560-61.
4. Weese WC, Smith IM. A study of 57 cases of actinomycosis over a 36 year period. *Arch Intern Med* 1975; **135**:1562-1568.
5. Legum LL, Greer KE, Glessner SE. Disseminated actinomycosis. *South Med J* 1978; **71**:463-465.
6. Webb WR, Sagel SS. Actinomycosis involving the chest wall: CT findings. *Am J Roentgenol* 1982; **139**:1007-1009.
7. Balikian JP, Cheng TH, Costello P, Herman PG. Pulmonary actinomycosis. *Radiology* 1978; **128**:613-616.
8. Bates M, Cruickshank G. Thoracic actinomycosis. *Thorax* 1957; **12**:99-124.
9. McQuarrie DG, Hall WH. Actinomycosis of the lung and chest wall. *Surgery* 1968; **64**:905-911.
10. Blinkhorn RJ, Strimbu V, et al. Punch actinomycosis causing osteomyelitis of the hand. *Arch Intern Med* 1988; **148**:2668-2670.
11. Graybill JR, Silverman BD. Sulfur granules. *Arch Intern Med* 1969; **123**:430-432.
12. Smith DL, Lockwood WR. Disseminated actinomycosis. *Chest* 1975; **67**:242-244.
13. Davies AL, Messerschmidt W, et al. Thoracic actinomycosis presenting as empyema necessitatis. *Del Med J* 1987; **10**:649-657.

14. Varkey B, Landis FB, Tang TT, Rose HD. Thoracic actinomycosis. *Arch Intern Med* 1974; **134**:689-693.
15. Dorman JP, Arom KV. Pulmonary pseudotumor caused by actinomycosis. *Tex Med* 1976; **72**:65-67.
16. Maiwand O, Makey AR, Khagani A. Actinomycosis of the trachea affecting the right supraclavicular region. *Thorax* 1982; **37**:861-862.
17. Macoul K, Souliotis PT. Actinomycosis: solitary nodule. *Postgrad Med* 1967; **288**-290.
18. Coodley EL. Actinomycosis: clinical diagnosis and management. *Postgrad Med* 1969; **46**:73-78.
19. Moore WR, Scannell JG. Pulmonary actinomycosis simulating cancer of the lung. *J Thorac Cardiovasc Surg* 1968; **55**:193-195.
20. Cedermarck B, Sundblad R, Willems JS. Suspected neoplasm of the liver with pulmonary metastasis cured by surgery and penicillin. *Am J Surg* 1981; **141**:384-386.
21. Case Records of the Massachusetts General Hospital. Case 9-1967. *N Engl J Med* 1967; **276**:515-518.
22. Slade PR, Slesser BY, Southgate J. Thoracic actinomycosis. *Thorax* 1973; **28**:73-85.
23. Smith LB, Heaton CL. Actinomycosis presenting as Wegener's granulomatosis. *JAMA* 1978; **240**:247-248.
24. Dershaw DD. Actinomycosis of the chest wall: ultrasound findings in empyema necessitatis. *Chest* 1984; **86**:779-780.
25. James R, Heneghan MA, Lipansky V. Thoracic actinomycosis. *Chest* 1985; **87**:536-537.
26. Jara FM, Toledo-Pereyra LH, Magilligan DJ. Surgical implications of pulmonary actinomycosis. *J Thorac Cardiovasc Surg* 1979; **78**:600-604.
27. Varkey B. Sulfur granules. *JAMA* 1982; **248**:3025.
28. Robboy SJ, Vickery AL. Tinctorial and morphologic properties distinguishing actinomycosis and nocardiosis. *N Engl J Med* 1970; **282**:593-595.
29. Lazzari G, Vineis C, Cugini A. Cytologic diagnosis of primary pulmonary actinomycosis. *Acta Cytol* 1981; **25**:299-301.
30. Warthin TA, Busueff B. Pulmonary actinomycosis. *Arch Intern Med* 1958; **101**:239-243.
31. Louie S, Allen RP, Lillington GA. Cough with axillary calor, dolor and tumor. *Chest* 1986; **90**:761-762.
32. Wright EP, Holmberg K, Houston J, et al. Pulmonary actinomycosis simulating a bronchial neoplasm. *J Infect* 1983; **6**:179-181.
33. Eiben C, Indihar FJ, Hunter SW. Thoracic actinomycosis mimicking the pancoast tumor. *Minn Med* 1983;(Sept):541-544.
34. McCarthy MJ, Whitlock WL, Dietricj RA. A red hot sternal mass. *Chest* 1989; **96**:924-926.

