

# Immunological reversal of digitalis toxicity by Fab fragments of digoxin-specific antibodies<sup>1</sup>

Daniel M. Cooper, M.D.  
James D. Maloney, M.D.  
Lisa A. Cooper, R.N., B.S.N.  
James R. Hodgman, M.D.  
Lon W. Castle, M.D.

**Severe digitalis toxicity is associated with a high mortality. We present a case of advanced digoxin toxicity successfully treated with digoxin-specific antibody Fab fragments, and discuss its mechanism of action. A review of the pharmacokinetics of digitalis as well as the mechanisms of cardiotoxicity and its conventional treatment is presented.**

**Index terms:** Digitalis, toxicity • Immunoglobulin fragments

**Cleve Clin J Med 54:43-48, Jan/Feb 1987**

Systemic toxic effects of digitalis have been extensively described and investigated in the last quarter century. Nevertheless, 200 years after its publication, William Withering's "An Account of the Foxglove"<sup>1</sup> continues to provide the best description of digitalis toxicity. In his own words, "the foxglove, when given in very large doses,

occasions sickness, vomiting, purging, giddiness, confused vision, objects appearing green or yellow, increased secretion of urine, with frequent motions to part it, and sometimes inability to retain it; slow pulse, even as slow as 35 in a minute, cold sweats, convulsions, syncope, death."

The conventional treatment of digitalis cardiotoxicity is directed toward the control of digitalis-induced tachyarrhythmias and bradyarrhythmias, while allowing time for the elimination of digitalis from the patient. Nevertheless, cases of severe digitalis intoxication have a high mortality.<sup>2</sup>

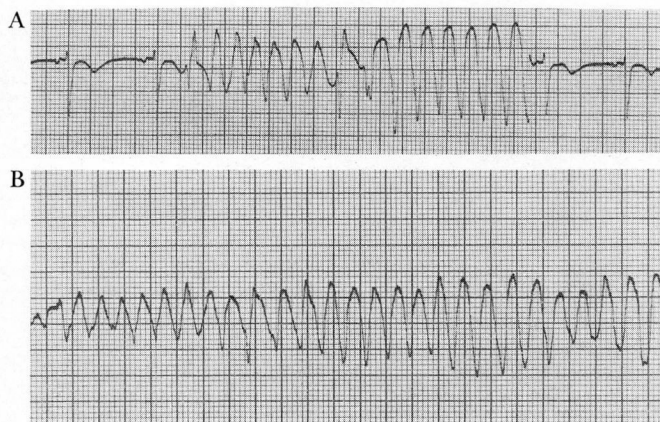
In 1976, the use of digoxin-specific antibody Fab fragments was first reported to be successful clinically in the treatment of serious digitalis toxicity.<sup>3</sup> Subsequently, a multicenter clinical trial reported in 1982<sup>4</sup> showed excellent results in 23 patients treated for digoxin intoxication and 3 patients with digitoxin intoxication. More recently, the multicenter's experience<sup>5</sup> has confirmed the initial results.

We report a patient treated successfully with digoxin-specific antibody Fab fragments for severe digoxin toxicity and discuss its mechanism of action. A review of the pharmacokinetics of

<sup>1</sup> Department of Cardiology, The Cleveland Clinic Foundation. Submitted for publication July 1986; accepted Sept 1986. lp

0891-1150/87/01/0043/06/\$2.50/0

Copyright © 1987, The Cleveland Clinic Foundation



**Fig. 1.** A. Nonsustained polymorphic ventricular tachycardia. B. Sustained polymorphic ventricular tachycardia requiring cardioversion.

digitalis as well as the mechanisms of its cardiotoxicity is presented.

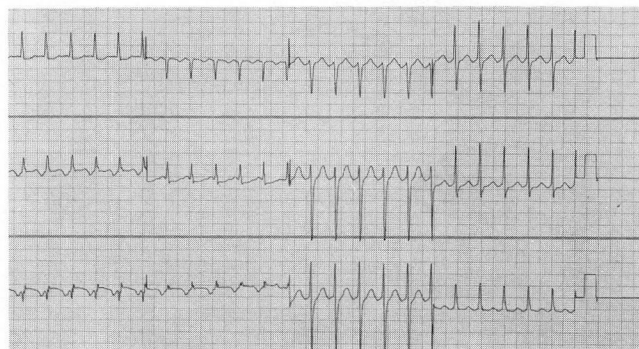
### Case report

A 55-year-old white woman with a history of drug-induced cirrhosis was admitted and a splenorenal shunt was performed. The patient's postoperative course was complicated by sepsis and oliguric renal failure. The development of atrial fibrillation with rapid ventricular response prompted the use of digoxin. Progressive renal impairment led to the development of digoxin intoxication.

The patient had sustained episodes of rapid ventricular tachycardia and recurrent episodes of ventricular fibrillation requiring several cardioversions (*Fig. 1*). She was treated with lidocaine, bretylium, and phenytoin. The serum digoxin level was 5.8 ng/mL and the serum potassium levels ranged from 5.3 to 6.2 mEq/L. The presence of a slow junctional rhythm with significant hemodynamic compromise prompted the placement of a temporary atrioventricular (AV) sequential pacemaker.

Physical examination revealed an obese white woman who was icteric, and obtunded. She was intubated and maintained on ventilatory support. Her weight was 61 kg. Her blood pressure was 105/50 mm Hg. She was being paced in DVI mode at a rate of 90 beats/min. Cardiovascular examination revealed normal first and second heart sounds, and no gallop, click, or rubs were heard. A soft systolic ejection murmur was present at the base without radiation. There was no jugular vein distension or hepatjugular reflux. The abdominal examination revealed the presence of ascites. The patient had rheumatoid nodules in the arms and around the achilles tendon in addition to deformities in her hands and feet secondary to rheumatoid arthritis.

After obtaining informed consent from the family, the patient received an intradermal skin test followed by a small intravenous testing dose. No allergic reactions were observed, and a total of 310 mg of digoxin-specific antibody Fab fragments was given intravenously over 10 minutes. There were no immediate adverse reactions.



**Fig. 2.** Nonparoxysmal junctional tachycardia at a rate of 150 beats/min.

Fifteen minutes after the Fab fragments were given, the patient's low atrial rhythm converted to a sinus rhythm. The antiarrhythmic drugs were stopped, and in the next 24 hours no further arrhythmias developed. Four hours after administration of Fab, the serum potassium level was 4.4 mEq/L despite the patient being oliguric, and remained constant during the next 24 hours without ancillary therapy. Except for one brief episode of atrial fibrillation 36 hours post-Fab with a ventricular response of about 130 beats/min, there were no further arrhythmic problems.

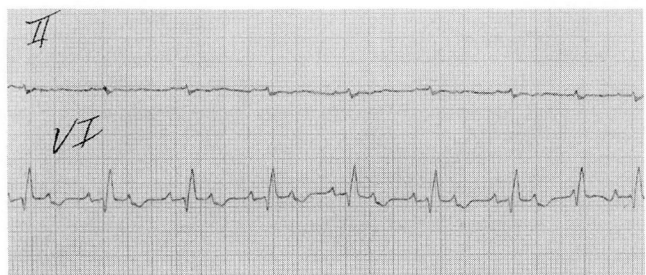
The patient died 70 hours after the administration of the Fab fragments from overwhelming septic shock. An autopsy was performed, revealing peritonitis and sepsis as the causes of death. The heart was not enlarged. There was evidence for acute fibrinous pericarditis, and a thrombus was found in the right atrium, presumably secondary to the intravenous monitoring catheters. The coronary arteries were normal.

### Discussion

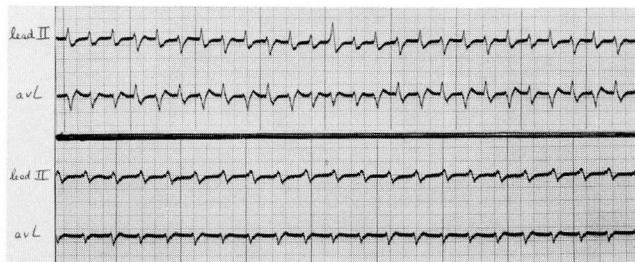
Digitalis is one of the 10 most prescribed drugs in the United States at present. Digoxin is the most frequently used cardiac glycoside in the United States.

The pharmacokinetics of digoxin is markedly different from digitoxin (*Table 1*). The bioavailability of oral digoxin averages about 70% of the equivalent intravenous dose. Digitoxin is almost completely absorbed by the normal gastrointestinal tract and 95% is bound to albumin. Only 20% of serum digoxin is protein bound. Digoxin has an elimination half-life of 36 to 48 hours, being predominantly excreted by the kidneys. Digitoxin is metabolized by the liver and has a half-life of five to seven days, which is independent of the renal function.

Digoxin toxicity remains a common problem in daily practice. It has a narrow therapeutic-toxic ratio and is subject to a variety of interac-



**Fig. 3.** Paroxysmal atrial tachycardia with block (atrial rate of 180 beats/min with varying ventricular response: 2:1 and 3:2).



**Fig. 4.** Top electrocardiographic tracing shows rhythm consistent with bidirectional ventricular tachycardia. Bottom tracing shows persistence of the primary ventricular tachycardia after intravenous phenytoin (Dilantin). The patient's QRS morphology is different from his QRS morphology during normal sinus rhythm.

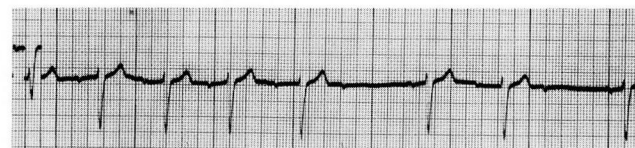
tions that may potentiate its effects, or less commonly, increase the tolerance to digitalis (Table 2).

With the advent of serum level determinations by radioimmune assay, an apparent decrease in the frequency of digitalis intoxication was observed.<sup>7</sup>

According to Fisch and Knoebel,<sup>8</sup> the classification of digitalis-induced arrhythmias, resulting from its cardiotoxicity, can be based on electrophysiologic mechanisms (Table 3). Examples of various digitalis-induced arrhythmias are shown in Figures 2-5.

The conventional treatment of digitalis cardiotoxicity is directed toward the suppression of the tachyarrhythmias and/or chronotropic support of the bradyarrhythmias, until renal elimination of digoxin or the metabolism of digitoxin decreases total body stores.

Lidocaine and phenytoin are first-line membrane-stabilizing agents to control digitalis-related ventricular arrhythmias. Potassium is helpful in treating ectopic tachyarrhythmias, but



**Fig. 5.** The rhythm strip shows evidence for both 3:2 and long-cycle Wenckebach periodicity.

should be avoided in patients who also have AV block because it can aggravate AV node conduction. Potassium should not be used in normokalemic patients in whom a massive overdose of digitalis is suspected because refractory hyperkalemia can be expected from the sodium pump inhibition.

Propranolol or verapamil can be used to treat atrial tachyarrhythmias secondary to digitalis toxicity although it may worsen sinoatrial (SA) or

**Table 1.** Pharmacokinetics of digoxin and digitoxin

Digitalis	GI absorption*	Onset of action (min)†	Peak effect (hr)†	Average half-life (controls)	Major metabolic route	Average loading dose (mg)		Usual daily oral maintenance dose (mg)§
						Oral‡	IV‡	
Digoxin	55%-75%	15-30	1½-5	36-48 hr	Renal	1-1.25	0.75-1	0.25
Digitoxin	90%-100%	25-120	4-12	4-6 days	Hepatic (enterohepatic cycle)	0.7-1.2	1	0.1

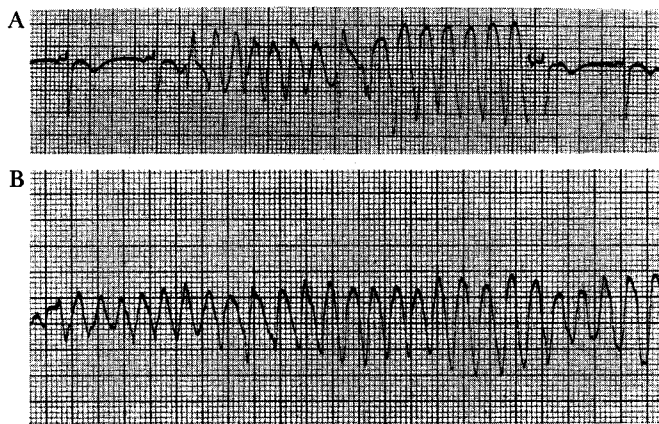
\* Lanoxicaps a digoxin solution in gel capsules marketed by Burroughs Wellcome Co. has a bioavailability of 90% to 100%. Oral dose should be reduced by 20% (Lanoxin tablets of 0.25 and 0.125 mg are approximately equivalent to Lanoxicaps of 0.2 and 0.1 mg strengths, respectively).

† Intravenous dose.

‡ Given in divided doses over a 24-hour period at six- to eight-hour intervals.

§ Average dose for an adult without renal or hepatic dysfunction (wide variation among patients, requiring close medical supervision).

Modified from Smith T.<sup>6</sup>



**Fig. 1. A.** Nonsustained polymorphic ventricular tachycardia.  
**B.** Sustained polymorphic ventricular tachycardia requiring cardioversion.

digitalis as well as the mechanisms of its cardiotoxicity is presented.

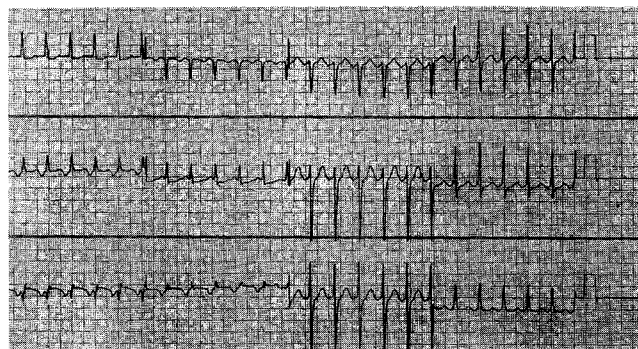
### Case report

A 55-year-old white woman with a history of drug-induced cirrhosis was admitted and a splenorenal shunt was performed. The patient's postoperative course was complicated by sepsis and oliguric renal failure. The development of atrial fibrillation with rapid ventricular response prompted the use of digoxin. Progressive renal impairment led to the development of digoxin intoxication.

The patient had sustained episodes of rapid ventricular tachycardia and recurrent episodes of ventricular fibrillation requiring several cardioversions (*Fig. 1*). She was treated with lidocaine, bretylium, and phenytoin. The serum digoxin level was 5.8 ng/mL and the serum potassium levels ranged from 5.3 to 6.2 mEq/L. The presence of a slow junctional rhythm with significant hemodynamic compromise prompted the placement of a temporary atrioventricular (AV) sequential pacemaker.

Physical examination revealed an obese white woman who was icteric, and obtunded. She was intubated and maintained on ventilatory support. Her weight was 61 kg. Her blood pressure was 105/50 mm Hg. She was being paced in DVI mode at a rate of 90 beats/min. Cardiovascular examination revealed normal first and second heart sounds, and no gallop, click, or rubs were heard. A soft systolic ejection murmur was present at the base without radiation. There was no jugular vein distension or hepatojugular reflux. The abdominal examination revealed the presence of ascites. The patient had rheumatoid nodules in the arms and around the achilles tendon in addition to deformities in her hands and feet secondary to rheumatoid arthritis.

After obtaining informed consent from the family, the patient received an intradermal skin test followed by a small intravenous testing dose. No allergic reactions were observed, and a total of 310 mg of digoxin-specific antibody Fab fragments was given intravenously over 10 minutes. There were no immediate adverse reactions.



**Fig. 2.** Nonparoxysmal junctional tachycardia at a rate of 150 beats/min.

Fifteen minutes after the Fab fragments were given, the patient's low atrial rhythm converted to a sinus rhythm. The antiarrhythmic drugs were stopped, and in the next 24 hours no further arrhythmias developed. Four hours after administration of Fab, the serum potassium level was 4.4 mEq/L despite the patient being oliguric, and remained constant during the next 24 hours without ancillary therapy. Except for one brief episode of atrial fibrillation 36 hours post-Fab with a ventricular response of about 130 beats/min, there were no further arrhythmic problems.

The patient died 70 hours after the administration of the Fab fragments from overwhelming septic shock. An autopsy was performed, revealing peritonitis and sepsis as the causes of death. The heart was not enlarged. There was evidence for acute fibrinous pericarditis, and a thrombus was found in the right atrium, presumably secondary to the intravenous monitoring catheters. The coronary arteries were normal.

### Discussion

Digitalis is one of the 10 most prescribed drugs in the United States at present. Digoxin is the most frequently used cardiac glycoside in the United States.

The pharmacokinetics of digoxin is markedly different from digitoxin (*Table 1*). The bioavailability of oral digoxin averages about 70% of the equivalent intravenous dose. Digitoxin is almost completely absorbed by the normal gastrointestinal tract and 95% is bound to albumin. Only 20% of serum digoxin is protein bound. Digoxin has an elimination half-life of 36 to 48 hours, being predominantly excreted by the kidneys. Digitoxin is metabolized by the liver and has a half-life of five to seven days, which is independent of the renal function.

Digoxin toxicity remains a common problem in daily practice. It has a narrow therapeutic-toxic ratio and is subject to a variety of interac-

**Table 2.** Factors altering sensitivity to digoxin

Drugs
Quinidine
Amiodarone, flecainide
Verapamil and other calcium blockers
Antibiotics
Laxatives
Vasodilators
Spirolactone
Myocardial disease
Respiratory disease
Hyperthyroidism
Renal function
Electrolyte disorders
Hypokalemia or hyperkalemia
Hypomagnesemia
Hyponatremia
Hypercalcemia
Acid-base imbalance
Autonomic system tone

AV node conduction. Verapamil actually increases serum digoxin level by decreasing its clearance.<sup>9</sup> Currently, type I-A drugs such as procainamide and quinidine are rarely used to

**Table 3.** Classification of digitalis-induced arrhythmias based on probable electrophysiologic mechanisms

Mechanism	Arrhythmias
Ectopic rhythms secondary to reentry and/or increased automaticity	Atrial flutter, atrial fibrillation, atrial tachycardia with block, nonparoxysmal junctional tachycardia, multifocal premature ventricular complexes, ventricular tachycardia and fibrillation, bidirectional ventricular tachycardia
"Triggered" automaticity	Accelerated junctional rhythm triggered by a premature beat or rarely by nonsustained ventricular tachycardia
Depression of intrinsic pacemakers	Sinoatrial node arrest
Depression of conduction	Sinoatrial block, AV block (1°, 2° Wenckebach type and rarely 3°)
Atrioventricular dissociation due to suppression of the dominant pacemaker with escape of an accelerated lower pacemaker	Accelerated junctional rhythm following sinus arrest

Based on the proposed classification by Fisch and Knoebel.<sup>8</sup>

treat digitalis-induced arrhythmias because they can aggravate conduction. Quinidine may worsen digitalis intoxication by raising the serum level.<sup>10</sup>

Temporary pacing can be used to treat digitalis-induced bradyarrhythmias that cause hemodynamic compromise and fail to respond to atropine.

Serious digitalis intoxication with life-threatening arrhythmias is still prevalent in patients who develop high serum levels from an overdose taken accidentally or intentionally, and in patients taking digoxin in whom a drug interaction or renal impairment ensues. Therefore, when specific digoxin antibodies were produced, their use was advocated to treat severe digitalis cardiotoxicity.

Butler and Chen<sup>11</sup> first produced digoxin antibodies in 1967. The IgG antibody is obtained by immunizing sheep with a digoxin-albumin conjugate. The 150,000 dalton antibody molecule is cleaved with papain to yield two antigen-binding fragments (Fab) and one complement-binding fragment (Fc) (Fig. 6).

In contrast to the intact IgG molecule, the Fab fragment, which is 50,000 daltons in size, has a larger volume of distribution, equilibrates more rapidly with digoxin, and is excreted by the kidneys bound to digoxin. The Fab fragment alone provokes less immunogenic response.<sup>12</sup>

The Fab fragments are dispensed in 40-mg vials in the lyophilized form, and the neutralizing dose is calculated to be approximately equimolar to the amount of digoxin or digitoxin in the patient's body.

A half-life of 16 to 20 hours for the dig-Fab complex is expected in patients with normal renal function, while the half-life in patients with severe renal insufficiency is not known.<sup>5</sup>

Following a bolus injection of Fab, the resolution of digitalis-induced arrhythmias is usually seen in 15 to 60 minutes, as observed in our patient. A clinical response in minutes has been seen in small children.<sup>13</sup> Earlier experiences with the use of slow intravenous Fab infusion resulted in a more delayed response.<sup>14</sup> Fab fragments bind to free digoxin promoting a shift of tissue-bound digoxin to the extracellular compartment, with further dig-Fab complex formation.

Hyperkalemia resulting from the inhibition of the Na<sup>+</sup> active transport by digitalis is rapidly reversed by specific Fab fragments,<sup>15</sup> even in patients with acute renal failure.

In the multicenter clinical trial reported in 1982 by Smith et al,<sup>4</sup> 26 patients with severe digitalis intoxication were treated with Fab. Of those, 21 patients recovered, and their cardiac rhythm disturbances and hyperkalemia rapidly reversed. Four patients had initial stabilization after prolonged shock and died of cerebral or myocardial hypoperfusion. One patient died of ventricular fibrillation after initial recovery from a massive ingestion of digoxin counteracted with a limited supply of Fab. No adverse reactions to the treatment were noted.

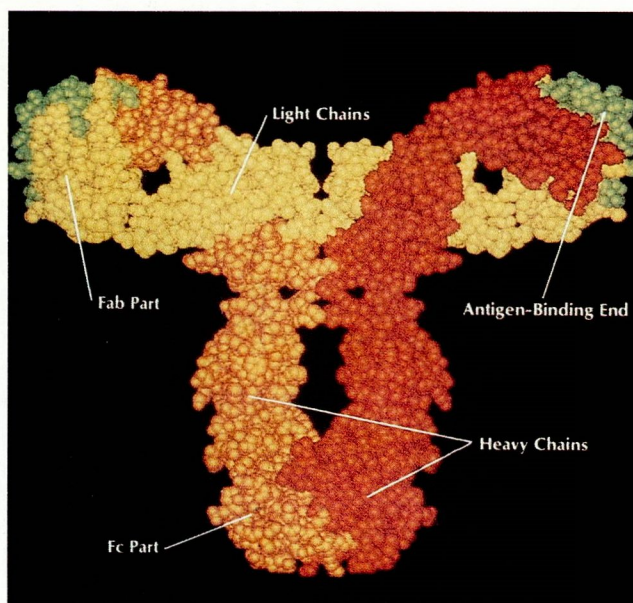
In 1985, Wenger et al<sup>5</sup> reported the multicenter experience with 63 patients treated with Fab for digitalis intoxication. In this group, 52% had ingested digitalis accidentally or as a suicidal attempt, with the remaining patients developing toxicity during treatment. Most patients had a serum digoxin concentration >5 mg/mL. Thirty-one patients had abnormal kidney function and did not have further deterioration of renal function following administration of Fab fragments.

The prolonged presence of circulating digoxin-Fab complex in patients with renal insufficiency could potentially lead to its breakdown, and reinitiation of digoxin cardiotoxicity. This scenario has been postulated<sup>16</sup> but has not been clinically observed. Similarly, a potential detrimental effect has been hypothesized regarding the rapid withdrawal of the inotropic effect of digitalis; however, this observation has been limited to animal studies<sup>17</sup> and can be clinically overcome by use of alternative inotropic therapy.

At present, Smith<sup>18</sup> considers appropriate clinical criteria for immunologic reversal of digitalis toxicity to include:

1. Actual or potentially life-threatening digitalis toxicity.
2. Conventional means of therapy are found inadequate and/or toxic exposure is judged so great that a satisfactory outcome with conventional therapy would be unlikely.
3. Skin testing should be performed to exclude immediate hypersensitivity to the heterologous Fab fragments.

The use of digoxin-specific antibody Fab fragments was restricted to investigational centers. Fab appears to be safe and has been approved by the Food and Drug Administration. It has been recently released as digoxin immune Fab (Digi-bind). Fab is of value in treating digitalis intoxication in carefully selected patients. More impor-



**Fig. 6.** Computer model of an antibody molecule shows the antigen-binding ends (Fab) and the complement-binding end (Fc). (Published with the permission of Haber E. *Antibodies in cardiovascular diagnosis and therapy*. Hosp Pract 1986; 21(2):148. Illustration by Albert Miller.)

tantly, early recognition of digitalis toxicity and prompt dosage adjustment or cessation of therapy are the key factors in the prevention of advanced digitalis intoxication.

### Acknowledgment

We are very grateful to Harry Fozzard, M.D. from the University of Chicago and Thomas Wenger, M.D. from Burroughs Wellcome for kindly providing the Digibind and their clinical advice. We also thank Ms. Bev Kane for her secretarial assistance.

### References

1. Withering W. *An Account of the Foxglove and Some of its Medical Uses*. London, Paternoster-Row, 1785, p 184.
2. Chung E. *Digitalis intoxication*. Baltimore. Williams and Wilkins Company. 42-85, 1969.
3. Smith TW, Haber E, Yeatman L, Butler VP. Reversal of advanced digoxin intoxication with Fab fragments of digoxin-specific antibodies. *N Engl J Med* 1976; **294**:797-800.
4. Smith TW, Butler VP, Haber E, et al. Treatment of life-threatening digitalis intoxication with digoxin-specific Fab antibody fragments: experience in 26 cases. *N Engl J Med* 1982; **307**:1357-1362.

5. Wenger TL, Butler VP Jr, Haber E, Smith TW. Treatment of 63 severely digitalis-toxic patients with digoxin-specific antibody fragments. *J Am Coll Cardiol* 1985; **5**:118A-123A.
6. Smith TW. Pharmacokinetics, bioavailability and serum levels of cardiac glycosides. *J Am Coll Cardiol* 1985; **5**:43A-50A.
7. Duhme DW, Greenblatt DJ, Koch-Weter J. Reduction of digoxin toxicity associated with measurements of serum levels: a report from the Boston Collaborative Drug Surveillance Program. *Ann Intern Med* 1974; **80**:516-519.
8. Fisch C, Knoebel SB. Digitalis cardiotoxicity. *J Am Coll Cardiol* 1985; **5**:91A-98A.
9. Zatuchini J. Verapamil-digoxin interaction (brief communication). *Am Heart J* 1984; **108**:412-413.
10. Leahey EB Jr, Reiffel J, Drusin R, Heissenbuttel RH, Lovejoy WP, Bigger JT Jr. Interaction between quinidine and digoxin. *JAMA* 1978; **240**:533-534.
11. Butler VP, Chen JP. Digoxin-specific antibodies. *Proc Natl Acad Sci USA* 1967; **57**:71-78.
12. Cohen SN. Antibody therapy of digoxin intoxication (commentary). *Pediatrics* 1982; **70**:494.
13. Zucker AR, Lacina SJ, DasGupta DS, et al. Fab fragments of digoxin-specific antibodies used to reverse ventricular fibrillation induced by digoxin ingestion in a child. *Pediatrics* 1982; **70**:468-471.
14. Hess T, Stucki P, Barandun S, Scholtysik G, Riesen W. Treatment of a case of lanatoside C intoxication with digoxin-specific F(ab')<sub>2</sub> antibody fragments. *Am Heart J* 1979; **98**:767-771.
15. Spiegel A, Marchlinski FE. Time course for reversal of digoxin toxicity with digoxin-specific antibody fragments. *Am Heart J* 1985; **109**:1397-1399.
16. Smith TW, Antman EM, Friedman PL, Blatt CM, Marsh JD. Digitalis glycosides: mechanisms and manifestations of toxicity (part III). *Prog Cardiovasc Dis* 1984; **27**:21-56.
17. Ochs HR, Vatner SF, Smith TW. Reversal of inotropic effects of digoxin by specific antibodies and their Fab fragments in the conscious dog. *J Pharmacol Exp Ther* 1978; **207**:64-71.
18. Smith TW. *Digitalis Glycosides*. Grune and Stratton, 1986.

James D. Maloney, M.D.  
Department of Cardiology  
The Cleveland Clinic Foundation  
9500 Euclid Ave.  
Cleveland, OH 44106