

DAVID L. LONGWORTH, MD, AND JAMES K. STOLLER, MD, EDITORS

Regurgitation in a patient with an esophageal diverticulum

A 56-year-old man presents to your office for a second opinion regarding findings on a barium esophagogram (*Figure 1*). A hiatal hernia was noted 25 years ago. Approximately 1 year ago, the patient began regurgitating undigested foods and fluids regularly. He also describes a nocturnal cough and hoarseness, but has no dysphagia after ingesting solids or liquids. His symptoms have not progressed. He has not lost any weight and does not have any other systemic symptoms. On physical examination, he appears healthy and comfortable, and no abnormalities are noted.

Q1 What is the best course of action?

- Immediate referral to a thoracic surgeon for repair of the diverticulum
- Upper endoscopy to exclude a neoplasm or a structural problem
- Esophageal manometry to exclude an accompanying motility disorder
- None of the above

Q2 Esophageal manometry was performed. A representative part of the tracing is depicted in *Figure 2*. The most likely diagnosis is:

- Normal
- Nutcracker esophagus
- Diffuse esophageal spasm
- Achalasia

This patient presents a classic dilemma, namely, the finding of an esophageal diverticulum on a roentgenogram in a patient with dysphagia and regurgitation. Intuitively, one would think that symp-

toms are related to the diverticulum. Epiphrenic diverticula are outpouchings of the distal esophagus occurring just above the lower esophageal sphincter. They are typically associated with a variety of motor disturbances of the esophagus such as achalasia (which this patient has) or diffuse esophageal spasm. Symptoms such as dysphagia, regurgitation, or chest pain are typically caused by the underlying motility disorder and not by the diverticulum. Any patient with an epiphrenic diverticulum should undergo esophageal manometry to help define if an underlying motor disorder is present.

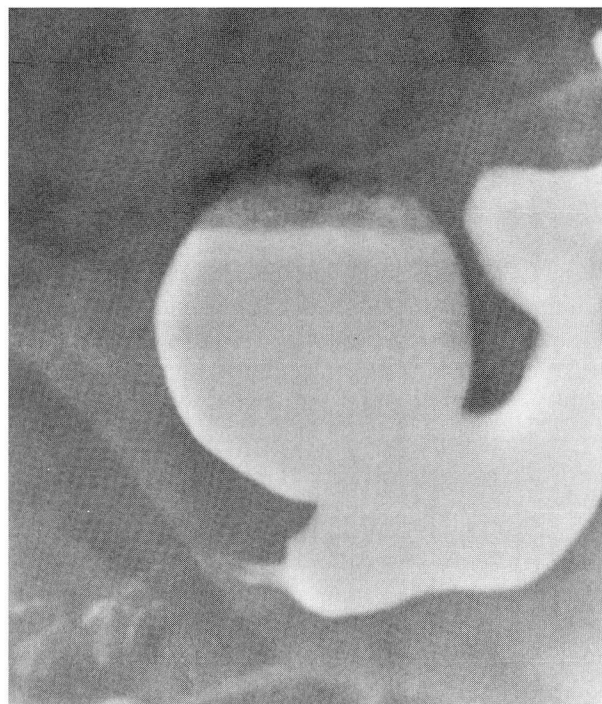


FIGURE 1. Barium esophagogram demonstrating a large epiphrenic diverticulum.

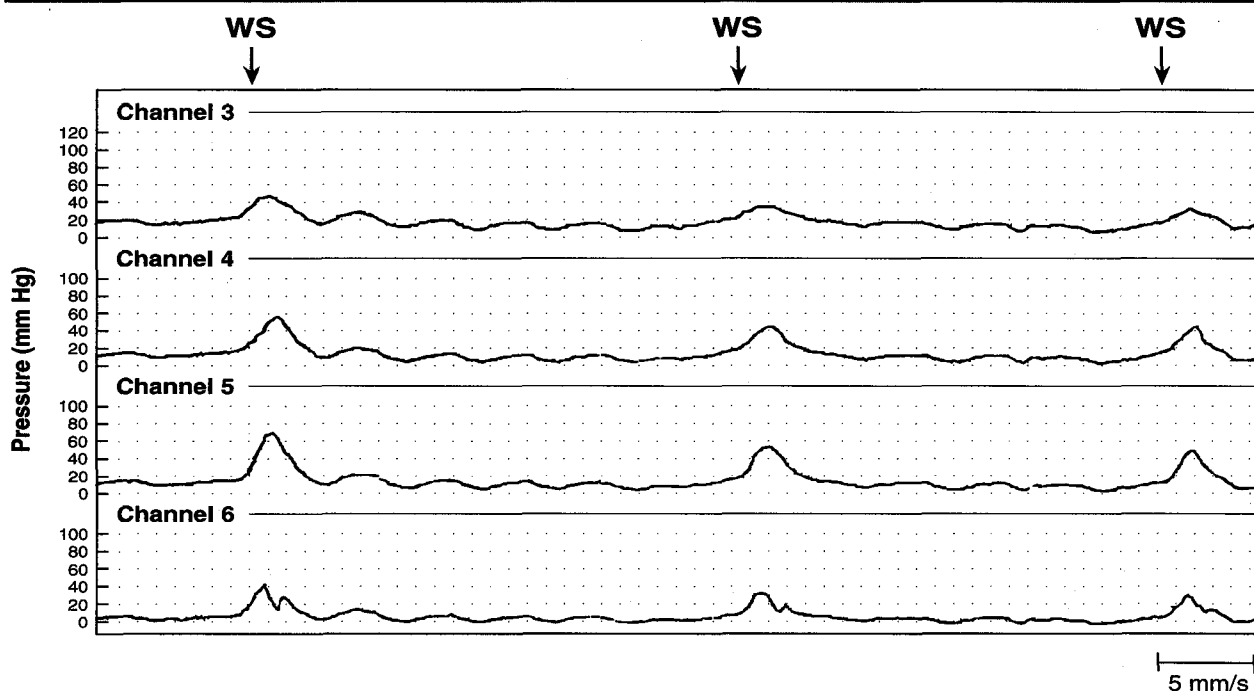


FIGURE 2. Esophageal manometric tracing demonstrating aperistalsis. WS indicates swallow after a 5 mL bolus of water. Channels 3, 4, 5, and 6 are located 18, 13, 8, and 3 cm above the lower esophageal sphincter, respectively.

Achalasia is the classic primary esophageal motility disorder. It is characterized by the absence of normal esophageal peristalsis (Figure 2), accompanied by a failure of the lower esophageal sphincter to relax completely. The cause of achalasia remains unclear. A number of intriguing abnormalities have been described, including the loss of ganglion cells in the esophagus, degenerative changes of the vagus nerve, changes in the structure of the brain-stem dorsal motor nucleus, and a decrease in the number of neural fibers innervating the esophagus.

Upper endoscopy is mandatory in the evaluation of patients with achalasia because there are no reliable criteria to differentiate primary achalasia from pseudoachalasia due to a neoplasm. Furthermore, pseudoachalasia can be missed with routine radiography.

The aim of therapy in achalasia is to decrease the pressure of the lower esophageal sphincter and enhance the emptying of the esophagus. Pharmacologic therapy has a limited role. Calcium antagonists are a reasonable option only for patients who are poor candidates for pneumatic dilatation or surgery, or as a temporizing measure before definitive therapy.

Pneumatic dilatation involves placing a balloon across the lower esophageal sphincter and inflating it to a pressure adequate to tear the muscle fibers. Symptoms improve with this therapy in 65% to 80% of patients at long-term follow-up. Pneumatic dilatation has many advantages: it is done as an outpatient procedure, recovery is rapid, discomfort is short-lived, and there is a low incidence of subsequent gastroesophageal reflux. The only associated risk is perforation, which happened in approximately 5% of cases in most reported series.

Surgery is also quite effective. Symptoms improve in over 80% of patients who undergo a modified Heller myotomy. However, surgery has some disadvantages: it is expensive, some morbidity is associated with it, and patients lose more days from work and have a greater risk of reflux afterward than with dilatation. Laparoscopic and thoracoscopic techniques for performing a Heller myotomy have recently been reported and appear to be effective. However, only small numbers of patients have been studied and follow-up is limited.

The newest and most exciting technique currently undergoing trials is injection of botulinum toxin into the lower esophageal sphincter. Bot-

ulium toxin inhibits neurotransmission by inhibiting acetylcholine release from nerve endings, and injection into the sphincter decreases resting pressures dramatically. Pilot studies suggest this is a promising mode of therapy.

A minority of patients with an esophageal diverticulum will have intractable symptoms. For these patients, surgical therapy is indicated with excision of the diverticulum and correction of the underlying motor disturbance with an esophageal myotomy.

Diverticula can also be seen in the middle esophagus. These are typically asymptomatic, although symptoms such as episodic dysphagia, chest pain, and regurgitation may occur. Just as in epiphrenic diverticulum, it may be difficult to determine if these symptoms are caused by the diverticulum or by an associated motor abnormality of the esophagus.

ACKNOWLEDGMENT

I wish to thank Diane Benigni for assistance with manuscript preparation.

GARY W. FALK, MD
 Department of Gastroenterology
 The Cleveland Clinic Foundation

SUGGESTED READING

Kadakia SC, Wong RK. Graded pneumatic dilation using Rigiflex achalasia dilators in patients with primary esophageal achalasia. *Am J Gastroenterol* 1993; **88**:34-38.

Wong RK, Maydonovitch CL. Achalasia. In: Castell DO, editor. *The esophagus*. Boston: Little, Brown and Co, 1992:233-260.

MISSED THE CONFERENCE? HERE IT IS!



CLEVELAND CLINIC VIDEO PROGRAMS

Intensive Review of Internal Medicine for 1995

Current concepts and Board-related issues are examined using an organ system approach in this in-depth analysis. Relevant clinical information is emphasized and lectures are supplemented by "Board Simulation" sessions which integrate clinical cases, pathology, and imaging studies. This comprehensive review is intended for those preparing for the Board Examination in Internal Medicine and those desiring a review of state-of-the-art developments in internal medicine.

Offers 51 hours of AMA-PRA Category 1 credit. Includes 25 videotapes, a 1,300 page syllabus and a self-assessment examination. Release date: June 17, 1994.*

Intensive Care Nephrology & Chronic Dialysis Therapy Update

Take an up-to-the-minute look at ICU nephrology and reimbursement strategies. This video program covers standard and newer concepts involved in the generation of frequent nephrological problems seen in ICU. The evolution of genetic engineering from lab to practice in both acute and chronic renal diseases is described, as well as evolving concepts of dialysis adequacy in peritoneal dialysis and analysis of dialysis patients. You will be able to interpret the outcomes of various maneuvers frequently undertaken in acute renal failure support and to appraise other extracorporeal modalities in support or treatment of failing organ systems.

Program offers 18.5 hours of AMA-PRA Category 1 credit. Program includes 9 videotapes, a 202-page syllabus, and a self-assessment examination. Release date: May 6, 1994.*

\$525 (plus \$12.25 S&H) (#143)

Call for FREE catalog of over 160 CMEVideo® programs

**TO ORDER
 CALL 1-800-284-8433
 OR FAX 1-800-284-5964**

**CMEVideo®
 PROGRAMS**

2000 Crawford Place, Suite 100
 Mt Laurel, NJ 08054