



EDUCATIONAL OBJECTIVE: Readers will identify appropriate uses of magnetic resonance imaging and other imaging tests in the management of breast cancer

LOUIE ENRIQUEZ, MD
Radiology Imaging Associates,
Denver, CO

JAY LISTINSKY, MD, PhD
Department of Radiology, University
of Wisconsin School of Medicine,
Madison, WI

Role of MRI in breast cancer management

ABSTRACT

In breast cancer, different situations call for different imaging tests. Mammography is the test of choice for screening women with no signs or symptoms of breast cancer. For diagnosis, tailored mammographic views and ultrasonography are the norm. Magnetic resonance imaging (MRI) is highly sensitive for cancer staging, problem-solving, posttreatment surveillance, and other indications. It can detect primary breast cancers and additional foci of cancer that are occult to standard imaging. Continued improvements in technology and studies to assess outcomes will help to better define MRI's role in breast cancer.

KEY POINTS

Whether rates of death and local recurrence are reduced when additional breast tumors found by MRI are treated remains to be seen.

MRI contrast enhancement occurs in many cancers, but it may occur for benign reasons; thus, the finding of contrast enhancement does not establish the diagnosis of breast cancer.

The National Comprehensive Cancer Network currently recommends screening with both mammography and MRI starting at age 20 to 25 for women at high risk of hereditary breast cancer and ovarian cancer.

A breast MRI evaluation costs about 10 times more than screening mammography and may not be covered by health insurance, but coverage for this indication appears to be improving gradually.

doi:10.3949/ccjm.76a.06043

A 52-YEAR-OLD WOMAN presents to your outpatient clinic with a newly palpable marble-sized lump in the upper outer quadrant of her right breast. The mass is firm and non-tender. She performs breast self-examinations regularly and first noticed the mass 3 weeks ago. Your examination confirms a palpable lesion. Annual screening mammograms at another facility have been negative, including the last one 6 months ago. The woman is otherwise in good health.

When she was younger, she had two pregnancies and gave birth to two children, whom she did not breastfeed. She reached menopause at age 49 and has never been on hormone replacement therapy. Neither she nor anyone in her family has had breast cancer, and she has never undergone breast biopsy.

She says that a woman she spoke with in the waiting room, a 2-year breast cancer survivor, told her that her primary cancer had been “finally diagnosed” with magnetic resonance imaging (MRI). This patient is now urging you to order an MRI. What should you do?

DIFFERENT IMAGING TESTS FOR DIFFERENT INDICATIONS

Different imaging tests are indicated in different situations. Screening mammography is the standard of care for women who have no signs or symptoms of breast cancer. When a screening examination shows abnormal or equivocal findings or when a patient presents with symptoms (eg, a palpable lesion, breast pain, nipple discharge), further characterization with a tailored imaging examination is warranted. Such an examination might include diagnostic mammography, ultrasonography, or MRI.

This article reviews MRI's role in breast cancer management with respect to the other imaging tests currently in use.

■ MAMMOGRAPHY IS THE SCREENING TEST OF CHOICE

Screening mammography, as distinguished from diagnostic mammography, is an x-ray examination of breast tissue that obtains high-quality images while using a very low dose of ionizing radiation. It is performed with the breast tissue compressed to optimize image quality. The examination time is short, usually 15 to 20 minutes. No contrast agents are used. The malignant lesions it detects differ from normal fibroglandular tissue in their x-ray attenuation, appearing as asymmetric soft-tissue densities, architectural distortion, masses, or abnormal calcifications.

The American Cancer Society¹ recommends mammography as the method of choice to screen for nonpalpable, clinically occult breast cancers in women over age 40 and in younger women with certain risk factors.

The rationale for screening mammography is supported by evidence of significant reductions in death rates from breast cancer in patients who undergo routine mammographic screening. Tabar et al,² in the Swedish Two-County Trial, found a 30% lower rate of death from breast cancer in women ages 40 to 74 who were invited to undergo screening: the reduction was 34% for women age 50 to 74 and 12% for women age 40 to 49. The authors attributed the smaller benefit in the younger group to a tendency toward more rapid tumor progression in that age group.

Mammography is somewhat less sensitive and specific in women with dense breasts,³ in younger women, and in women on hormone replacement therapy.⁴ For example, a recent population-based study of seven mammography registries in the United States⁵ reported that the sensitivity of mammography for detecting breast cancer, adjusted for breast density and age, ranged from 63% for extremely dense breast tissue to 87% for entirely fatty breast tissue, and from 69% for women age 40 to 44 to 83% for women age 80 to 89. The adjusted specificities ranged from 89% for extremely dense breast tissue to 97% for entirely

fatty breast tissue. The adjusted specificities in women not on hormone replacement therapy ranged from 91% for those age 40 to 44 to 94% for those age 80 to 89. In women on hormone replacement therapy, the adjusted specificity was about 92% for all ages taken together.

Digital is often better than film

Screening mammography has improved with the development of digital technology,⁶ in which images are acquired directly from an x-ray-sensitive solid-state receptor, without film. This process differs from digital computer-aided detection techniques, in which conventional analog films are optically scanned, generating a secondary digital image, which is then used for subsequent computerized analysis.

In 2005, the first large national trial comparing digital mammography with conventional mammography—the Digital Mammographic Imaging Screening Trial⁶—showed that digital mammography held a statistically significant advantage over conventional film-screen mammography in three subgroups⁷:

- Women under age 50
- Women with radiographically dense breast tissue
- Premenopausal or perimenopausal women.

It is hoped that these encouraging results will be confirmed and extended by other trials now in progress.

■ DIAGNOSTIC MAMMOGRAPHY FOR FURTHER WORKUP

Screening mammography yields findings of uncertain significance or frank concern in roughly 1 out of 10 examinations. In these cases, the examination is considered to be incomplete. If the finding is of unclear significance, previous mammograms, if available, may reveal whether the finding has remained the same or changed over time. If a worrisome change has occurred or if no prior films can be obtained, a diagnostic study with additional imaging must be carried out so that the radiologist can decide if a lesion is actually present.

Diagnostic mammography is a tailored examination that may include special projections to better visualize a specific region of concern, spot-compression views to disperse

MRI 'diagnosis' of breast cancer is not foolproof, but it offers useful information

dense breast tissue, or magnification views to characterize microcalcifications. In cases of known breast cancer, diagnostic mammography helps detect additional foci of cancer in the same or in the contralateral breast.⁸

■ DIRECTED ULTRASONOGRAPHY TO EVALUATE REGIONS OF CONCERN

While ultrasonography is not part of the standard breast cancer screening protocol,⁹ directed or “targeted” breast ultrasonography is routinely used in the diagnostic workup to evaluate particular regions of concern. Ultrasonography is used in combination with diagnostic mammography to evaluate mammographic masses, palpable lumps, asymmetric tissue, and architectural distortions.

Breast ultrasonography can usually distinguish cystic lesions from solid lesions, and it is used to guide core biopsy or fine needle aspiration of suspicious breast lesions. It is relatively inexpensive, widely available, and reliable when performed by a skilled and knowledgeable operator.

■ HOW MRI WORKS

Magnetic resonance imaging takes advantage of the magnetic properties of hydrogen nuclei (protons) in breast tissue. A small fraction of the protons in the patient are brought into alignment with a strong magnetic field within the MRI scanner. Then, the protons are exposed to a brief pulse of radiofrequency energy, which displaces their magnetic vectors. As the protons “relax” and realign along the applied magnetic field, energy is released. This energy, the electromagnetic magnetic resonance signal, is detected and electronically processed to construct an image, exploiting the different “relaxation times” of the different tissues in the breast to generate image contrast.

A standard breast MRI examination requires an intravenous paramagnetic contrast agent, usually a gadolinium chelate, to increase the sensitivity of the study. Gadolinium-based contrast material causes shortening of the T1 relaxation time of tissues in which the contrast agent accumulates, thereby increasing signal intensity (or “enhancement”) in those tissues.

Contrast enhancement may occur in malignant tissues with defective or “leaky” capillaries, but it also can occur in benign tissues, such as normal lymph nodes or benign proliferative processes. Thus, the finding of contrast enhancement does not by itself establish the diagnosis of breast cancer.

The patient must remain still

The patient is positioned prone for about 30 to 40 minutes inside the MRI scanner with the breasts encompassed by specially designed imaging coils, which maximize the signal strength and achieve high spatial resolution. The prone position also minimizes motion of breast tissue and transmitted physiologic motions, further ensuring good image quality.

Contrast enhancement over time

To display how contrast enhancement resolves over time, a series of scans must be obtained. First, a baseline scan is recorded. Then, the contrast material is given, and multiple post-contrast scans are obtained at equally spaced time intervals, typically 1 to 1.5 minutes apart. Usually five to seven postcontrast scans are recorded. During this time, the patient must continue to lie still without moving.

For each individual volume element (voxel) of breast tissue, which may measure 1 mm³ or less, a curve representing contrast enhancement vs time can be constructed. Such curves tend to show one of three typical trajectories or patterns, known as “washout,” “plateau,” and “progressive.” With additional postprocessing, these three contrast enhancement patterns are reduced to color coding and are mapped onto the gray-scale MRI image in the form of a color overlay, so that overall enhancement patterns in both breasts can be discerned at a glance by the radiologist.

These enhancement patterns initially were believed to be reliable indicators of malignant and benign conditions, but further experience has shown considerable overlap of the enhancement patterns between benign and malignant tissues. Thus, the diagnostic value of enhancement patterns is limited. As a rule of thumb, the washout pattern of enhancement (rapid uptake of contrast material followed by rapid washout) is thought to indicate malignancy

Incidental findings on MRI, although possibly benign, often may only be resolved by biopsy

in 60% to 70% of lesions that are suspicious in other respects.

Abnormal contrast enhancement of the suspicious region must be considered along with morphologic features, the degree of enhancement in adjacent normal-appearing tissue, and the correlation with mammographic or ultrasonographic findings.

Better for invasive ductal carcinoma than invasive lobular carcinoma or ductal carcinoma in situ

At present, we have no foolproof method of diagnosing cancer by MRI alone, though in many cases invasive ductal carcinoma can be predicted with a high degree of confidence. The accuracy of breast MRI is lower for “non-mass-like” enhancement, as is often seen in invasive lobular carcinoma and ductal carcinoma in situ.

Contraindications, problems

MRI for breast cancer evaluation is contraindicated in women with cardiac pacemakers, implanted neurostimulators, and certain older models of aneurysm clips and cardiac prosthetic valves. However, this is becoming less of a problem as MRI-compatible devices of recent design become more prevalent. To ensure safety, patients should complete a screening questionnaire for ferromagnetic devices before they are allowed to undergo breast MRI.

Claustrophobia may preclude an MRI study, but this is less of an issue now, as the newer “short-bore” magnet designs reduce the sensation of confinement.

A problem of increasing importance today is patient obesity: obese patients may not fit into the MRI scanner. So-called “open” MRI scanners are not a good alternative, as they cannot provide the high-resolution images of uniform quality required for breast MRI.

Another factor affecting the use of MRI for breast cancer diagnosis is the limited number of facilities that offer it. Head, spine, and orthopedic MRI services are more widely available.

Cost may be an issue. A breast MRI evaluation costs about 10 times more than screening mammography and may not be covered by health insurance, although coverage for this indication appears to be improving gradually.

MRI IS SENSITIVE, BUT NOT SO SPECIFIC

The role of MRI in evaluating breast disease has been studied and debated since contrast-enhanced breast MRI was introduced in 1985.¹⁰ Interest has grown steadily as evidence of its usefulness has accumulated. Improvements in MRI scanners have included better image resolution, dedicated breast coils, and rapid dynamic contrast-enhanced imaging.

The overall sensitivity of MRI for breast cancer is relatively high, with estimates ranging from 85% to 100%.¹¹ In invasive ductal carcinoma, its sensitivity approaches 100%.¹² Sensitivities for invasive lobular carcinoma and ductal carcinoma in situ are lower and not yet well defined.

In contrast, MRI’s specificity for breast cancer is much more variable, ranging from 37% to 100%. The discrepancies among estimates of specificity are attributed to multiple confounding methodologic factors in the studies to date, such as differences in imaging protocols, patient selection criteria, patient ages, interpretation criteria, and the level of experience of the interpreting radiologist.¹²

False-positive results may be caused by benign conditions such as fibroadenomas, intramammary lymph nodes, proliferative and nonproliferative fibrocystic changes, and mastitis, as well as by radial scars, atypical ductal hyperplasia, and lobular carcinoma in situ.¹³⁻¹⁵ In premenopausal women, the menstrual cycle may bring about regional physiologic variation in enhancement of the normal breast parenchyma, which may either simulate the appearance of a lesion or obscure a true lesion.¹⁶

Thus, breast MRI may detect cancer that is occult to mammography, but it also carries the risk of worrisome incidental findings that may only be resolved by biopsy. Such uncertain findings are troubling for both the radiologist and the patient when mammography, ultrasonography, and the physical examination are all normal. Clearly, breast MRI cannot be counted on to reassure the “worried well” patient.

MRI is not for screening in the general population

While its high sensitivity for invasive ductal carcinoma¹⁷ would seem to make breast MRI

A negative MRI study does not preclude biopsy of suspicious lesions detected on mammography or directed ultrasonography

attractive for breast cancer screening, it has the disadvantages of lower sensitivity for invasive lobular carcinoma and ductal carcinoma in situ,^{17,18} as well as the potential to raise suspicions of breast cancer that may be difficult to resolve. For these reasons, MRI is not suitable for routine breast cancer screening in asymptomatic women, although it is recommended for patients in some high-risk groups, as we discuss later.

Data from the Memorial Sloan-Kettering Cancer Center suggest that MRI can detect mammographically occult breast cancer in high-risk populations.¹⁹ This study evaluated 367 women at high risk (ie, with a personal history of breast cancer, lobular carcinoma in situ, or atypia, or with a family history of breast cancer). Biopsy was recommended in 64 (17%) of the women on the basis of MRI findings. Biopsy revealed cancer in 14 (24%) of 59 women who underwent biopsy. Subgroup analysis further suggested a 50% positive predictive value of biopsy based on MRI findings in women with both a positive family history and a personal history of breast cancer.

Further studies of breast MRI for screening high-risk populations are under way in North America and Europe.

■ CLINICAL APPLICATIONS OF MRI OF THE BREAST

MRI has been shown to be useful in:

- Staging biopsy-proven primary breast carcinoma
- Detecting an occult primary breast cancer in a patient with proven axillary node involvement but negative results on mammography and ultrasonography
- Ascertaining the extent of disease after lumpectomy with positive margins or close margins
- Investigating suspected pectoralis muscle invasion
- Assessing response to chemotherapy, including preoperative chemotherapy
- Looking for suspected recurrent disease, such as in a postsurgical scar
- A compelling clinical presentation with negative or equivocal imaging results
- Problem solving, ie, workup of uncertain imaging findings that could not be resolved

even after special mammographic and ultrasonographic techniques were used

- Needle localization and guided biopsy
- Known or suspected rupture of breast implants
- Screening patients with certain well-defined risk factors for breast cancer.

The current standard of practice does not support the use of MRI to replace problem-solving mammography and ultrasonography. A negative MRI study does not preclude biopsy of a suspicious lesion found with mammography or directed ultrasonography.

Lesion characterization and staging

Surgical options for treating breast cancer are breast-conserving surgery and mastectomy, taking into account the tumor size, multifocality or multicentricity, local extent vs distant spread, nodal status, and patient preference. Studies have shown that MRI is more accurate than mammography and ultrasonography in defining the extent of tumor burden as characterized by tumor size and multifocality or multicentricity.^{20,21}

Preoperative MRI also has been shown to change therapeutic decisions when additional disease was detected and then proven by image-guided biopsy.¹⁹ In a study by Fischer et al²² in 336 women with breast cancer, MRI led to a change in therapy in 19.6% of patients by demonstrating unsuspected multifocal or multicentric ipsilateral lesions or contralateral carcinomas. In all cases, a confirming tissue diagnosis, either before or after MRI, was obtained before surgery. Given the potential for false-positive findings on breast MRI, biopsy of newly detected suspicious lesions is generally necessary before mastectomy is contemplated.

MRI in the follow-up assessment

After excisional biopsy, MRI may help determine the presence or absence of residual tumor if there are positive or close margins shown by surgical pathology, or if residual microcalcifications persist on the postbiopsy mammogram.²³ The time between surgical biopsy and follow-up MRI affects the sensitivity of MRI for residual tumor. Frei et al²⁴ reported a sensitivity of 89% to 94% when imaging was done at least 28 days after excision.²¹

MRI cannot be counted on to reassure the 'worried well' patient

MRI also is useful in identifying and differentiating tumor recurrence from postsurgical or postradiation scar when conventional imaging is indeterminate.²⁵ In a study of 45 women with suspected tumor recurrence after lumpectomy, with or without radiotherapy and chemotherapy, Lewis-Jones et al²⁶ reported a sensitivity of 100% and a specificity of 94% for MRI in detecting new tumor vs posttreatment fibrosis.²⁶

Inflammatory changes in the breast tissue after surgery and radiation therapy limit the accuracy of MRI. Tissue enhancement can be seen in the operative bed for up to 6 months after surgery and for up to 24 months after radiation therapy. In general, local tumor recurrence appears after this interval. Therefore, the postsurgical timing of the MRI examination is important.

Problem solving

At times, mammographic findings are unclear as to whether a suspected lesion is truly present, often because of the radiographic density of fibroglandular breast tissue. In some cases, a lesion's morphology is indeterminate for malignancy. These equivocal findings can usually be resolved with the combined use of tailored mammographic views, as noted above (eg, magnification or compression views), and directed ultrasonography.

If the findings are still inconclusive after this additional workup, MRI may be useful. Newer, improved MRI scanners can show structures as small as 0.5 mm, which helps the radiologist discern lesion morphology. Moreover, contrast-enhanced and temporally resolved imaging provides estimates of spatially localized enhancement patterns and kinetics, which in turn may offer clues as to whether a lesion is benign or malignant.

Screening patients at high risk

The National Comprehensive Cancer Network²⁷ currently recommends screening with both mammography and MRI starting at age 20 to 25 for women at high risk for hereditary breast cancer and ovarian cancer. Risk factors include the following:

- A known BRCA1 or BRCA2 mutation in the patient or a family member
- A personal history of breast cancer, with

two or more close blood relatives with breast or epithelial ovarian cancer at any age

- A close male blood relative with breast cancer
- A personal history of epithelial ovarian cancer
- Being in an ethnic group with a higher frequency of deleterious mutations (eg, Ashkenazi Jews)
- Mutations in p53 (Li-Fraumeni syndrome) or PTEN (Cowden syndrome).

■ MRI IN THE PREOPERATIVE EVALUATION: THE DEBATE

Numerous reports have shown that MRI can detect additional foci of breast cancer in a substantial number of women with a new diagnosis of breast cancer. While some argue that detecting these additional lesions should improve outcomes after the first operation and, hopefully, lead to lower rates of recurrence, the long-term consequences of MRI-directed changes in treatment have not been fully studied. Below is a summary of the arguments both against and for the use of breast MRI in staging.

The argument against preoperative MRI

Mastectomy was the routine treatment for breast cancer into the 1980s. The arrival of breast conservation surgery combined with radiation therapy offered major advantages with similarly low recurrence rates. Based on the results of controlled clinical trials with mortality as the end point, breast conservation therapy and mastectomy confer equivalent risk to the patient. Any increase in the rate of mastectomy prompted by MRI findings would represent a setback in the standard of care. And since radiation therapy is presumed to eradicate or delay progression of residual disease in most women who undergo conservation therapy, preoperative MRI would have little or no impact on rates of recurrence or death. Thus, MRI should not be used routinely in the workup of new breast cancers.²⁸

The argument for preoperative MRI

The upper threshold amount of residual disease that can be eradicated by radiation thera-

Inflammatory changes after surgery and radiation therapy limit the accuracy of MRI

py is not yet well established. There are as yet no MRI criteria for assessing the likelihood of standard treatment failure in individual patients with multifocal or multicentric disease, or with occult cancer in the contralateral breast. Although the rate of recurrence after breast conservation is low, it is not zero, and each patient should be offered the best possible chance for successful treatment. Detecting widespread disease can obviate inappropriate attempts at conservation, in which both lumpectomy with positive margins and re-excision with positive margins are carried out before the full extent of the disease burden is understood. Knowledge of the extent of disease at presentation will help the patient to make a more informed decision when presented with treatment options. A staging MRI examination showing only a single cancer lesion may permit the patient to choose conservation therapy with a high degree of confidence that no macroscopic disease will be missed at surgery.²⁹

Challenges for future clinical trials

These issues will not be easy to resolve. Definitive answers can only come from controlled clinical trials with mortality as the end point, but for the data from these trials to be useful, the trials must use standardized MRI technique and interpretation criteria. Such standardization has yet to be accomplished.

In the absence of such guidance, it seems reasonable to use MRI for staging within the known limitations of the technique and with secure histologic confirmation whenever widespread disease is suspected from the MRI findings. In this way, the patient and her surgeon can select a treatment plan based on the most realistic assessment of disease burden.

■ CASE RESOLVED

Our 52-year-old patient had been managed appropriately with yearly screening mammography before the onset of her symptoms. On discovery of the new palpable lump, diagnostic mammography (**FIGURE 1**) showed confluent dense breast tissue in the region of the palpable lesion. Targeted ultrasonography showed a discrete mass lesion, a biopsy of which proved it to be invasive breast cancer.

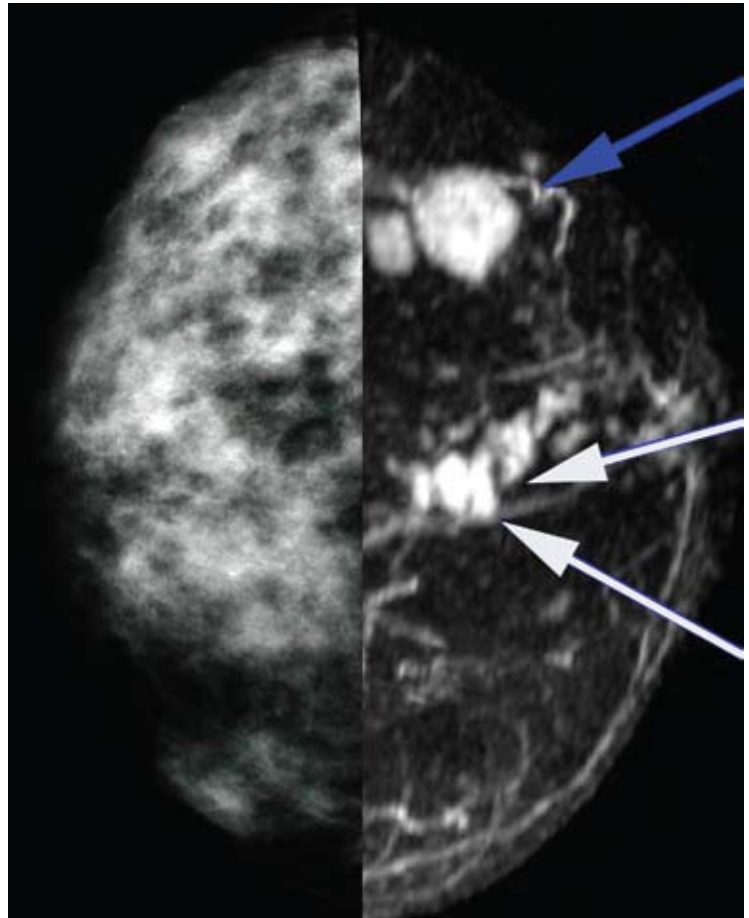


FIGURE 1. Standard craniocaudal mammography (left) shows confluent dense breast tissue in the area of the palpable lesion. Targeted ultrasonography showed a discrete mass lesion. Biopsy showed this lesion to be invasive breast cancer. Magnetic resonance imaging (MRI) (right) was done to assess the extent of disease. This “mirror-image” view of the same breast from the contrast-enhanced MRI shows two enhancing lesions with irregular borders in the region of the proven cancer (blue arrow). The enhancement kinetics of the lesions were consistent with malignancy. The MRI study showed other, unsuspected, irregular, small lesions in the 12-o’clock region (white arrows).

MRI to assess extent of disease (**FIGURE 1**) showed two enhancing lesions with irregular borders in the region of the proven cancer. The MRI enhancement kinetics of the lesions were consistent with malignancy. MRI also showed several additional, unsuspected, small, irregular lesions in the 12-o’clock region.

On the basis of these findings, a second ultrasonographic examination of the right breast

was carried out, targeting the 12-o'clock region. One of the MRI-detected lesions was located, and biopsy showed invasive breast cancer of the same cell type as the palpable mass. With this evidence of multiple malignant lesions in the same breast, it was concluded that breast-conserving surgery would not be feasible. The

patient underwent mastectomy with pathologic confirmation of the MRI findings.

Comment. This case demonstrates how breast MRI, when used appropriately, can lead to objective pathologic results that support the clinical decision to perform a mastectomy rather than breast conservation therapy. ■

REFERENCES

1. **American Cancer Society.** Breast cancer facts and figures 2008-2009. Atlanta: American Cancer Society. http://www.cancer.org/docroot/STT/content/STT_1x_Breast_Cancer_Facts_Figures_2007-2008_08.asp. Accessed 10/9/2009.
2. **Tabar L, Fagerberg G, Chen HH, et al.** Efficacy of breast cancer screening by age: new results from the Swedish Two-County Trial. *Cancer* 1995; 75:2507-2517.
3. **Vachon CM, van Gils CH, Sellers TA, et al.** Mammographic density, breast cancer risk and risk prediction. *Breast Cancer Res* 2007; 9:217.
4. **Warren R.** Hormones and mammographic breast density. *Maturitas* 2004; 49:67-78.
5. **Carney PA, Miglioretti DL, Yankaskas BC, et al.** Individual and combined effects of age, breast density, and hormone replacement therapy use on the accuracy of screening mammography. *Ann Intern Med* 2003; 138:168-175.
6. **Pisano ED, Gatsonis C, Hendrick RE, et al.** Diagnostic performance of digital versus film mammography for breast-cancer screening. *N Engl J Med* 2005; 53:1773-1783.
7. **Pisano ED, Hendrick RE, Yaffe MJ, et al.** Diagnostic accuracy of digital versus film mammography: exploratory analysis of selected population subgroups in DMIST. *Radiology* 2008; 246:376-383.
8. **Barlow WE, Lehman CD, Zheng Y, et al.** Performance of diagnostic mammography for women with signs or symptoms of breast cancer. *J Natl Cancer Inst* 2002; 94:1151-1159.
9. **Berg WA, Blume JD, Cormack JB, et al.** Combined screening with ultrasound and mammography vs mammography alone in women at elevated risk of breast cancer. *JAMA* 2008; 299:2151-2163.
10. **Heywang SH, Hahn D, Schmid H, et al.** MR imaging of the breast using gadolinium-DTPA. *J Comput Assist Tomogr* 1986; 10:199-204.
11. **Heywang-Kobrunner SH, Viehweg P, Heinig A, Kuchler CH.** Contrast-enhanced MRI of the breast: accuracy, value, controversies, solutions. *Eur J Radiol* 1997; 24:94-108.
12. **Lee CH.** Problem solving MR imaging of the breast. *Radiol Clin North Am* 2004; 42:919-934.
13. **Heywang SH, Wolf A, Pruss E, Hilbertz T, Eiermann W, Permanetter W.** MR imaging of the breast with Gd-DTPA: use and limitations. *Radiology* 1989; 171:95-103.
14. **Gilles R, Guinebretière JM, Lucidarme O, et al.** Nonpalpable breast tumors: diagnosis with contrast-enhanced subtraction dynamic MR imaging. *Radiology* 1994; 191:625-631.
15. **Fobben ES, Rubin CZ, Kalisher L, Dembner AG, Seltzer MH, Santoro EJ.** Breast MR imaging with commercially available techniques: radiologic-pathologic correlation. *Radiology* 1995; 196:143-152.
16. **Müller-Schimpfle M, Ohnenhäuser K, Stoll P, Dietz K, Claussen CD.** Menstrual cycle and age: influence on parenchymal contrast medium enhancement in MR imaging of the breast. *Radiology* 1997; 203:145-149.
17. **Orel SG, Schnall MD, Powell CM, et al.** Staging of suspected breast cancer: effect of MR imaging and MR-guided biopsy. *Radiology* 1995; 196:115-122.
18. **Weinstein SP, Orel SG, Heller R, et al.** MR imaging of the breast in patients with invasive lobular carcinoma. *AJR Am J Roentgenol* 2001; 176:399-406.
19. **Morris EA, Liberman L, Ballon DJ, et al.** MRI of occult breast carcinoma in a high-risk population. *AJR Am J Roentgenol* 2003; 181:619-626.
20. **Esserman L, Hylton N, Yassa L, Barclay J, Frankel S, Sickles E.** Utility of magnetic resonance imaging in the management of breast cancer: evidence for improved preoperative staging. *J Clin Oncol* 1999; 17:110-119.
21. **Boetes C, Mus RD, Holland R, et al.** Breast tumors: comparative accuracy of MR imaging relative to mammography and US for demonstrating extent. *Radiology* 1995; 197:743-747.
22. **Fischer U, Kopa L, Grabbe E.** Breast carcinoma: effect of preoperative contrast-enhanced MR imaging on the therapeutic approach. *Radiology* 1999; 213:881-888.
23. **Orel SG, Reynolds C, Schnall MD, Solin LJ, Fraker DL, Sullivan DC.** Breast carcinoma: MR imaging before re-excisional biopsy. *Radiology* 1997; 205:429-436.
24. **Frei KA, Kinkel K, Bonel HM, Lu Y, Esserman LJ, Hylton NM.** MR imaging of the breast in patients with positive margins after lumpectomy: influence of the time interval between lumpectomy and MR imaging. *AJR Am J Roentgenol* 2000; 175:1577-1584.
25. **Gilles R, Guinebretière JM, Shapeero LG, et al.** Assessment of breast cancer recurrence with contrast-enhanced subtraction MR imaging: preliminary results in 26 patients. *Radiology* 1993; 188:473-478.
26. **Lewis-Jones HG, Whitehouse GH, Leinster SJ.** The role of magnetic resonance imaging in the assessment of local recurrent breast carcinoma. *Clinical Radiol* 1991; 43:197-204.
27. **National Comprehensive Cancer Network.** Clinical practice guidelines in oncology. Genetic/familial high-risk assessment: breast and ovarian cancer. www.nccn.org/professionals/physician_gls/f_guidelines.asp. Accessed May 4, 2009.
28. **Morrow M, Freedman G.** A clinical oncology perspective on the use of breast MR. *Magn Reson Imaging Clin N Am* 2006; 14:363-378.
29. **Schnall M.** MR imaging of cancer extent: is there clinical relevance? *Magn Reson Imaging Clin N Am* 2006; 14:379-381.

ADDRESS: Jay Listinsky, MD, PhD, 17200 South Woodland Road, Shaker Heights, OH 44120; e-mail gaulbert@aol.com.

CME CREDIT TEST

Visit WWW.CCJM.ORG
Test your knowledge
of clinical topics and earn
Category I CME Credit

