

DIVERTICULUM OF THE ESOPHAGUS

Report of Two Cases

R. S. DINSMORE, M.D.

INTRODUCTION

The two cases of diverticulum of the esophagus which are herein reported occurred in brothers, aged 61 and 51. The lesions were almost identical in location and size. Each patient had known for several years that he had a diverticulum, and each came to operation because of difficulty in swallowing. A third brother, aged 38, had no x-ray evidence of a diverticulum. He has not had an esophagoscopy.

Although there is considerable doubt as to whether these lesions are congenital, the occurrence of these two cases in brothers suggests the possibility. Boyd¹ denies a congenital origin of diverticulum of the esophagus, and Perrone² states that he has found only two instances in the literature in which the writers were certain of the diagnosis. Jackson and Shallow³ reported a case in a child 8 years of age, who discharged particles of food through the external chest wound following a rib resection. At autopsy a small tube was found springing from the posterior lateral wall of the esophagus. Further exploration showed that it opened into the chest, which led them to believe that it was a congenital lesion. Rush and Stingily⁴ reported a case in an infant who died at the age of 20 days with a swelling at the side of the neck. At autopsy they found what appeared to be a true congenital diverticulum.

CASE REPORTS

Case 1: The patient, a 61 year old man, had always been in good health. His chief complaint was "throat trouble". For an indefinite time he had had a gurgling in his throat and had regurgitated food several hours after eating. No swelling or pain in his neck had been noticed. An x-ray taken 4 years prior to examination had revealed a diverticulum, about 3 x 3 mm., situated in the upper third of the esophagus.

The general physical examination was normal. The patient's height was 65 inches and his weight 162 pounds. The blood pressure was 120/80. The urine was normal. The blood count showed 4,560,000 red blood cells, 87 per cent hemoglobin; and 4,200 white blood cells. The blood sugar was 105 mg. per cent, and the blood urea 30 mg. per cent, fasting. The Wassermann and Kahn tests were negative. X-ray examination showed that the diverticulum did not extend into the superior mediastinum, but had increased to about twice its size on the previous film. Excision of the diverticulum was advised.

At the beginning of the operation an unsuccessful attempt was made to pass a Levine tube into the stomach. The patient was given 70 mg. of avertin, and an esophagoscope was passed. It was impossible, however, to pass the Levine tube by means of the esophagoscope beyond the site of the diverticulum, and the procedure was abandoned.

R. S. DINSMORE

A transverse thyroid incision was made, and the skin flaps dissected upward and downward. The muscles were separated longitudinally over the left lobe of the thyroid, which was retracted mesially and anteriorly. The diverticulum was easily located and dissected downward to its neck. The opening of the diverticulum was closed with No. 0-0-0 chromic interrupted catgut sutures and reinforced by a row of interrupted No. 0 silk sutures. A small piece of iodoform gauze, the end of which was covered with vaseline, was placed just below the site of the closure. The muscles were approximated with No. 0-0-0 catgut sutures, and the skin was closed with clips.

After traction had been placed on the sac through an esophagoscope, an attempt was made to pass a Levine tube into the stomach. Before the patient left the operating table, however, the tube had come back into the mouth. No attempt was made to reinsert it.

The sac was globular in shape and measured about 2 cm. in diameter. The wall was about 2 mm. thick, and the mucosa was smooth and white. Histologically, microscopic section showed normal squamous epithelium on the mucosal surface. A small amount of muscular tissue was present in the wall of the sac.

The postoperative course was uneventful. The highest temperature was 100.6°F. Immediately after the operation 2000 cc. of 3 per cent glucose in saline was given by hypodermoclysis, and 3000 cc. of 5 per cent glucose in saline was administered intravenously daily for two days. Sips of water were allowed at the end of 48 hours; on the fifth postoperative day a liquid diet was allowed; and on the seventh postoperative day a soft diet was begun. The patient had no difficulty in swallowing and was discharged on the tenth postoperative day.

Case 2: A man aged 51 complained of a choking sensation and a slight soreness in the throat. Seven years ago he had begun to notice an occasional choking sensation while eating and at infrequent intervals during the night. The attacks had gradually increased in intensity, and at the time of examination he stated that he felt as though something was stuck in the throat. For 5 years the patient had experienced a sensation of food coming back into his pharynx immediately after eating. This discomfort which always seemed to be in the midline, just below the larynx, could be relieved by the act of swallowing or by drinking water, or by manipulating the neck so as to empty the pouch by pressure. Nausea or expectoration of blood were not experienced. He had relatively little difficulty in taking fluids. X-rays taken 5 years previously showed a small diverticulum, which had enlarged to the size shown (Fig. 1).

The past history revealed that several years ago he had had two attacks of right-sided renal colic. A flat x-ray plate of the abdomen showed small stones in the region of the right kidney pelvis.

The patient was a short, obese individual, 66 inches tall, weighing 187 pounds, and appeared to be in excellent health. The pulse rate was 86, and the blood pressure 116/64; the temperature was normal. The physical examination revealed a few fine crepitant râles over the base of the left lung posteriorly. The impression of the examiner was diverticulum of the esophagus and obesity.

Laboratory studies: The urine was normal. The blood count was 5,180,00 red blood cells, 94 per cent hemoglobin, and 11,300 white blood cells. The differential count showed 52 per cent polymorphonuclear neutrophils, 4 per cent eosinophiles, 1 per cent basophiles, 41 per cent lymphocytes, and 2 per cent monocytes. The blood sugar was 114 mg. per cent, and the blood urea was 39 mg. per cent, fasting. The Wassermann and Kahn tests were negative.

DIVERTICULUM OF THE ESOPHAGUS

The x-ray of the chest showed increased fibrotic infiltration with extension into the peripheral zones and some small calcified glands at both hili. Excision of the diverticulum was advised.

Satisfactory anesthesia was obtained with 70 mg. of avertin and supplementary gas, oxygen, and ether. A Hasslinger esophagoscope was introduced, and the internal open-

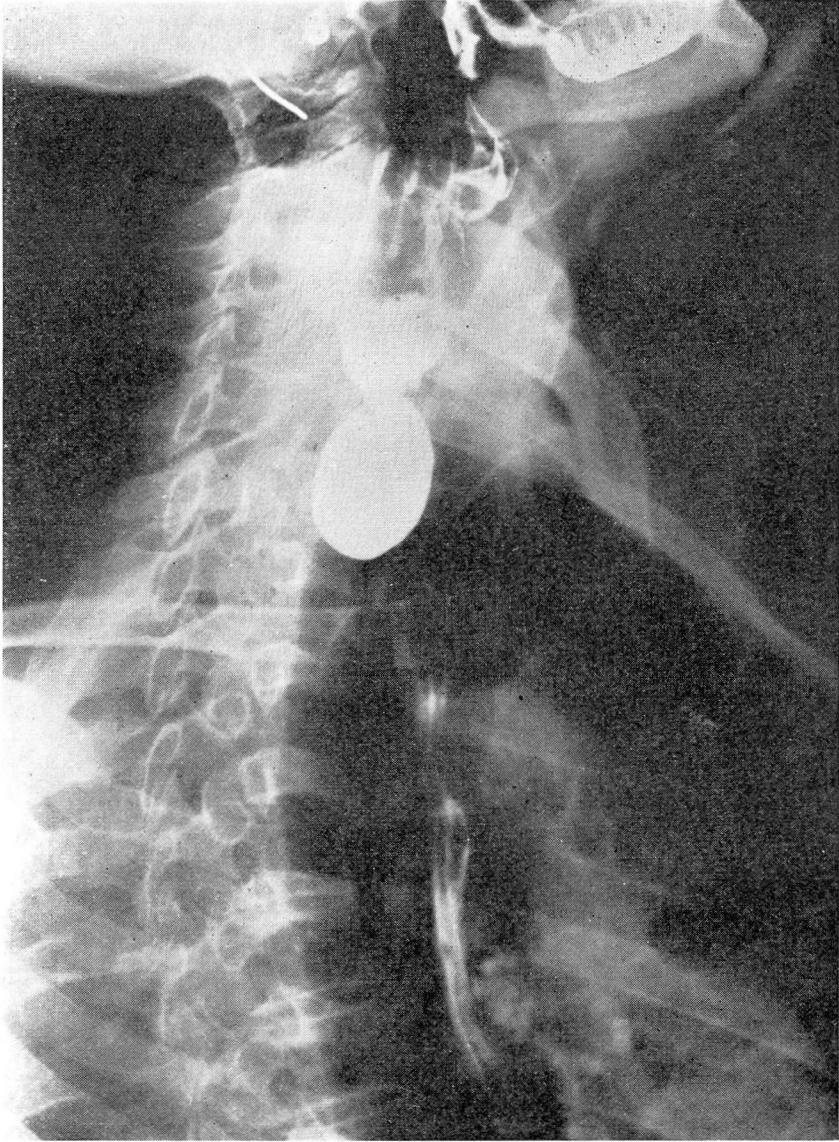


FIGURE 1

R. S. DINSMORE

ing of the diverticulum was noted. A transverse incision was made midway between the thyroid cartilage and the suprasternal notch. The skin flaps were dissected for a short distance upward and downward, and an oblique incision was made through the pre-thyroid muscles. The left lobe of the thyroid was retracted mesially, and the esophageal diverticulum identified and dissected free. The diverticulum was about 2½ inches long, the neck of the sac being opposite the cricoid cartilage. The stump of the diverticulum was closed with continuous No. 0-0-0 chromic catgut sutures and reinforced by fine interrupted sutures through the muscularis. A cigarette drain was placed just below the lower angle of the anastomosis. A Levine tube was then passed through the esophagoscope into the stomach. The pregladular muscles were reapproximated with interrupted No. 0-0-0 chromic catgut sutures, and the skin was closed with clips.

The postoperative course was uneventful, and the patient was discharged on the ninth postoperative day, free from symptoms.

DISCUSSION

For many years there has been a discussion as to whether or not an esophageal diverticulum is best treated by a one or a two-stage operation. The excellent results in a large series of cases reported by Lahey^{5,6} and Shallow^{7,8} indicate that either is a satisfactory method. Jackson,^{3,9,10,11} Shallow,^{7,8} and Eliason,^{12,13} have done the operations in one stage, while C. H. Mayo,¹⁴ Pool,¹⁵ and Lahey,^{5,6} have used a two-stage procedure.

Mediastinitis has not been a complication in the many cases reported. Moynihan¹⁶ has stated that this complication has been over-emphasized. Shallow^{7,8} is in accord and in 104 cases has not reported a single instance of mediastinitis.

Dr. Lahey always does a two-stage operation, without using an esophagoscope and with periodic postoperative dilatations. Jackson and his group devised the preliminary passing of a leaded thread, and later the insertion of a duodenal tube over this thread, routine esophagoscopy, and the use of the esophagoscope at operation, with no postoperative dilatation.

I have performed the operation with 3 technics: (1) a two-stage procedure, (2) a one-stage procedure, and (3) a modification. In the modified technic the sac is ligated, and a small pack is placed in the operative wound and is removed at the end of 48 hours. Two or three sutures are then placed in the pregladular muscles, and the skin closed with clips. In the uncomplicated case I prefer to do the one-stage operation, following Shallow's^{7,8} technic of handling the stump. On the other hand I have had cases in which it has been a distinct advantage to do the two-stage procedure. My own preference for the one-stage operation

DIVERTICULUM OF THE ESOPHAGUS

is that at the primary operation the stump is much more easily handled with a much better apposition of all the layers. Likewise, the use of an esophagoscope allows one to see the sac distinctly, and also at the completion of the operation a duodenal tube may be easily inserted if this has not been done preoperatively. Undoubtedly, the use of the duodenal tube has helped greatly in these cases, as the tube can be left in place for 5 or 6 days and a normal caloric and electrolytic intake maintained by feeding the patient through the tube.

Babcock suggested that a transverse incision be made in these cases. I have used this satisfactorily, simply making an ordinary thyroid incision and then dividing the preglandular muscles longitudinally and exposing the lobe of the thyroid, and retracting it mesially. This provides adequate exposure and leaves a much less noticeable scar than does an incision made longitudinally. In neither of these cases was it necessary to ligate any of the thyroid vessels, although Shallow^{7,8} has stated that in 35 per cent of his series some vessels had to be ligated. On the other hand, Eliason^{12,13} reported only one case in which this was necessary.

The duodenal tube is usually removed on the fifth or sixth day, and on the following day the patient is allowed small quantities of fluids. Occasionally, the patient will complain about irritation from the tube. The second patient reported insisted that when he coughed the movement of the tube caused him discomfort. Therefore, if the patient has a good deal of mucus the tube should be removed earlier, as these patients do well for a few days with nothing by mouth and intravenous glucose. The Penrose drain is loosened on the third day and ordinarily removed on the fifth. I have not practised a postoperative dilatation. The patients are given as little sedation as possible, since, as has been emphasized by many writers, the cough reflex should not be abolished.

In both of the reported cases, the sac was closed after putting two guide sutures in the fundus of the sac. The neck of the sac was closed with a running suture of No. 0-0-0 chromic catgut, and apposition of the muscularis over this with fine interrupted stitches. Shephard¹⁷ has devised a small clamp with which the base of the diverticulum is grasped, and the sac is excised; then, with a fine running suture of No. 0-0-0-0-0 chromic catgut over the clamp, as in intestinal work, the base of the sac is closed. I believe, however, that Shallow's technic is the most satisfactory.

R. S. DINSMORE

SUMMARY

Two cases of diverticulum of the esophagus are reported which were operated upon by a one-stage procedure. Although these cases occurred in brothers, there was no evidence to show that they were congenital.

BIBLIOGRAPHY

1. Boyd, William: *Surgical Pathology* (Philadelphia: W. B. Saunders Co. 1925) p. 231.
2. Perrone, Joseph A.: Diverticula of the esophagus. *The Laryngoscope*, 46:899-921, 1936.
3. Jackson, C., and Shallow, T. A.: Diverticula of esophagus, pulsion traction, malignant and congenital. *Ann. Surg.* 83:1-19 (January) 1926.
4. Rush, Leslie V., and Stingily, C. R.: Congenital diverticulum of esophagus. Case report. *South. Med. Jour.* 22:546-548 (June) 1929.
5. Lahey, F. H.: Surgical management of pharyngoesophageal diverticulum based upon experience with 21 cases. *Trans. South. S. A.*, 42:421-434, 1929. *Surg. Gynec. & Obst.*, 51:227-236, 1930.
6. Lahey, Frank: The management of pulsion esophageal diverticulum. *J. A. M. A.* 109:141-149 (October) 1937.
7. Shallow, T. A.: Combined one stage closed method for the treatment of pharyngeal diverticula. *Surg., Gynec., & Obst.*, 62:624-633, 1936.
8. Shallow, T. A.: Pharyngeal diverticulum. *Jour. of Inter. Coll. of Surg.*, 2:48-52, 1939.
9. Jackson, Chevalier: *Bronchoscopy and Esophagoscopy* (2nd ed.; Philadelphia: W. B. Saunders & Co. 1926).
10. Jackson, Chevalier: *Peroral Endoscopy and Laryngeal Surgery* (St. Louis: The Laryngoscope Co. 1914) pp. 544-545.
11. Jackson, Chevalier, and Babcock, W. W.: One-stage operation with esophagoscopic assistance (Diverticulum of the esophagus). *Surg. Clin. N. A.*, 10:1249-1263 (December) 1930.
12. Eliason, E. L.: Esophageal diverticulum (cervical). *Surg. Clin. N. A.*, 3:163-169 (February) 1923.
13. Eliason, E. L., et al.: Esophageal diverticula. *Surgery*, 2:188-195 (August) 1937.
14. Mayo, C. H.: Treatment of diverticulum of esophagus. *Ann. Surg.*, 77:267-271 (March) 1923.
15. Pool, E. H.: Diverticulum of the esophagus, two-stage operation. *Ann. of Surg.*, 95:151-153 (January) 1932.
16. Moynihan, Sir Berkeley: Correspondence. *Surg., Gynec., & Obst.* 54:128, 1923.
17. Shephard, John Hunt: Pharyngoesophageal diverticula. *Calif. and Western Med.*, 51:156-159, 1931.