

CAVERNOUS HEMANGIOMA OF THE SYNOVIAL MEMBRANE OF THE KNEE JOINT

Report of Three Cases

CHARLES F. THOMAS, M.D.,* and CHARLES M. EVARTS, M.D.

Department of Orthopedic Surgery

CAVERNOUS hemangioma of the synovial membrane of the knee joint is not common, as reports of approximately 50 cases have been published.¹⁻⁴ In spite of a characteristic clinical picture that the tumor presents, misdiagnosis is often made, warranting reemphasis of the salient features of this rare entity.

Hemangiomas are common tumors, and although they appear in several forms, two groups predominate; the capillary hemangiomas, composed of an endothelial component forming many small blood vessels, and the cavernous hemangiomas, characterized by large blood-filled spaces lined with a thin endothelium and lacking the cellularity noted in the former type. The cavernous variety is the most frequent type found in the knee joint.

Cavernous hemangioma of the knee joint was comprehensively discussed by O'Ferrall¹ in 1925. He pointed out that blood vessel tumors occurring within joint cavities can present themselves clinically in such a way as to obscure the correct diagnosis. The tumor mass is often palpable around the patella and appears much like a pedunculated joint mouse. The mass is only slightly movable and softer in consistency than cartilage or bone. He observed that the cardinal diagnostic points were: (1) a history of the existence of a tumor since early life, or association with more or less recent trauma; (2) a soft and slightly movable, unusually sensitive joint mass; (3) a reduction in size of the mass on elevation of the extremity; (4) moderate pain with slight limitation of motion, and (5) negative roentgenographic examinations.

Report of Cases

Case 1. An 18-year-old boy was examined in 1956 because of pain and swelling of the right knee for several years. After a recent athletic injury, he had been unable to walk for nine days. He had noted the swelling in his knee had decreased when in the supine position. The physical examination showed only some varices in the region of the suprapatellar pouch and in the posteromedial area of the right knee. The range of knee motion was from 0 to 120 degrees.

The symptoms persisted and eight months later the knee joint was explored. At operation the synovium was found to be involved with a mass of tortuous hemangioma. The affected synovium was excised. The postoperative period was complicated by the persistent accumulation of joint fluid, requiring repeated aspirations. The effusions gradually subsided. Two months postoperatively, the mass in the suprapatellar pouch was similarly excised. Nine months later a third operative procedure was performed to excise additional hemangioma.

The subsequent course has been satisfactory with disappearance of the symptoms. Some swelling that is presumed to be residual hemangioma is still present, but the tumor is apparently stationary with no evidence of progression four years postoperatively.

*Fellow in the Department of Orthopedic Surgery.

Case 2. A 17-year-old girl was first examined in 1963 because of intermittent pain at the lateral patellar aspect of the right knee and swelling of the right ankle. These symptoms had been present for several months, and apparently had not been initiated by trauma. She had been given two intraarticular injections of cortisone which did not relieve her pain.

Physical examination demonstrated an exquisitely tender, pea-sized, mobile mass in the right lateral patellar region, and minimal pitting edema of the right ankle. Roentgenograms of the right knee were normal. A diagnosis of hemangioma was considered and surgical exploration was advised.

At operation a reddish-blue tumor, 1.5 cm. in diameter, involving the synovium of the joint capsule just lateral to the inferior pole of the patella was found and completely excised. The tissue sections confirmed the diagnosis of cavernous hemangioma. The patient has been asymptomatic for the 20 months since operation.

Case 3. A 10-year-old boy was examined in 1965, because of intermittent swelling and pain of the right knee for one year. A small tender mass had been noted in the suprapatellar region at onset but spontaneously regressed within two weeks after its appearance. Ten months later the tender mass recurred and was associated with a prominent limp. There was no history of trauma. In infancy the patient had been treated with bilateral wedging casts to correct a clubfoot deformity; results were satisfactory. He had congenital ichthyosis of the skin and dyshidrosis of both feet.

On physical examination the skin was dry, flaky, and scaly. A rubbery, tender, 2.0-cm. movable mass that became prominent on standing was present in the right lateral suprapatellar pouch. The range of motion of the right knee was from 0 to 115 degrees, and a slight joint effusion was present. The right quadriceps was $\frac{1}{2}$ -in. smaller than the left. Except for roentgenograms of the right knee, which showed fullness of the soft tissues along the distal femoral shaft, the results of the diagnostic studies were within normal limits.

At operation the synovium of the suprapatellar pouch was found to be involved by hemangioma over an area of 3.0 by 2.0 cm. The affected tissue was totally excised and the pathologic diagnosis was that of cavernous hemangioma (*Fig. 1 and 2*). The patient has been asymptomatic for six months.

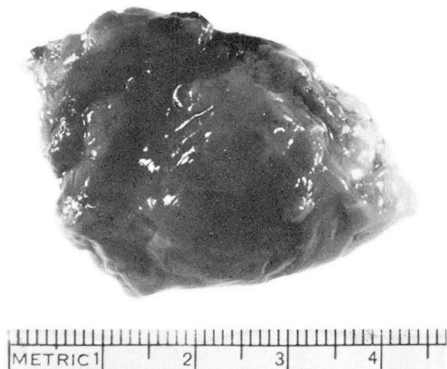


Fig. 1. Case 3. Photograph showing the gross appearance of a cavernous hemangioma removed at operation.

Discussion

There are certain characteristic clinical features of intraarticular cavernous hemangiomas which enable a correct diagnosis to be made preoperatively. These are: (1) the existence of a rubbery, tender, and movable tumor in the knee of a young person; (2) intermittent swelling and pain, (3) an unusually sensitive tumor mass; (4) a mass that decreases in size with elevation of the extremity and increases

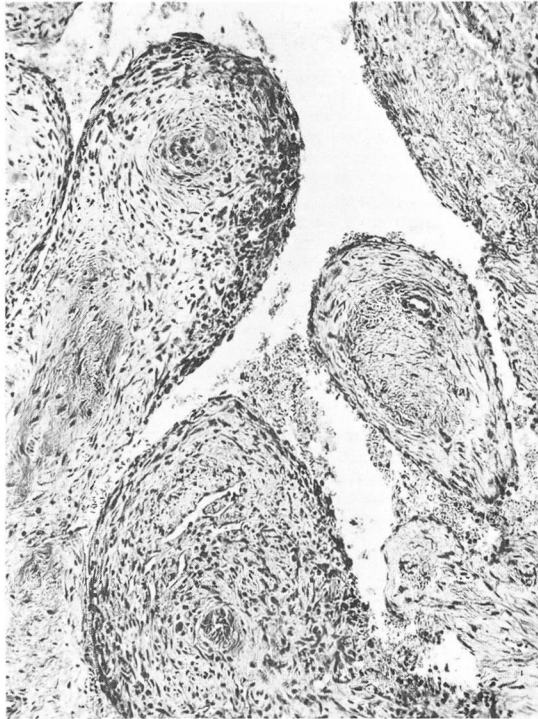


Fig. 2. Case 3. Photomicrograph of a section of the tumor, showing the endothelial-lined spaces. Hematoxylin-eosin stain; magnification X100.

with standing; (5) slight limitation of motion of the involved knee, associated with quadriceps atrophy and a limp; and (6) prior trauma as an aggravating factor. Laboratory studies and roentgenograms are not specific enough for a definitive diagnosis.

The differential diagnoses to be considered include internal derangement of the knee, rheumatoid arthritis, pigmented villonodular synovitis, infectious arthritis, tuberculosis, syphilis, and hemorrhagic diathesis.⁵

The treatment of hemangiomas elsewhere in the body has included observation only, in the hope of spontaneous regression, the injection of sclerosing substances to convert the vascular tumor mass into scar tissue,⁶ electrocautery or the use of carbon dioxide snow in superficial hemangiomas, irradiation,⁷ and surgical excision of the tumor mass.

Spontaneous regression of cavernous hemangiomas is not uncommon in some tissues, but because of the pain associated when this tumor is present in a weight-bearing joint, observation in anticipation of spontaneous regression is not acceptable either to the patient or to the physician. Intraarticular injection of sclerosing substances into the tumor mass is contraindicated because of possible damage to

joint structures. Electrocautery and the use of freezing substances are not applicable to other than the most superficial hemangiomas. Irradiation was used by Bennett and Cobey³ for lesions considered to be too extensive for surgical excision. However, such treatment is contraindicated in a growing child because of the radiosensitivity of epiphyses and the risk of permanent disturbance of growth in the extremity. Surgical excision of the tumor and its synovial attachments remains the most successful therapy.^{8, 9}

Summary

Three cases of cavernous hemangiomas of the synovial membrane in the knee joint are reported. This uncommon tumor presents certain characteristic clinical features, which, combined with a high index of suspicion on the part of the clinician, allow early recognition and preoperative diagnosis. Surgical excision is the preferred treatment.

References

1. O'Ferrall, J. T.: Hemangiomas of knee joint. *J.A.M.A.* **85**: 505-508, 1925.
2. Weaver, J. B.: Hemangiomas of lower extremities; with special reference to those of knee-joint capsule and phenomenon of spontaneous obliteration. *J. Bone & Joint Surg.* **20**: 731-749, 1938.
3. Bennett, G. E., and Cobey, M. C.: Hemangioma of joints; report of five cases. *Arch. Surg.* **38**: 487-500, 1939.
4. Karlholm, S., and Stjernswärd, J.: Hemangioma of knee joint. *Acta orthop. scandinav.* **33**: 306-311, 1963.
5. Lewis, R. C., Jr.; Coventry, M. B., and Soule, E. H.: Hemangioma of synovial membrane. *J. Bone & Joint Surg.* **41-A**: 264-271, 1959.
6. Baurmash, H., and Mandel, L.: Nonsurgical treatment of hemangioma with Sotradecol. *Oral Surg.* **16**: 777-782, 1963.
7. Nordberg, U. B., and Sundberg, J.: Indications and methods for radiotherapy of cavernous hemangiomas. Study of 1191 hemangiomas following radiotherapy. *Acta radiol.* **1**: 257-274, 1963.
8. Wallace, G. T., and Ghormley, R. K.: Cavernous hemangioma of knee. *Proc. Staff Meet. Mayo Clin.* **18**: 177-182, 1943.
9. Harmon, P. H.: Hemangioma of synovial membrane of knee joint cured by synovectomy. *Arch. Surg.* **47**: 359-363, 1943.