

## THE CLINICAL PICTURE

**ABDUL HAMID ALRAIYES, MD**

Pulmonary Disease, Critical Care, and Environmental Medicine, Tulane University School of Medicine, New Orleans, LA

**M. CHADI ALRAIES, MD**

Department of Hospital Medicine, Medicine Institute, Cleveland Clinic

**FRANCISCO AÉCIO ALMEIDA, MD, MS**

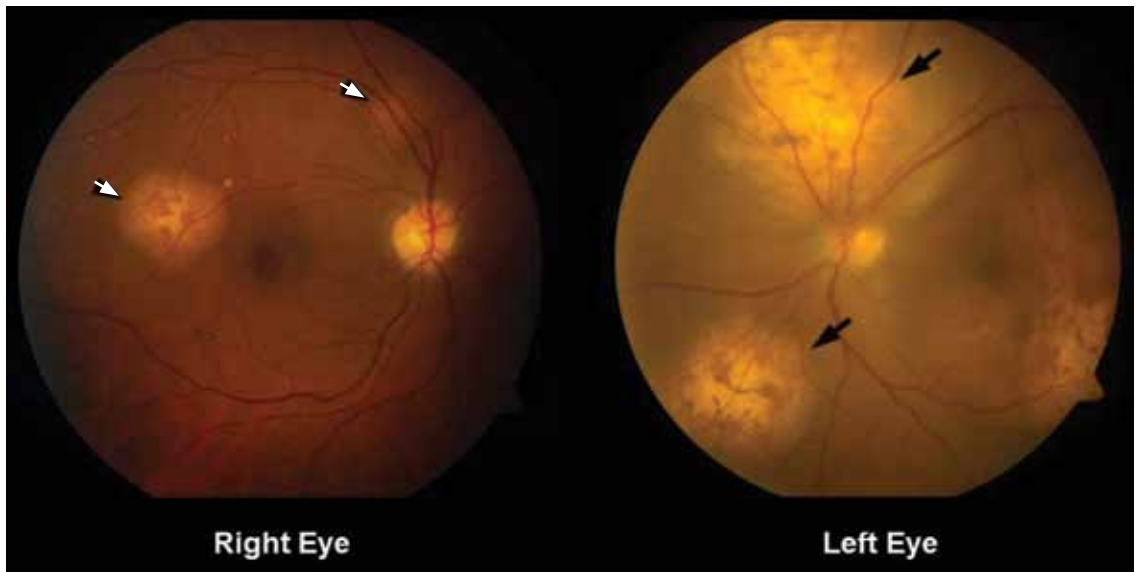
Pulmonary, Allergy, and Critical Care Medicine, Respiratory Institute, Cleveland Clinic

**ARUN D. SINGH, MD**

Department of Ophthalmic Oncology, Cole Eye Institute, Cleveland Clinic

# The Clinical Picture

## Flashing lights, floaters, and reduced vision



**FIGURE 1.** Funduscopy showed multiple lobulated, yellowish choroidal lesions in the posterior pole, with overlying subretinal fluid (arrows). Similar but smaller lesions were seen in the right eye (arrows).

The disease tends to present bilaterally and to involve the central nervous system

**A** 62-YEAR-OLD WOMAN has had flashing lights and floaters in her left eye with progressive loss of vision over the past month. She has not had recent trauma. She does not smoke.

She was referred for an ophthalmologic evaluation. Her visual acuity was 20/20 in the right eye, but she could only count fingers with the left. The anterior segment appeared normal in both eyes. Funduscopic examination of the left eye revealed numerous lobulated, yellowish, choroidal lesions in the posterior pole with overlying subretinal fluid. The lesions involved the fovea, accounting for the poor visual acuity. There were two similar but smaller lesions in the right eye (**FIGURE 1**).

doi:10.3949/ccjm.79a.11141

Ultrasonography confirmed the choroidal location of the lesions (**FIGURE 2**).

**Q:** Which is the most likely diagnosis?

- Retinal detachment
- Choroidal melanoma
- Uveitis
- Uveal metastatic tumor

**A:** Uveal metastatic tumor is the correct diagnosis. Funduscopic findings of bilateral yellow choroidal lesions are consistent with metastatic cancer.

The patient was admitted to the hospital for a thorough evaluation. Computed tomography of the chest showed a 2.1-by-4.5-cm mass in the lower lobe of the left lung, highly

suspicious for malignancy and associated with left hilar lymphadenopathy and right acute pulmonary embolism. Bronchoscopy showed an endobronchial tumor completely occluding the left lower lobe and the lingular orifices.

Pathologic specimens from the endobronchial tumor confirmed adenocarcinoma, consistent with a primary lung cancer.

### ■ THE OTHER DIAGNOSTIC CHOICES

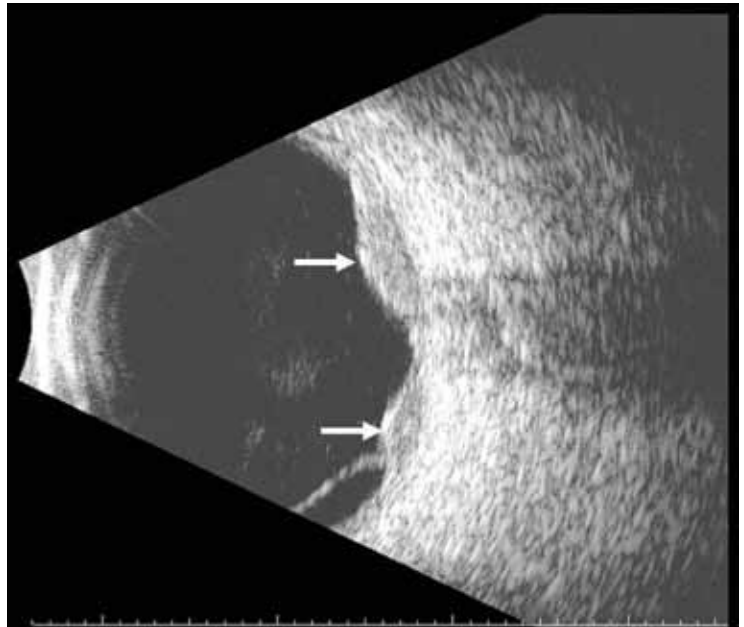
**Detachment** or separation of the retina from the underlying pigment epithelium is one of the most commonly encountered eye emergencies.<sup>1</sup> It requires urgent attention, since delay in treatment can cause permanent vision loss.

Retinal detachment differs from uveal metastatic tumor in that it presents and progresses rapidly. The common signs and symptoms are floaters in the center of the visual axis, a sensation of flashing lights (related to retinal traction), and, eventually, loss of vision. The detachment most often represents a break or tear (rhegmatogenous retinal detachment), but it is also a common sequela of neglected diabetic retinopathy. Exudative retinal detachment is usually secondary to uveal inflammation or a uveal tumor.

**Choroidal melanoma**, the most common primary intraocular malignancy, arises from melanocytes within the choroid. In most cases, it develops from preexisting melanocytic nevi.<sup>2</sup> It may present as blurred vision, a paracentral scotoma, painless and progressive visual field loss, and floaters. Choroidal melanoma is usually pigmented (dark brown) and is invariably unilateral.

**Uveitis** is an inflammation of the uveal tract, which includes the iris, ciliary body, and choroid. It is classified as anterior, intermediate, or posterior uveitis or as panuveitis.<sup>3</sup>

Although flashing lights, floaters, and reduced vision can occur in uveitis, its other important presenting symptoms (ie, pain, redness, and photophobia) were absent in this patient. The absence of anterior chamber cells and corneal inflammatory deposits (keratic precipitates) also made uveitis less likely.<sup>4</sup> However, granulomatous uveitis such as sarcoidosis can present as nodular thickening of the uvea, mimicking an intraocular tumor.<sup>5</sup>



**FIGURE 2.** Ultrasonography of the left eye confirmed the choroidal location of the lesions noted on funduscopy (arrows).

### ■ THE MOST COMMON INTRAOCULAR MALIGNANCY

Uveal metastasis is the most common intraocular malignancy<sup>6</sup> and is found on autopsy in up to 12% of people who die of cancer; it involves both eyes in 4.4% of cases. Multiple metastases are seen in one eye in up to 20% of cases.<sup>7</sup>

The tumors are most often in the choroid, probably because of its extensive blood supply. Breast cancer (in women) and lung cancer (in men) are the most common cancers with uveal metastasis.<sup>8</sup> Uveal metastasis from cancers of the prostate, kidney, thyroid, and gastrointestinal tract and from lymphoma and leukemia is less common.<sup>8</sup>

Patients with choroidal metastasis can see flashing lights, floating spots, and distortion of their vision. In such patients, a careful history and physical examination can uncover signs and symptoms of the hidden cancer, especially of lung cancer.<sup>9</sup>

Once uveal metastasis is suspected, both eyes and orbits and the central nervous system should be examined, as this disease tends to present bilaterally and to involve the central nervous system.<sup>10</sup> Uveal metastases respond to chemotherapy and radiotherapy, depending on

## Tuberculosis Testing in the 21st Century: The Role of Interferon- Gamma Release Assays Webcast Series

### TB testing has evolved – has your practice?

The *Tuberculosis Testing in the 21st Century* webcast series is designed for healthcare professionals with an interest in a multidisciplinary approach to the screening and prevention of TB.

This complimentary 5-part educational series features expert faculty presenting the following topics:

#### 100 Years of TB Testing

John J. Cush, MD  
Baylor Research Institute

#### Tuberculosis in 20 Minutes

Kevin L. Winthrop, MD, MPH  
Oregon Health & Science University

#### Tuberculosis and Biologics: Relating Mechanisms of Action to Immunopathogenesis of Granulomatous Infections

Xavier Mariette, MD  
Université Paris-Sud, France

#### Detection of Latent TB Infection in the Immunosuppressed Patient: Defining the Utility of IGRA in Vulnerable Populations

Arthur Kavanaugh, MD  
University of California, San Diego

#### Tuberculosis Testing in the 21st Century Interactive Case Discussion

Moderator: Leonard H. Calabrese, DO  
Cleveland Clinic

These activities have been approved for  
AMA PRA Category 1 Credit™.

The Cleveland Clinic Foundation Center for  
Continuing Education acknowledges  
an educational grant for support of this activity  
from Cellestis, a QIAGEN Company.

Participate Today!

[www.ccfme.org/tb-testing](http://www.ccfme.org/tb-testing)

## REDUCED VISION

the nature of the primary tumor. In general, treatment is based on the extent of the metastasis, prior treatments, and the patient's overall functional status. ■

### REFERENCES

1. Hatten B, Brown V. Retinal detachment. *Emerg Med J* 2011; 28:83.
2. Factors predictive of growth and treatment of small choroidal melanoma: COMS Report No. 5. The Collaborative Ocular Melanoma Study Group. *Arch Ophthalmol* 1997; 115:1537–1544.
3. Jabs DA, Nussenblatt RB, Rosenbaum JT; Standardization of Uveitis Nomenclature (SUN) Working Group. Standardization of uveitis nomenclature for reporting clinical data. Results of the First International Workshop. *Am J Ophthalmol* 2005; 140:509–516.
4. Wertheim MS, Mathers WD, Planck SJ, et al. In vivo confocal microscopy of keratic precipitates. *Arch Ophthalmol* 2004; 122:1773–1781.
5. Desai UR, Tawansy KA, Joondeph BC, Schiffman RM. Choroidal granulomas in systemic sarcoidosis. *Retina* 2001; 21:40–47.
6. Singh AD, Damato BE, Pe'er J, Murphree AL, Perry JD, eds. Uveal metastatic tumors. In: *Clinical Ophthalmic Oncology*. Philadelphia, PA: Saunders-Elsevier; 2007:322–327.
7. Eliassi-Rad B, Albert DM, Green WR. Frequency of ocular metastases in patients dying of cancer in eye bank populations. *Br J Ophthalmol* 1996; 80:125–128.
8. Shields CL, Shields JA, Gross NE, Schwartz GP, Lally SE. Survey of 520 eyes with uveal metastases. *Ophthalmology* 1997; 104:1265–1276.
9. Herrag M, Lahmiti S, Yazidi AA, Le Lez ML, Diot P. Choroidal metastasis revealing a lung adenocarcinoma. *Ann Thorac Surg* 2010; 89:1013–1014.
10. Kanthan GL, Jayamohan J, Yip D, Conway RM. Management of metastatic carcinoma of the uveal tract: an evidence-based analysis. *Clin Exp Ophthalmol* 2007; 35:553–565.

ADDRESS: M. Chadi Alraies, MD, Department of Hospital Medicine, A13, 9500 Euclid Avenue, Cleveland, OH 44195; e-mail [alraiec@ccf.org](mailto:alraiec@ccf.org).

## Copyright Compliance

Permission to reproduce articles from the *Cleveland Clinic Journal of Medicine* may be obtained from:

Copyright Clearance Center  
1-800-982-3887, ext. 2862  
[marketing@copyright.com](mailto:marketing@copyright.com)  
[www.copyright.com](http://www.copyright.com)