Epiphyseal injuries in athletes

H. Royer Collins, M.D.

Department of Orthopaedic Surgery

Athletics play an important role in the lives of our children and adolescents, with more and more participation in an increasing number of contact and noncontact sports by boys and girls. There has been much controversy over participation in contact sports at an early age. Although many reasons have been given, in the final analysis the only valid criticism is that injury can occur. It would be naive for us to hide our heads in the sand and pretend that injuries do not occur. There are definite risks in all types of sports, contact or not, also in any active form of entertainment or play. However, tangible and intangible benefits can be gained from participation in sports.

Much criticism has been leveled against competitive sports at the elementary and junior high levels. Although it had been claimed that many epiphyseal injuries occur at this age, the first good study on this subject was not made until 1966 when Larson and McMahan[1] reported on 1,338 athletic injuries in their experience. They found that 20% of the injuries occurred in the age group under 14 years, and 40% in the group from 15 to 18 years of age. Sixty percent of the school population was of elementary and junior high school age, 15% in the high school age group, and

the greatest number of injuries occurred in the smallest population sample, the high school students. Of these injuries, 6% were epiphyseal in students younger than 15 years. In my study[2] of a 7-year period in one school system in Texas, 234 injuries occurred in junior high, grades 7 through 9. It is interesting that most injuries occurred in youngsters in the 9th grade; the least in the 7th grade; however, the injuries sustained by the younger children were not as severe, possibly because younger children do not hit as hard as those who are older, and if one observes these youngsters play, it becomes obvious that this is so. It is said that serious injuries become more common when "boys attain that point of development physically and emotionally where they are willing to run head on into each other or a stone wall without even changing their expressions." [3] This seems to occur in the age range of 14 to 18 years. Only three injuries in this group of 234 were epiphyseal injuries, one was a separation of the proximal/humeral epiphysis, one a separation of the distal radial epiphysis, and one an injury to the calcaneal apophysis sustained playing basketball.

Rather than adopt a pessimistic viewpoint, Larson and McMahan[1] have stressed the value of recognizing injury and administering proper treatment as well as the value of "pre-participation physical examinations, body conditioning and warmup drills, instructions in techniques of safety regulated protective equipment and officiating, and instant medical care administered either as first aid by the coaches or in many instances by a doctor in attendance at games." Larson[4] subsequently reviewed the incidence of injuries in 4,854 athletes in his group's practice and found 138 conditions involving epiphyses, with 84 being epiphyseal sprains, fractures or dislocations and 54 other epiphyseal conditions, primarily epiphysitis. Despite this low number of epiphyseal injuries and the fact that most epiphyseal injuries sustained in sports in this age range tend to be Grade I or II, it is important to understand the pathology and mechanism of injury, to be able to make a prompt diagnosis, and to institute early definitive treatment to avoid any growth disturbance should injury occur.

Anatomy

The epiphyseal plate is composed of four zones: the first is the zone of resting cells lying immediately adjacent to the epiphysis. These cells act as a reservoir for future growing cartilage. The second zone is the zone of proliferation in which growth and division of cells occur. The third zone is the zone of hypertrophied cells or the zone of provisional calcification and is the weakest part of the epiphyseal plate through which separation usually occurs. In this zone, the cells begin to hypertrophy and degenerate. Calcification of the cartilaginous matrix begins but osteogenesis has not occurred yet. The fourth zone is the zone of enchondral ossification, and it is characterized by the appearance of osteoblasts, replacement of dying cartilage cells by trabeculae of bone and the outgrowth of capillaries from the metaphysis.[5] Fortunately, the usual separation through the zone of provisional calcification does not interfere with the blood supply, nor does it tend to interfere with the zone of resting cartilage cells so that, in most in-

stances, there is no disturbance of growth.

Classification of epiphyseal fractures

Many classifications have been recommended. We prefer to use the one devised by Salter and Harris.[6] In their classification, Type I fractures are those in which there is separation through the epiphyseal plate without any bony involvement. Type II fractures involve separation through the epiphyseal plate with fracture through the metaphysis with a small triangular fragment of bone being carried along with the epiphyseal line on the edge of the metaphysis. In Type III fractures, the fracture line traverses the epiphysis vertically and then along the epiphyseal plate. Type IV fractures cross through the epiphyseal plate and into the metaphysis, and Type V fractures are crush injuries to the epiphyseal plate. Most epiphyseal fractures in athletes, as mentioned, are Type I or II. In Larson's series,[4] Types I and II fractures accounted for 82% of the epiphyseal fractures.

Review of patients

Patients examined at the Cleveland Clinic's Sports Injury Clinic between April 1973 and November 1974 were evaluated. In 2,137 cases, 58 epiphyseal injuries were found. By far the greatest number of epiphyseal injuries (34) involved the proximal tibial tubercle and were traction epiphyseal injuries, the so-called Osgood Schlatter's disease; the remainder involved other regions of the body as noted in the *Table.*

Table. Epiphyseal injuries, April 1973 to November 1974

Proximal humeral epiphyseal fracture	1
Medial epicondylitis	2
Radial head epiphyseal fracture	1
Distal radial epiphyseal fracture	4
Scheuermann's epiphysitis	5
Avulsion ischial apophysis	1
Iliac apophysitis	1
Slipped capital femoral epiphysis	1
Distal femoral epiphyseal fracture	1
Proximal tibial epiphyseal fracture	1
Osgood Schlatter's disease	34
Ankle epiphyseal fracture	2
Distal fibular epiphysis fracture	3
Os calcis apophysitis	1
Total	58

Humerus. There was one proximal humeral epiphyseal injury in a football player (*Fig. 1*). The mechanism of injury in these cases is similar to that which would produce a dislocation of the shoulder. The deformity which is produced is usually caused by muscle attachments. Fusion of this epiphysis does not occur until late, often at 18 years of age or later, and therefore sufficient time remains for growth and remodeling. Anatomical reduction is not necessary in this type of epiphyseal separation, and Neer and Horwitz[7] have stated that in their clinic in the past 10 years, none of these injuries had to be opened. Reduction can usually be achieved by bringing the distal fragment into abduction and external rotation, approximating it to the proximal fragment. If reduction is stable, the arm may be brought down to the side and an arm immobilizer or sling and swathe-type dressing may be used. If reduction cannot be maintained, it may be necessary to keep the patient in traction with the arm out in abduction to keep that position. If reduction cannot be obtained in this fashion, 45 degrees or more of angulation can be accepted without the necessity for open reduction. Healing of

Fig. 1. Epiphyseal fracture, proximal humerus.

epiphyseal fractures usually occurs in 3 to 4 weeks, so that immobilization is necessary for only this period of time.

Elbow. Much has been written about Little League elbow and problems which can occur to the epicondylar epiphyses as a result of the throwing motion. Adams[8] described a high incidence of problems in the elbow of Little League baseball players, but we have not seen the same incidence of Little League elbow in this area. A more recent study by Larson and Tullos which is still unpublished indicates that epicondylitis and other problems in the elbow do not seem to occur frequently in the Little League age range but, in fact, occur later. In our series reviewed during this period, only three patients had elbow problems; two were medial epicondylitis as a result of throwing, and one was a fracture of the proximal radial head epiphysis as a result of a fall while playing football (*Fig. 2*). About 30 degrees of angulation of the radial head epiphysis can be accepted since this will remodel with growth, but if there is significant displacement of the radial head epiphysis, this must be reduced. It is often necessary to pin the radial head with a Kirschner wire extending from the distal humerus across the joint and impaling the radial head so that it remains fixed on the shaft of the radius. It is obvious that there

Fig. 2. Epiphyseal fracture, radial head.

must also be some external fixation to prevent breakage of the Kirschner wire; the Kirschner wire must be removed prior to allowing motion of the elbow joint. In patients with so-called Little League elbow, if the symptoms become apparent early and there is not much destruction in the elbow joint, rest is all that is required. If, however, symptoms are severe and if there already have been changes in the capitulum as a result of compression by the radial head with loose bodies in the joint, surgery may be indicated. Surgery is also necessary when there is intraarticular fracture with displacement of the epiphyseal centers, or in cases in which the medial epicondyle has been fractured with significant displacement, and particularly with interposition of the medial epicondyle into the joint.

Forearm. Fractures of the distal radial epiphysis are the most common epiphyseal fractures (*Fig. 3*). These occur as a result of falling on the outstretched arm, and in our series accounted for four of the epiphyseal injuries, two resulting from playing football and one from bike riding. Closed reduction usually is sufficient for these fractures. Anatomical reduction is not absolutely essential, and good results may be obtained provided there is 50% apposition and good alignment. Some small amount of angulation may be accepted if there is a significant period of growth remaining.

Pelvis. Epiphyseal injuries in the region of the pelvis are generally traction epiphyseal injuries as a result of avulsion of the apophyses by strong muscular contraction (*Fig. 4*). The anterior superior spine may be involved due to pull by the sartorius, the anterior inferior spine due to pull by

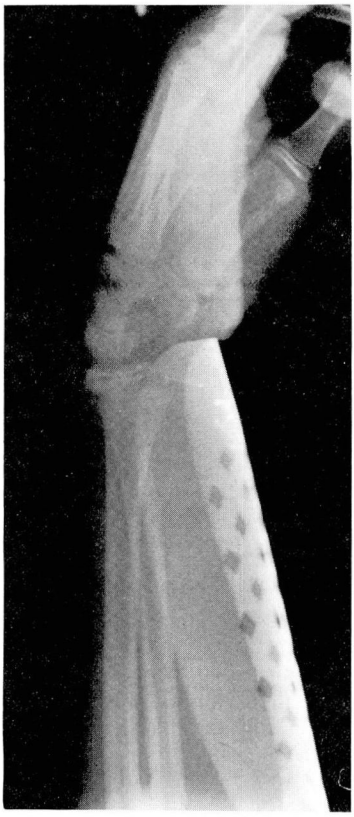

Fig. 3. Fractured distal radial epiphysis.

the rectus femoris, the lesser trochanter due to pull by the iliopsoas, and the iliac apophysis may be involved when the hamstrings exert an excessive force. In our series, one cheerleader suffered an avulsion of an ischial apophysis, and there was one incidence of iliac apophysitis as a result of track participation.

Hip. Slipping of the femoral capital epiphysis, not an uncommon problem in adolescence, may occur while the youngster is participating in sports (*Fig. 5A and B*). This may mimic problems with the knee, and we have seen youngsters who have had menisectomy performed because of knee pain when their true problem was slipping of the femoral capital epiphysis. It is important to examine thoroughly the athlete with knee complaints to be certain that he does not have any limitation of hip motion and that his problem is not arising from the hip. Treatment in these cases is the same as in all cases of slipped capital femoral epiphysis.

Knee. Fractures of the distal femoral epiphysis occur as a result of the same mechanism which produces injuries to the ligaments in older youngsters. The ligaments are two to five times as strong as the epiphyseal line and as long as the epiphyseal line is open, blows to the side of the knee tend to injure the epiphysis rather than the ligament. As long as the distal femoral epiphysis is open, it is necessary to get stress x-rays to rule out the possibility of epiphyseal injury, because the treatment is entirely different from that of ligamentous tears. If there is no displacement of the epiphysis, the patient may be treated in a cast without reduction. Often, however, there is considerable displacement and closed reduction is necessary. It is necessary to flex the hip as well as the knee to achieve reduction in these cases. Once reduction is achieved, these injuries tend to be notoriously unstable and, although the patient may be placed in a hip spica cast, reduction may be lost. To avoid this complication, roentgenograms should be done frequently in the early postreduction period. If the reduction is too unstable, we prefer to put a Kirschner wire across the epiphysis and into the metaphysis to maintain the reduction, keeping this in place for a 3-week period. In these injuries, attention must be directed to the circulation in the lower extremities at all times because of the possible

Fig. 4. Avulsion, ischial apophysis.

vascular and neurovascular problems which may occur. If anatomical reduction of the articular surface cannot be achieved by closed methods, then open reduction with internal fixation is necessary. Fortunately, most of these injuries tend to occur just before the epiphysis closes so that even if there is growth disturbance, loss of bone length is not noticeable. However, occasionally growth disturbance will occur, resulting in either varus or valgus deformities of the knee and, at times, loss of considerable length of the femur. This may necessitate osteotomies of the involved leg and premature closure of the epiphysis of the opposite extremity to balance out the leg lengths. Injury of the proximal tibial epiphysis is much less common because the ligaments insert distal to the epiphysis and do not attach directly on it. However, there was one injury to the proximal tibial epiphysis in this series. Treatment is as outlined for the distal femoral epiphysis. The most common affliction of the epiphyses was Osgood Schlatter's disease (*Fig. 6*). This is really an avulsion of the tibial tubercle epiphysis caused by the strong pull of the quadriceps mechanism at this point. There may not be any apparent evidence of displacement of the tibial tubercle on the roentgenogram, and all that one may have are signs of irritation and some swelling, enlargment, and tenderness of the tibial tubercle on physical examination. Treatment in most instances is conservative, allowing the youngster to rest from a sport for a short period of time until he becomes asymptomatic. If he is able to participate in a sport without any discomfort, despite having the prominence of the tibial tubercle, we allow the youngster to participate. Occasionally, it becomes necessary to treat these patients with

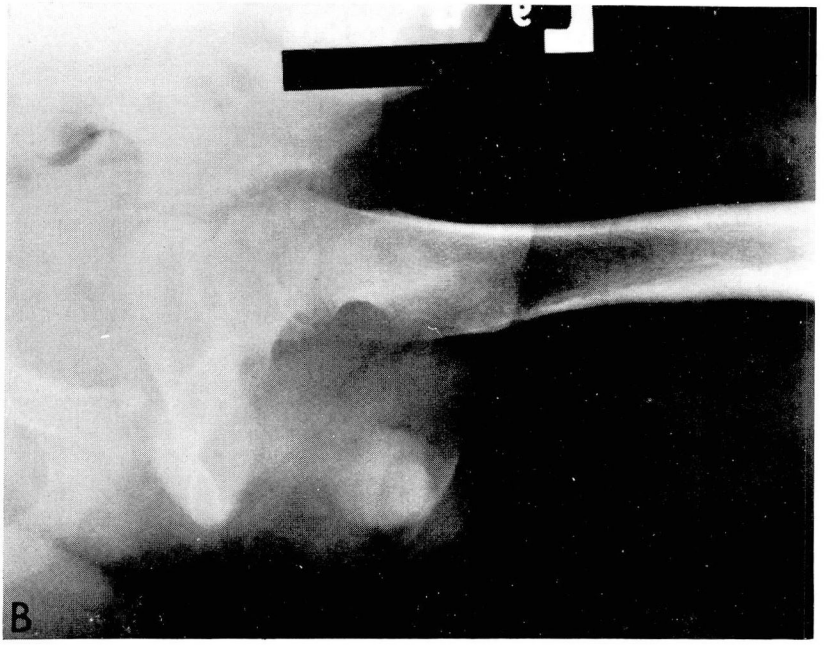

Fig. 5. A, Slipped capital epiphysis, anteroposterior view. **B,** Slipped capital epiphysis, lateral view.

Fig. 6. Osgood Schlatter's disease.

plaster cast immobilization for 6 weeks; cortisone injections are sometimes required to ease the symptoms. In most instances, all that is needed is protection of the bony prominence, which is quite tender; the use of pads to allow participation; and reassurance to the parents that no intraarticular damage is being done.

Ankle. Epiphyseal fractures of the ankle occurred in five of our patients. This also occurs in lieu of ligamentous injuries to the ankle, as the epiphysis is again the weakest link in the chain. There may not be any displacement of the epiphyseal centers seen on the roentgenogram, and the fibula may be all that is involved. Tenderness at the point of the distal fibular epiphysis is the clue to the diagnosis. Even though the roentgenogram may not show any displacement, if there is tenderness over the distal fibular epiphysis (not over the ligaments themselves), one must treat this injury as a distal fibular epiphyseal fracture until proven otherwise. Injury to the distal tibial epiphysis may occur and growth disturbances can also occur in these instances, which may lead to some deformity in the ankle. Good articular surface reduction is necessary to prevent any problems in the future.

Foot. There was one case of os calcis apophysitis in our series. This is most often a clinical diagnosis with the symptoms a result of constant pull of the Achilles tendon on the os calcis.

Fig. 7. Scheuerman's eiphysitis, dorsal spine.

Roentgenography may not show anything significant. This condition is generally self-limiting and should be treated by wearing good shoes with heel pads and avoiding vigorous activities until symptoms have subsided.

Spine. In this age range the most common condition in the spine is Scheuermann's epiphysitis (*Fig. 7*). This condition will often be precipitated by the onset of weight training, or may flare up as the result of a fall or a blow to the spine. In our series there were five cases of Scheuermann's epiphysitis with three of these occurring during football, one during wrestling, and one during track. Participation in athletics is not necessarily contraindicated and treatment is symptomatic. As soon as the pain has subsided, the athlete is capable of doing anything that he had been doing before, but we attempt to avoid weight lifting maneuvers which put a stress upon his back and may cause increasing symptoms. If the Scheuermann's epiphysitis is extremely severe with wedging of the dorsal vertebrae, it may be necessary for the youngster to be placed in a Milwaukee Brace to prevent severe deformity; in these in-

stances athletic participation must be avoided. However, we have found that most youngsters are capable of continuing participation in athletics. Occasionally, they may have to wear a brace, but the disease entity is self-limiting.

Summary

Epiphyseal injuries occur as a result of participation in athletics, but the incidence is no more than one would expect in other activities, such as riding bicycles. It is important that one be aware of the possibility, so that early diagnosis and definitive treatment can be made. Parents must be alerted to the possibility of growth disturbance, and patients who incur these injuries must be followed to correct any deformity that might occur.

References

1. Larson RL, McMahan RO: The epiphyses and the childhood athlete. JAMA **196:** 607–612, 1966.
2. Collins HR: Contact sports in junior high school. Tex Med **63:** 67–69, 1967.
3. Quinby WC Jr, Truman JT, Connelly JP: Athletic injuries in chidren. Clin Pediatr (Phila) **3:** 533–540, 1964.
4. Larson RL: Epiphyseal injuries in the adolescent athlete. Orthop Clin North Am **4:** 839–851, 1973.
5. Harris WR: Epiphysial injuries. Instructional Course Lectures, American Academy of Orthopaedic Surgeons, **XV:** 206–214, 1958.
6. Salter RB, Harris WR: Injuries involving the epiphyseal plate. J Bone Joint Surg **45-A:** 587–622, 1963.
7. Neer CS II, Horwitz BS: Fractures of the proximal humeral epiphyseal plate. Clin Orthop Rel Res **41:** 24–31, 1965.
8. Adams JE: Injury to the throwing arm; a study of traumatic changes in the elbow joints of boy baseball players. Calif Med **102:** 127–132, 1965.