

Head and neck spindle cell carcinoma: an evaluation of current management

MICHAEL S. BENNINGER, MD; DENNIS KRAUS, MD; BRUCE SEBEK, MD; HARVEY M. TUCKER, MD; PIERRE LAVERTU, MD

■ Spindle cell carcinoma is an unusual variant of squamous cell carcinoma. The histogenesis of these tumors is controversial, as is the prognosis for patients with spindle cell carcinoma of the head and neck when compared with all squamous cell carcinomas of these sites. Fifteen consecutive nondermal cases of spindle cell carcinoma of the head and neck were reviewed. Six patients had spindle cell carcinoma either in recurrent tumor or in neck metastases following treatment for squamous cell carcinoma where a spindle cell component was not initially noted. Despite aggressive management, 13 patients have died from their disease. The histogenesis and management of spindle cell carcinoma of the head and neck are discussed.

□ INDEX TERMS: CARCINOMA; HEAD AND NECK NEOPLASMS □ CLEVE CLIN J MED 1992; 59:479-482

SPINDLE CELL CARCINOMAS of the head and neck are unusual neoplasms that are histologically biphasic, having both a squamous cell carcinoma and an apparently malignant spindle cell or sarcomatous element.¹⁻³ Controversy as to the histogenesis of these tumors has resulted in diverse terminology to describe them; these terms include sarcomatoid carcinoma,² pseudosarcoma,⁴ carcinosarcoma,⁵ and spindle cell carcinoma.³ The clinical course and natural history of these tumors are also controversial: superficial tumors have a good prognosis,^{2,5} whereas invasive tumors have a prognosis worse than all squamous cell carcinomas of similar sites.^{6,7} The role of radiation therapy in treating spindle cell carcinoma is also questionable.^{6,8}

The purpose of this study was to evaluate the clinical course, treatment, prognosis, and histogenesis of spindle cell carcinoma of the head and neck.

From the Department of Otolaryngology and Communicative Disorders (M.S.B., D.K., H.M.T., P.L.) and the Department of Pathology (B.S.), The Cleveland Clinic Foundation.

Address reprint requests to P.L., Department of Otolaryngology and Communicative Disorders, The Cleveland Clinic Foundation, 9500 Euclid Avenue, Cleveland, OH 44195.

MATERIALS AND METHODS

The charts of all patients with nondermal spindle cell carcinoma of the head and neck who presented to The Cleveland Clinic Foundation between 1978 and 1987 were retrospectively reviewed. Information on the presentation, site, stage, treatment, and prognosis of these tumors was accumulated. Histopathological specimens from all patients were reviewed. Cases were included only if they contained both a squamous cell carcinoma and a spindle cell component (*Figure 1*).

RESULTS

The study group consisted of 15 patients (9 women, 6 men). Their ages ranged from 32 to 76, with a mean age of 61. Thirteen patients were white, 1 was black, and 1 was Asian. Six patients had a history of tobacco use; 3 of these also had a significant use of alcohol.

Sites and staging of the lesions are listed in *Table 1*. There were five stage I, one stage III, and three stage IV tumors; one patient had local excision prior to presentation, but this did not prevent staging. Six patients had received previous therapy which

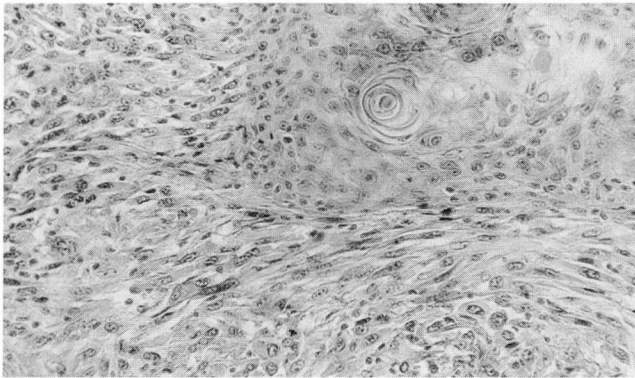


FIGURE 1. Spindle cell carcinoma, showing the transition of conventional squamous cell carcinoma into malignant spindle cell elements.

prevented staging. Of this latter group, five were treated for cure with radiation therapy and one had surgery, the failure of which prompted referral.

After presentation, 13 patients were treated with surgery—3 as the sole management, 5 in combination with radiation therapy, 1 as a planned palliative procedure, 3 after failure of radiation for cure, and 1 treated with combined surgery and radiation therapy for a head and neck primary tumor and surgical lobectomy for a solitary lung metastasis. Two patients presented with unresectable disease.

Specimen margins were free of tumors in 11 patients. Of two specimens with positive margins, one was in the patient who had received palliative surgical therapy. Squamous cell carcinoma was poorly differentiated in 13 specimens and moderately differentiated in 2. There were no well-differentiated carcinomas.

Twelve patients underwent radiation therapy in the course of treatment. Of these, 7 had radiation for cure initially (5 prior to presentation), and 5 had planned combined radiation and surgical therapy (4 postoperatively and 1 preoperatively).

Nine patients were diagnosed with spindle cell carcinoma at the time of their original treatment. Four others were noted to have spindle cell carcinoma in specimens obtained only after recurrence. These four patients were treated prior to presentation, three with radiation therapy and one with surgical excision. Original histopathological specimens were available for two of these patients; in these biopsies, no spindle cell carcinoma was noted. Two patients were noted to only have spindle cell carcinoma in neck metastases, but one underwent biopsy only for the primary lesion and was subsequently treated with radiation prior to

TABLE 1
TUMOR SITE AND STAGING FOR 15 PATIENTS

Primary site	
Oral cavity	6
Oropharynx	2
Nasopharynx	1
Maxillary sinus	2
Larynx-supraglottic	1
Larynx-glottic	2
Hypopharynx	1
TNM staging	
T1, N0, M0	5
T2, N0, M1	1
T3, N0, M0	1
T4, N0, M0	1
T4, N1, M0	1
Prior treatment	6

presentation. The fourth patient was found to have a spindle cell component in a neck metastasis excised 5 months after excision of squamous cell carcinoma of the oral cavity. Review of the original specimen revealed no spindle element. The sites of treatment failure are noted in *Table 2*.

Thirteen of the 15 patients (87%) died of their disease an average of 14.5 months after presentation. One patient with stage I carcinoma of the floor of the mouth died of unrelated causes 40 months after treatment. This individual was treated with local excision and planned postoperative radiation therapy. The remaining patient with stage I laryngeal carcinoma treated with surgery alone is alive and free of disease (both the squamous cell and spindle cell components) 25 months after treatment.

DISCUSSION

Clinical characteristics

The clinical presentation of spindle cell carcinoma of the head and neck is similar to that of squamous cell carcinoma of these sites. Although other series have reported a preponderance of male patients (ratios ranging from 2:1 to 4:1),^{1,2,5} in this series females predominate 1.5 to 1. The mean age of patients (61 years) is consistent with other reported ages (range 4 to 93 years, median between 55 and 65 years).^{2,9} Combining the present report with other series^{1,5} results in the following site distribution: larynx, 32%; oral cavity, 30%; oropharynx, 13%; hypopharynx, 12%; sinonasal, 10%; and nasopharynx, 3%.

Although some have noted a close association between spindle cell carcinoma and exposure to tobacco and alcohol,⁵ only 6 of 15 (40%) patients in this report

TABLE 2
SITES OF TREATMENT FAILURE

Local	3
Regional	2
Distant	2
Local and regional	3
Metastases of presentation	1
Locally unresectable at presentation	2

had used either tobacco or alcohol. A previous series of laryngeal spindle cell carcinoma also reported less-than-expected alcohol and tobacco utilization.¹⁰ The absence of these potentially predisposing factors does not correlate with prognosis.

Histogenesis

The histogenesis of spindle cell carcinoma is controversial. The proposed histogenic mechanisms of the spindle cell component include metaplastic epithelial cells from the malignant squamous cell component or benign mesenchymal stromal reactions,^{1,6} possibly to invasive squamous cell carcinoma. The diagnosis is often difficult when an obvious squamous cell component is absent or in lesions where the squamous cell component is present only at the margins or base of the tumor^{1,3} (Figure 2). Distinguishing spindle cell carcinoma from other spindle cell lesions may be difficult in such cases.³

Immunohistologic staining or cytokeratin and epithelial membrane antigen, which are believed to be characteristic for epithelial cells, have been used to attempt to better classify these tumors. Immunoreactive cytokeratin and epithelial membrane antigen have been noted in the spindle component of most, but not all, tumors.^{1,3,6,7} Furthermore, vimentin, which is felt to be mesenchymal-specific, has been found to be positive in some tumors, while co-expression of vimentin and keratin has been noted in others.^{1,3} Electron microscopic evaluation may show epithelial features in the spindle cells,^{1,6} resulting in epithelial classification. Squamous cell carcinomas can undergo transformations that make them difficult to distinguish from sarcomas, even at the ultrastructural level. This may limit the role of electron microscopy.⁶ Using a combination of immunohistochemical and electron-microscopic observations, evidence for epithelial differentiation in the spindle cells can be found in a majority of tumors.¹ Most authors favor the epithelial nature of these tumors, but the controversy is not yet settled.^{1,3,5-8}

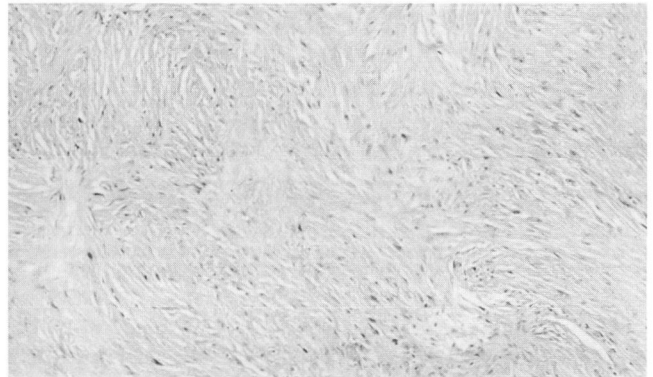


FIGURE 2. Spindle cell carcinoma of the nasopharynx exhibiting marked collagen production and a storiform pattern, making it indistinguishable from a sarcoma. Other areas of the tumor contained conventional squamous cell carcinoma.

Radiation therapy

The role of radiation therapy in spindle cell carcinoma is controversial. Many feel that radiation therapy is not effective in treating these tumors and is associated with frequent recurrences.^{2,5,6,8} Some, however, suggest radiation therapy may play a positive role in therapy.¹¹

One of the difficulties with assessing the role of radiation therapy for cure in these lesions is that a small initial biopsy may not show the spindle element, and, therefore, treatment may be initiated for what is thought to be squamous cell carcinoma alone. If the spindle cell element is noted only in the recurrent tumor, then this may represent selection of patients with poor prognosis. Patients whose biopsies do not reveal the spindle cell element and who were cured by radiation therapy may be considered to have squamous cell carcinoma and not spindle cell carcinoma.

Five patients in the present series were treated for squamous cell carcinoma with full-course radiation therapy based on biopsy results that did not show a spindle cell component. Three of these biopsies were not subsequently reviewed, but the two that were reviewed did not demonstrate spindle cell carcinoma in the original specimens. Although a conventional squamous cell carcinoma could have converted to spindle cell after radiation, since postradiation carcinosarcomas have been reported,¹² it seems more likely that inadequate biopsy failed to reveal the spindle cell element. Also, spindle cell conversion may have occurred in the recurrence without respect to the intervening radiation treatment.

Two patients were noted to have spindle cell car-

cinoma in neck metastases after initial treatment of a primary squamous cell carcinoma. One was initially only biopsied and subsequently treated with radiation therapy, which may raise some of the questions above. The other patient had no spindle component in the primary resected specimen, and a spindle component was noted only in a subsequent neck metastasis. Although unusual, the ability of the spindle cell component to metastasize independently of the carcinomatous element has been reported.^{2,6}

Management and prognosis

Definitive conclusions about the management of spindle cell carcinoma cannot be drawn since the prognosis in this group was universally poor with all therapies. Surgical treatment is the primary mode of therapy, and the use of adjuvant radiation therapy is controversial. It seems reasonable to treat these lesions as one would treat a squamous cell carcinoma of similar size, site, and stage—ie, with surgery and, when appropriate, radiation therapy.

Prognosis in these patients seems to depend primarily on the degree of invasiveness.^{2,5} Superficial tumors have a good prognosis, while more deeply infiltrative tumors result in poor survival.⁵ The only patients in this series who became free of disease were two who had stage I lesions, although three other patients with stage I tumors died from their disease.

The site of the lesion may also correlate with prog-

nosis. Oral cavity⁵ and sinonasal⁶ carcinomas have particularly poor survival. In general, spindle cell carcinoma has a poorer prognosis than squamous cell carcinoma at similar sites.^{6,7} Despite aggressive local and regional management, 87% of the patients in this series have expired from their disease. One patient died of other causes more than 3 years after treatment, and the sole survivor has been followed for only 25 months.

Such poor survival with surgery, radiation therapy, or both, and the higher survival rates in patients with superficial lesions suggests that improved survival may depend on very early diagnosis. Although short-term disease-free survival with chemotherapy has been reported,¹³ the role of chemotherapy remains undetermined. However, immunotherapy or chemotherapy may hold promise where conventional therapy for head and neck cancer has yielded poor results.

CONCLUSION

Spindle cell carcinoma of the head and neck is an aggressive variant of squamous cell carcinoma. Conventional surgical treatment has generally yielded poor results. The role of radiation therapy in treatment remains controversial, and the role of chemotherapy is undetermined. Improved prognosis depends on early and accurate diagnosis with treatment of superficial tumors.

REFERENCES

- Zarbo RJ, Crissman JD, Venkat H, Weiss MA. Spindle-cell carcinoma of the upper aerodigestive tract mucosa: an immunohistologic and ultrastructural study of 18 biphasic tumors and comparison with seven monomorphic spindle-cell tumors. *Am J Surg Pathol* 1986; **10**(11):741-753.
- Weiner N. Sarcomatoid carcinoma of the upper aerodigestive tract. *Semin Diagn Pathol* 1987; **4**(2):157-168.
- Ellis GL, Langloss JM, Heffner DK, Hyams VJ. Spindle-cell carcinoma of the aerodigestive tract: an immunohistochemical analysis of 21 cases. *Am J Surg Pathol* 1987; **11**(5):335-342.
- Lasser KH, Cove H, Faramarz N, Waisman J, Higgins J. "Pseudosarcoma" of the larynx. *Am J Surg Pathol* 1979; **3**(5):397-404.
- Leventon GS, Evans HL. Sarcomatoid squamous cell carcinoma of the mucous membranes of the head and neck: a clinicopathologic study of 20 cases. *Cancer* 1981; **48**:994-1003.
- Batsakis JG, Rice DH, Howard DR. The pathology of head and neck tumors: spindle cell lesions (sarcomatoid carcinomas, nodular fasciitis, and fibrosarcoma) of the aerodigestive tracts, part 14. *Head Neck Surg* 1982; **4**:449-513.
- Leonardi E, Dalri P, Pusioli T, Valdagni R, Pascioli F. Spindle-cell squamous cell carcinoma of head and neck region: a clinicopathologic and immunohistochemical study of eight cases. *ORL J Otorhinolaryngol Relat Spec* 1986; **48**(5):275-281.
- Anonsen C, Dolke RA, Hackman D. Carcinosarcoma of the floor of mouth. *J Otolaryngol* 1985; **14**:215-220.
- Kessler S, Bartley MH. Spindle cell squamous carcinoma of the tongue in the first decade of life. *Oral Surg Oral Med Oral Pathol* 1988; **66**:470-474.
- Goeluner JR, Devine KD, Weiland LH. Pseudosarcoma of the larynx. *Am J Clin Pathol* 1973; **59**:312-326.
- Amail FL. The controversial role of radiotherapy in spindle cell carcinoma (pseudosarcoma) of the head and neck. *Radiat Med* 1985; **3**(4):225-229.
- Hafiz MA, Mira J, Tokar C. Postirradiation carcinosarcoma of the nasal cavity. *Otolaryngol Head Neck Surg* 1987; **97**(3):319-321.
- Colozzo M, Grignani F, Crino L, Tonato M, Davis S. Metastatic spindle cell carcinoma: a complete response induced by cisplatin and 5-fluorouracil. *Anticancer Res* 1988; **8**(3):457-458.