

Changing concepts in the management of testis cancer¹

James E. Montie, M.D.

The emergence of extremely effective chemotherapy for testis cancer has changed many management concepts. Accurate clinical staging may eliminate the need for a node dissection in carefully selected stage I patients. Early detection of metastases is facilitated by using serum markers. Adjuvant chemotherapy after surgery may virtually eliminate recurrences. High-risk patients that respond poorly to standard treatment can be identified at the time of diagnosis; new protocols for this group are being developed. Chemotherapy is an effective treatment for seminoma and is the preferred initial treatment for a high-stage disease. Postchemotherapy surgery can aggravate the pulmonary fibrosis induced by bleomycin; consequently, appropriate precautions must be taken. All of these changes emphasize the importance of a continuing reappraisal by the practicing urologist of treatment philosophies for testis cancer.

Index terms: Drug therapy • Testicular neoplasms

Cleve Clin Q 51:381-385, Summer 1984

¹ Department of Urology, The Cleveland Clinic Foundation. Submitted for publication Dec 1983; accepted Jan 1984. sb

0009-8787/84/02/0381/05/\$2.25/0

Copyright © 1984, The Cleveland Clinic Foundation.

In 1976, my formal training under Dr. Bruce H. Stewart was completed. I feel fortunate that my education under him continued until his death in 1983. By the time I completed my residency at the Cleveland Clinic, potentially curative chemotherapy for testis cancer had just become a well-accepted treatment and, since then, has had a profound effect on the management of all stages of testis cancer.

Diagnosis

A physical examination is the focal point for the diagnosis

of testis cancer. No studies have been developed which do not include an operative exploration for the patient who has a scrotal mass which is suggestive of testicular cancer. Nevertheless, testicular ultrasound has proved valuable for the detection of small cancers in a palpably normal testis of a patient that has a metastatic germ-cell tumor. Although the number of cases reported is quite small, an intratesticular mass that cannot be palpated may be identified on testicular ultrasonograms.^{1,2} Presumed primary extragonadal germ-cell tumors are now correctly categorized as primary testis cancers. It is important to identify the testis as the primary site because the overall prognosis will be better and an orchiectomy will be necessary. Chemotherapy alone cannot eliminate all the cancer in the testis.³

Staging

In 1976, clinical staging evaluations were performed to identify metastases outside the retroperitoneum. Little attention was given to the local characteristics of the primary tumor. The presence or absence of small-volume nodal metastases in the retroperitoneum was not critical because a node dissection was done in all cases. If large bulky retroperitoneal nodes could be identified during a physical examination or on diagnostic radiographs, then chemotherapy was given as initial treatment.

Recently, the clinical staging of testis cancer by using serum-markers (beta-human chorionic gonadotropin [B-HCG], alpha-fetoprotein [AFP], and lactate dehydrogenase [LDH]), excretory urography, abdominal computed tomography (CT), bilateral pedal lymphangiography, and chest CT or whole-lung tomography has become more important. Under classic treatment methods, even if the results of these studies are normal, the patient undergoes at least a unilateral retroperitoneal lymphadenectomy. Consequently, 15%–25% of the patients are found to have either microscopic nodal involvement or small metastatic nodes that were missed during the staging evaluations. This procedure is therapeutic because retroperitoneal recurrences are quite uncommon, and most patients are cured with no further treatment.⁴ Nevertheless, an unnecessary operation was performed in 75%–85% of the patients with normal lymph nodes. Before the advent of curative chemotherapy, all patients underwent a lymphadenectomy because if one waited until grossly positive nodes were evident, the potential for cure by surgery alone was much

lower. The inconvenience, expense, risk, and morbidity of the operation could be readily justified to save the few who did have metastatic disease. Chemotherapy, however, has altered this rationale because patients can be cured, even in the presence of gross metastases. The following plan has been proposed: (a) All available staging modalities should be used in each case to identify metastases; (b) If all studies are *unequivocally normal*, observation only should be carried out; (c) Patients should be evaluated at monthly intervals in the first year and bimonthly during the second year with a physical examination, serum-marker study, chest radiography, and plain radiography of the abdomen, while abdominal CT should be performed every three months; and (d) At the first sign of any metastases, either a node dissection should be performed or chemotherapy begun. Initial trials with this approach indicate that the disease will recur and involve the retroperitoneum or lungs in 17%–40% of patients, but essentially, all patients have been cured with surgery, chemotherapy, or both.⁵⁻⁷ Several points, however, are critical. First, high-quality staging studies must be unequivocally normal. Second, the patient and physician must be committed to precise follow-up studies. Third, the patient and physician must realize that this approach is still investigational and has not been proved with a large number of patients in a community setting to be comparable to the standard therapy of an immediate node dissection after an orchiectomy. As further experience is obtained, the value of this approach will be determined.

Use of serum markers

B-HCG, AFP, and LDH studies are performed during each follow-up visit. In patients with a primary mixed germ-cell tumor, 60% will have an elevated B-HCG level and 60% will have an elevated AFP level if the studies are performed prior to an orchiectomy.⁸ The serum half-life of B-HCG is 18–24 hours; an elevated value should return to normal by five days. Similarly, the half-life of AFP is five days; the serum AFP value should return to normal within 25–30 days after an orchiectomy. If the serum markers fail to return to a normal level after an appropriate period of time or if a consistent new elevation becomes evident, metastases are indicated and a thorough radiographic evaluation to identify the site of the metastatic disease is warranted. Minor elevations of B-HCG levels are secondary to a cross-reactivity with luteinizing hormone. Before

beginning any treatment program based purely on serum-marker abnormalities, several values should be obtained and a clear trend of increasing values demonstrated. Unfortunately, for patients with a small volume of nodal metastases, serum-marker levels will not be elevated consistently.

LDH is an important marker for testis cancer.⁹ Although the level of this nonspecific enzyme may be high as a result of many different types of disease, in an otherwise healthy patient that has testis cancer, an elevated LDH value may be the first indicator which is abnormal. In patients with seminomas, the LDH level, as compared to the other serum-marker values, is probably the most commonly elevated. The LDH-1 isoenzyme is the fraction that is most commonly elevated, but the total LDH value is a sufficient basis for follow-up. An elevated LDH level should be considered as significant as an elevated B-HCG or AFP level and should normalize with therapy. Bosl et al¹⁰ believed that an elevated LDH value prior to chemotherapy was a prognostic parameter associated with a low likelihood of a complete response to treatment.

Adjuvant chemotherapy

Because chemotherapy has been effective for metastatic disease, the success of adjuvant chemotherapy for patients with completely resected involved nodes seems likely. The ability to cure patients after a relapse, however, may make the use of such treatment to enhance the effectiveness of overall therapy unnecessary. This dilemma can be illustrated (*Figure*). The calculations shown indicate that, ideally, results will be similar whether adjuvant chemotherapy is used or not. The plan that is actually followed is based on other unquantifiable factors. If one cannot rely on the patient, consistent close follow-up examinations can not be conducted; adjuvant treatment to lessen the possibility of relapse is then appropriate. Only two courses of chemotherapy are necessary, but the maximal tolerated dose should be used.¹¹

Unfortunately, adjuvant chemotherapy is associated with nausea, vomiting, and leukopenia. As shown in the *Figure*, 70 of 100 patients destined to be cured by surgery alone would experience adverse symptoms due to the acute toxicity of unnecessary adjuvant chemotherapy.

The risk of relapse after a node dissection may correlate well with the number of nodes involved and that adequate adjuvant chemotherapy may virtually eliminate late relapses. This information

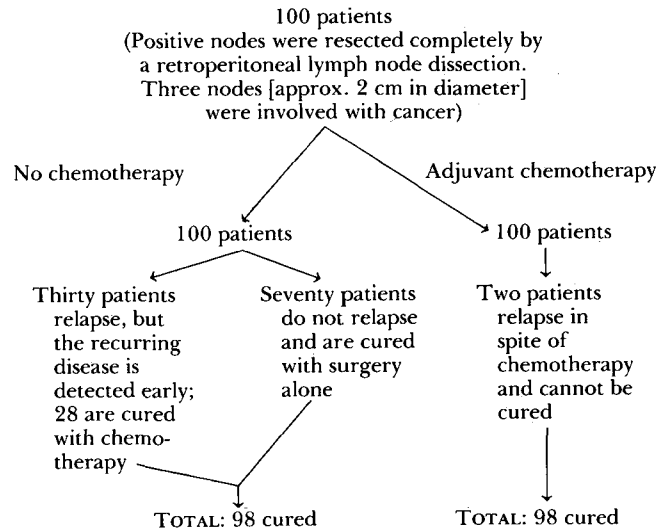


Figure. Cure rate when using adjuvant chemotherapy vs. no chemotherapy

supports the use of adjuvant chemotherapy for all patients except those with the smallest amount of nodal metastases and thus least chance for a relapse.

Management of high-risk patients

Several studies have identified prognostic indicators at the time of the diagnosis which are associated with a poor response to chemotherapy. While the precise definition of "high-risk patient" is still controversial, most physicians will include those with liver metastases, bulky chest metastases (approx. 5 cm in diameter), concomitant retroperitoneal and chest metastases, and extremely high serum-marker values.¹² An elevated B-HCG or LDH level has been reported to indicate a worse prognosis; the relationship between the level of AFP and a bad prognosis is still uncertain.¹⁰ The identification of a high-risk patient implies that additional efforts will be needed aside from standard chemotherapy and surgery to cure these persons. Multiple regimens have been suggested, but the protocol at the Cleveland Clinic now uses alternating noncross-resistant drugs.¹³ A course of vinblastine, bleomycin, and cisplatin is alternated with epipodophyltoxin VP-16-213, doxorubicin hydrochloride, and cis-platin. Chemotherapy should continue until the serum-marker levels normalize (within 4-6 mo). An operation should then completely remove any residual mass present in either the abdomen or the chest. The most commonly used standard chemotherapy regimen is that of Einhorn and Williams¹⁴ which employs four courses

of vinblastine, bleomycin, and cis-platin. After this treatment, a retroperitoneal exploration will indicate that 30% of the patients will have only fibrosis or necrotic cancer, 30% will have a mature teratoma, and 30% will have viable cancer. Patients with viable cancer should receive additional postoperative chemotherapy; this is probably not necessary for patients with either fibrosis, necrotic tumor, or a mature teratoma. The possibility of curing patients with postchemotherapy surgery justifies even extensive operations to completely resect a residual mass. A partial resection is of no long-term benefit to the patient.

During treatment of patients with a bulky disease, an optimistic approach must be steadfastly maintained until circumstances develop that make it clear that a cure is not possible. Although the situation may appear dismal at the initiation of therapy, the potential for positive responses warrant aggressive treatment approaches for as long as possible. Protocols which combine extremely high dosages of chemotherapy with autologous bone marrow transplantation provide partial responses, but provide few long-term remissions.¹² The risks probably outweigh the benefits.

Treatment of seminoma

Therapy for seminoma has changed recently in two ways: patients with a seminoma who have normal or minimally abnormal retroperitoneal staging studies need to be treated with radiation therapy to the retroperitoneum only, and according to Thomas et al,¹⁵ mediastinal irradiation is unnecessary and may make subsequent treatment with chemotherapy more difficult. A patient with a seminoma with bulky retroperitoneal or distant metastatic disease presents a unique problem. While extremely good results are obtained with radiation therapy as the treatment of stage I and small stage II seminomas, poor results are obtained with conventional irradiation methods in stage II-C and stage III seminomas; thus, chemotherapy tends to be employed more and more as the initial treatment. The Einhorn and Williams regimen of vinblastine, bleomycin, and cis-platin;¹⁴ the VAB-6 protocol from the Memorial Sloan-Kettering Cancer Center;¹⁶ and a combination of cyclophosphamide, dactinomycin, and vincristine¹⁷ have provided complete beneficial responses for 80%–90% of all patients. After the initial three to four courses of chemotherapy, a

retroperitoneal lymph node dissection or retroperitoneal radiation therapy can be performed. Radiation therapy may be the more appropriate treatment because most patients respond completely to the therapy. Postchemotherapy node dissections for seminoma are extremely difficult and not likely to be as precise. Aggressive chemotherapy as the initial treatment for patients with a high-stage disease will probably result in cure rates analogous to those obtained in patients with similarly staged mixed germ-cell tumors.

Postoperative management

The use of chemotherapy prior to surgery has contributed to some unique postoperative complications. Interstitial pulmonary fibrosis induced by bleomycin makes the heavily pretreated patients at high risk for adult respiratory distress syndrome. Several postoperative deaths have been reported¹⁸ This is particularly tragic since most of the patients had been cured of their cancer. Maintenance of low intravascular volume and low inspired oxygen pressure in the perioperative and postoperative period drastically reduces the frequency of this complication. An anesthesiologist involved in surgery for these patients must be familiar with this problem.

Conclusion

Therapy for testicular cancer is in a constant state of evolution. The need for urologists to constantly re-evaluate their treatment philosophy and practice in the light of new evidence is clear. Now that extremely good results are evident for patients with stage I and stage II testicular cancer, attention will be focused on minimizing the side effects of treatment. In addition, high-risk patients that may not respond positively to chemotherapy will be more precisely identified.

References

1. Bockrath JM, Schaeffer AJ, Kies MS, Neiman H. Ultrasound identification of impalpable testicle tumor. *J Urol* 1983; **130**:355–356.
2. Nachtsheim DA, Scheible FW, Gosink B. Ultrasonography of testis tumors. *J Urol* 1983; **129**:978–981.
3. Snow BW, Rowland RG, Donohue JP, Einhorn LH, Williams SD. Review of delayed orchiectomy in patients with disseminated testis tumors. *J Urol* 1983; **129**:522–523.
4. Whitmore WF Jr. Surgical treatment of adult germinal testis tumors. *Semin Oncol* 1979; **6**:55–68.
5. Peckham MJ, Husband JE, Barrett A, Hendry WF. Orchiectomy alone in testicular stage I non-seminomatous germ-cell tumours. *Lancet* 1982; **2**:678–680.
6. Sogani PC, Whitmore WF, Herr H, et al. Orchiectomy alone

- in treatment of clinical stage I non-seminomatous germ cell tumor of testis (NSGCTT) (meeting abstract). *Proc Am Soc Clin Oncol* 1983; **2**:C-547.
7. Sturgeon JF, Herman JG, Jewett MA, Alison RE, Gospodarwicz MK, Comisarow R. A policy of surveillance alone after orchidectomy for clinical stage I non-seminomatous testis tumours (meeting abstract). *Proc Am Soc Clin Oncol* 1983; **2**:C-558.
 8. Javadpour N. The role of biologic tumor markers in testicular cancer. *Cancer* 1980; **45**:1755-1761.
 9. Lippert MC, Javadpour N. Lactic dehydrogenase in the monitoring and prognosis of testicular cancer. *Cancer* 1981; **48**:2274-2278.
 10. Bosl GJ, Geller NL, Cirrincione C, et al. Multivariate analysis of prognostic variables in patients with metastatic testicular cancer. *Cancer Res* 1983; **43**:3403-3407.
 11. Vugrin D, Whitmore WF Jr, Cvitkovic E, Golbey RB. Adjuvant chemotherapy in non-seminomatous testis cancer: "mini-VAB" regimen: long-term followup. *J Urol* 1981; **126**:49-51.
 12. Ozols RF, Deisseroth AB, Javadpour N, Barlock A, Messerschmidt GL, Young RC. Treatment of poor prognosis non-seminomatous testicular cancer with "high-dose" platinum combination chemotherapy regimen. *Cancer* 1983; **51**:1803-1807.
 13. Smith G, Bukowski RM, Groppe CW, Montie JE, Purvis JD. Alternating chemotherapy including VP-16 in poor prognosis germinal cell neoplasms (meeting abstract). *Proc Am Assoc Cancer Res* 1983; **23**:583.
 14. Einhorn LH, Williams SD. Chemotherapy of disseminated seminoma. *Cancer Clin Trials* 1980; **3**:307-313.
 15. Thomas GM, Rider WD, Dembo AJ, et al. Seminoma of the testis: results of treatment and patterns of failure after radiation therapy. *Int J Radiat Oncol Biol Phys* 1982; **8**:165-174.
 16. Vugrin D, Whitmore WF Jr, Golbey RB. VAB-6 combination chemotherapy without maintenance in treatment of disseminated cancer of the testis. *Cancer* 1983; **51**:211-215.
 17. Crawford ED, Smith RB, de Kernion JB. Treatment of advanced seminoma with pre-radiation chemotherapy. *J Urol* 1983; **129**:752-756.
 18. Goldiner PL, Schweizer O. The hazards of anesthesia and surgery in bleomycin-treated patients. *Semin Oncol* 1979; **6**:121-124.