

THE CLINICAL PICTURE

SALVADOR ARIAS-SANTIAGO, MD, PhD

Department of Dermatology, San Cecilio University Hospital, Department of Dermatology, Baza General Hospital, and Department of Histology, School of Medicine, Granada University, Granada, Spain

JOSE ANEROS-FERNÁNDEZ, MD

Department of Pathology, San Cecilio University Hospital, Granada, Spain

VICTOR CARRIEL, PhD

Department of Histology, School of Medicine, Granada University, Granada, Spain

JACINTO ORGAZ-MOLINA, MD

Department of Dermatology, San Cecilio University Hospital, Granada, Spain

MIGUEL GONZÁLEZ-ANDRADES, MD, PhD

Department of Histology, School of Medicine, Granada University, Granada, Spain

AGUSTÍN BUENDÍA-EISMAN, MD, PhD

Department of Dermatology, School of Medicine, Granada University, Granada, Spain

MIGUEL ALAMINOS, MD, PhD

Department of Histology, School of Medicine, Granada University, Granada, Spain

The Clinical Picture

A skin lesion after cardiac catheterization

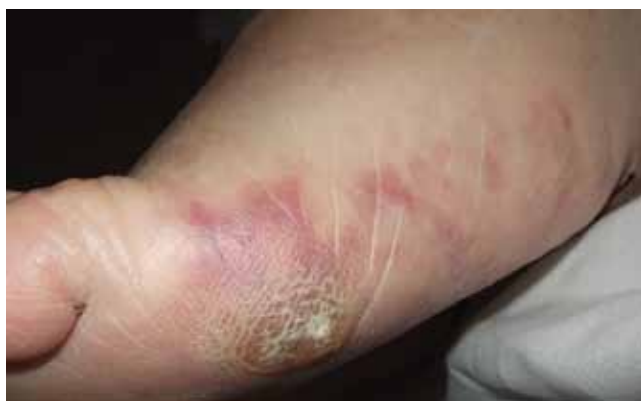

FIGURE 1. Macular violaceous connecting rings in a net-like pattern compatible with livedo reticularis on the foot.

A 64-YEAR-OLD MAN with diabetes and hypertension presented with a 2-day history of sudden onset of acute pain and cyanosis on the sole of his right foot 4 days after undergoing cardiac catheterization and coronary angiography.

The physical examination revealed macular, violaceous, connecting rings in a net-like pattern that blanched with pressure and disappeared when the foot was elevated, a presentation compatible with livedo reticularis (FIGURE 1). Laboratory testing (complete blood cell count, biochemistry panel, coagulation test, and C-reactive protein test) was notable only for eosinophilia.

A few days later, the patient returned with abdominal pain, diarrhea, and acute renal injury with urinary eosinophils (7% of the white blood cells in the urine) and proteinuria.

Q: Which is the most likely diagnosis?

- Infective endocarditis
- Pernio (chilblain)
- Cholesterol crystal embolism
- Cutaneous small-vessel vasculitis

A: Cholesterol crystal embolism is the correct diagnosis.

Infective endocarditis is an infection of the endocardium, but systemic signs may be present, including cutaneous lesions such as Osler nodes (painful papules on the tips of the fingers and toes) and Janeway lesions (painless macules on the palms and soles). Histologic staining of skin biopsy specimens often shows vasculitis, occasionally with a positive Gram stain. Severe renal injury is not common, and the timing of the acute illness and skin lesion fits better with an acute embolic phenomenon.

Pernio is a form of cold injury, localized in peripheral parts of the body and occurring after exposure to cold temperatures in damp conditions. It usually manifests bilaterally as painful erythematous or purple lesions on the acral areas of the hands and feet, nose, ears, and, rarely, the thighs and buttocks. Pernio most commonly affects women between 20 and 40 years of age. It can be idiopathic or associated with a systemic disease such as systemic lupus erythematosus or Sjögren syndrome.

Cutaneous small-vessel vasculitis is a heterogeneous group of disorders with inflammation and damage of the blood vessels; it may be limited to the skin or it may involve multiple systems. Palpable or nonpalpable purpura and ulceration are common clinical findings, and histologic study shows an inflammatory infiltrate of vessel walls, fibrinoid necrosis, thrombosis, and extravasation of red blood cells.

doi:10.3949/ccjm.79a.10108

While this patient's problems are not consistent with small-vessel vasculitis, the single skin lesion, the timing after the catheterization, and the urinary eosinophils are best explained by cholesterol embolization.

■ CHOLESTEROL CRYSTAL EMBOLISM

Cholesterol crystal embolism is commonly iatrogenic, a complication of mechanical damage to the arterial walls from vascular surgery or invasive percutaneous procedures. Material dislodged from atheromatous arterial plaques can occlude the small vessels of the feet, producing this syndrome.

The onset of the clinical disease is often delayed for days to weeks after an angiographic procedure.¹ Spontaneous hemorrhage, disruption of plaque, or drug therapy with an anticoagulant or a fibrinolytic can precipitate embolization of cholesterol crystals. The source of the emboli is atheromatous plaque in major blood vessels, particularly the abdominal aorta.

Many organs and systems can be affected

These emboli can affect many organs and systems: eg, the kidneys (causing hypertension and acute renal failure), the muscles (causing myalgias), gastrointestinal organs (causing bleeding, abdominal pain, and bowel infarction), the lungs (causing acute respiratory distress syndrome), the eyes (causing Hollenhorst plaques in retinal arteries), and the central nervous system (causing stroke, confusion, and delirium). Cardiac or central nervous system involvement is associated with a high risk of death.

After angiography, clinical manifestations of cholesterol embolization have been reported in 0.06% to 1.4% of patients,^{2,3} although the finding of cholesterol emboli is more common in autopsy studies.⁴

Recognizing skin signs is the key

Cutaneous abnormalities are usually the earliest and often the only clinical manifestation of this syndrome. Findings on the lower limbs include blue toes, cutaneous nodules, and livedo reticularis, affecting the feet and legs and sometimes extending upward to the trunk. Other findings include digital infarcts,

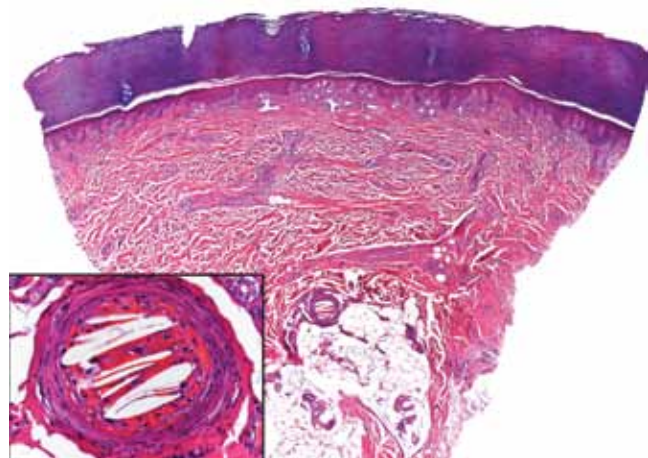


FIGURE 2. Skin biopsy showed needle-shaped clefts within the lumen of blood vessels, ie, dissolved cholesterol crystals obstructing small arteries.

ulceration, gangrene, purpura, cyanosis, and splinter hemorrhages in the nail bed.

In our patient, microscopic study of skin biopsy specimens showed needle-shaped clefts within the lumen of blood vessels—ie, dissolved cholesterol crystals obstructing small arteries (FIGURE 2).

Biopsy studies of skin lesions are positive in a high percentage of cases, showing dissolved cholesterol crystals within the lumen of blood vessels, especially in the small to large arteries and arterioles of the deep dermis or subcutaneous fat. Deep biopsies and careful examination are necessary, as emboli tend to be patchily distributed. Early recognition of cutaneous clinical findings is essential to establish the proper diagnosis and treatment.

The diagnostic triad of this disease includes blue toe syndrome, acute or subacute renal failure, and a temporal relation with an inciting event (particularly angiography). But despite these diagnostic criteria,² the diagnosis is often based on a combination of signs and symptoms specific to end-organ damage and a systemic inflammatory response.³

Histologic confirmation is considered essential to the diagnosis of cholesterol crystal embolism, and as the skin is the most accessible site, skin biopsy provides the best sample for histologic diagnosis.⁵

Postprocedural embolism of a blood clot, vasculitis, and infective endocarditis are the most important differential diagnoses.^{6,7}

The diagnostic triad: blue toe syndrome, acute or subacute renal failure, and a recent inciting event such as angiography

Treatment is supportive, preventive

Treatment is mainly supportive with hemodynamic monitoring, nutritional and metabolic support, mechanical ventilation, and dialysis if necessary. The underlying atherosclerotic disease should be treated aggressively. Prevention of another episode involves modification of traditional risk factors such as serum cholesterol, diabetes, hypertension, and smoking. Additional vascular surgery procedures should be avoided, as they can induce new episodes. ■

REFERENCES

1. Donohue KG, Saap L, Falanga V. Cholesterol crystal embolization: an atherosclerotic disease with frequent and varied cutaneous manifestations. *J Eur Acad Dermatol Venereol* 2003; 17:504–511.
2. Fukumoto Y, Tsutsui H, Tsuchihashi M, Masumoto A, Takeshita A; Cholesterol Embolism Study (CHEST) Investigators. The incidence and risk factors of cholesterol embolization syndrome, a complication of cardiac catheterization: a prospective study. *J Am Coll Cardiol* 2003; 42:211–216.
3. Johnson LW, Esente P, Giambartolomei A, et al. Peripheral vascular complications of coronary angioplasty by the femoral and brachial techniques. *Cathet Cardiovasc Diagn* 1994; 31:165–172.
4. Kronzon I, Saric M. Cholesterol embolization syndrome. *Circulation* 2010; 122:631–641.
5. Jucgla A, Moreso F, Muniesa C, Moreno A, Vidaller A. Cholesterol embolism: still an unrecognized entity with a high mortality rate. *J Am Acad Dermatol* 2006; 55:786–793.
6. Maki T, Izumi C, Miyake M, et al. Cholesterol embolism after cardiac catheterization mimicking infective endocarditis. *Intern Med* 2005; 44:1060–1063.
7. Arias-Santiago S, Aneiros-Fernández J, Girón-Prieto MS, Fernández-Pugnaire MA, Naranjo-Sintes R. Palpable purpura. *Cleve Clin J Med* 2010; 77:205–206.

ADDRESS: Salvador Arias-Santiago, MD, Department of Dermatology, San Cecilio University Hospital, Av Dr. Oloriz 16, Granada 18012, Spain; e-mail salvadorarias@hotmail.es.

Visit our web site at <http://www.ccjm.org>

Contact us by e-mail at ccjm@ccf.org



in cooperation with
Ohio Chapter of the American College of Cardiology



Ohio
CHAPTER

13th Annual Intensive Review of Cardiology

Comprehensive
Four-Day Symposium

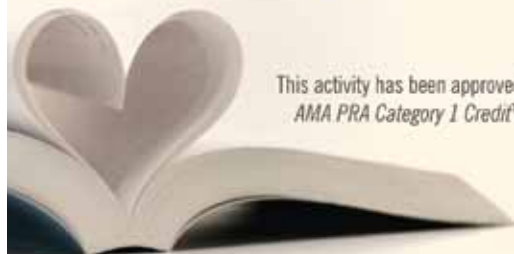August 19–22, 2012
Cleveland, Ohio, USA

PRESYMPOSIUM COURSE:

**Transcatheter
Valve Therapies**

Saturday, August 18, 2012

For complete program and
registration information go to:
www.ccfcm.org/cardioreview12



This activity has been approved for
AMA PRA Category 1 Credit™.