

URETERAL TRANSPLANTATION FOR EXSTROPHY AND CARCINOMA OF THE BLADDER

CHARLES C. HIGGINS, M.D.

Exstrophy of the bladder is one of the most unfortunate and pathetic of all congenital anomalies. According to the statistics of Neudörfer,¹ it occurs approximately once among every 50,000 births and it is stated that 50 per cent of the children who have this anomaly die before they attain the age of ten years, and that 66 per cent die before the twentieth year, unless relief is afforded by surgical intervention.

The late Dr. Robert C. Coffey deserves the gratitude of the profession for his valuable contributions in the development of the operation for the transplantation of the ureter into the recto-sigmoid. In 1911 he² emphasized the importance of utilizing the valve principle in this operation, and the basis for this contribution was afforded by observations of the anatomical relationships of the common bile duct in its course through the walls of the duodenum. Dr. Coffey noted that this duct courses through the muscularis and then between the muscularis and mucosa of the duodenum for some distance before it opens into the lumen of the duodenum itself.

Since the adoption of the valve principle in the transplantation of the ureters, the operation has been performed frequently and has been accepted as a sound and justifiable surgical procedure. Dr. Coffey, however, stated two objections to the procedure which have prevented its general acceptance by surgeons. The first was that it is impossible to maintain uninterrupted kidney function and not alter the normal physiologic processes of the upper urinary tract when both ureters are transplanted simultaneously. In the second place, the danger of infection always has been great and is the most common cause of death, regardless of the surgical technique employed.

In 1933, I described a technique by which both ureters could be transplanted simultaneously without interruption of renal function.³ By this method the continuity of the ureter remains intact until a new channel has been established, and the normal passage of urine from the kidney through the ureters and into the bladder is not disturbed until it is diverted through the newly established communication. In addition, since the lumen of the bowel is not exposed, the danger of infection is negligible. Since both ureters can be transplanted simultaneously, the length of time required for hospitalization is reduced materially. Another advantage is that the procedure is accompanied by only slight postoperative reaction.

By this technique, a child with exstrophy of the bladder may be operated upon much earlier in life before hydro-ureter, hydronephrosis and associated renal infection and impairment of renal function

URETERAL TRANSPLANTATION

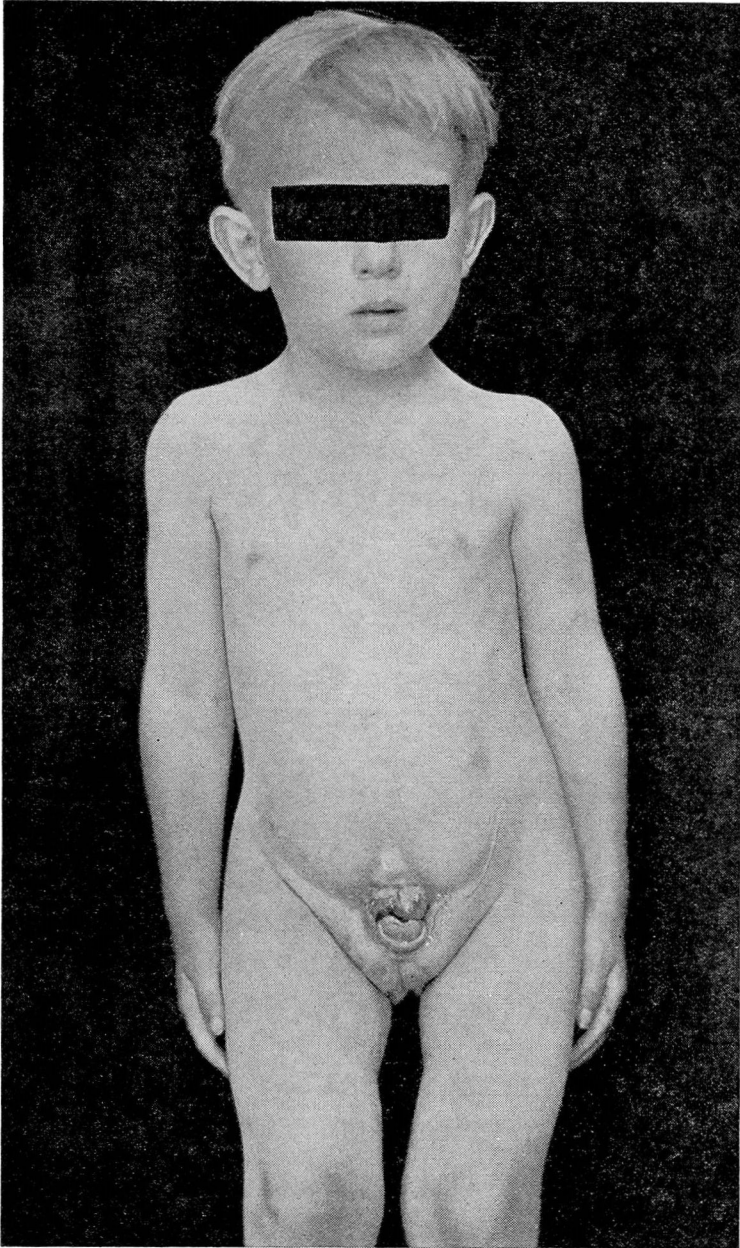


FIGURE 1.—Photograph of patient showing exstrophy of the bladder.

have appeared. If the tone of the rectal sphincter is adequate, the sooner surgical intervention is employed, the less likelihood is there that irreparable renal damage will have taken place.

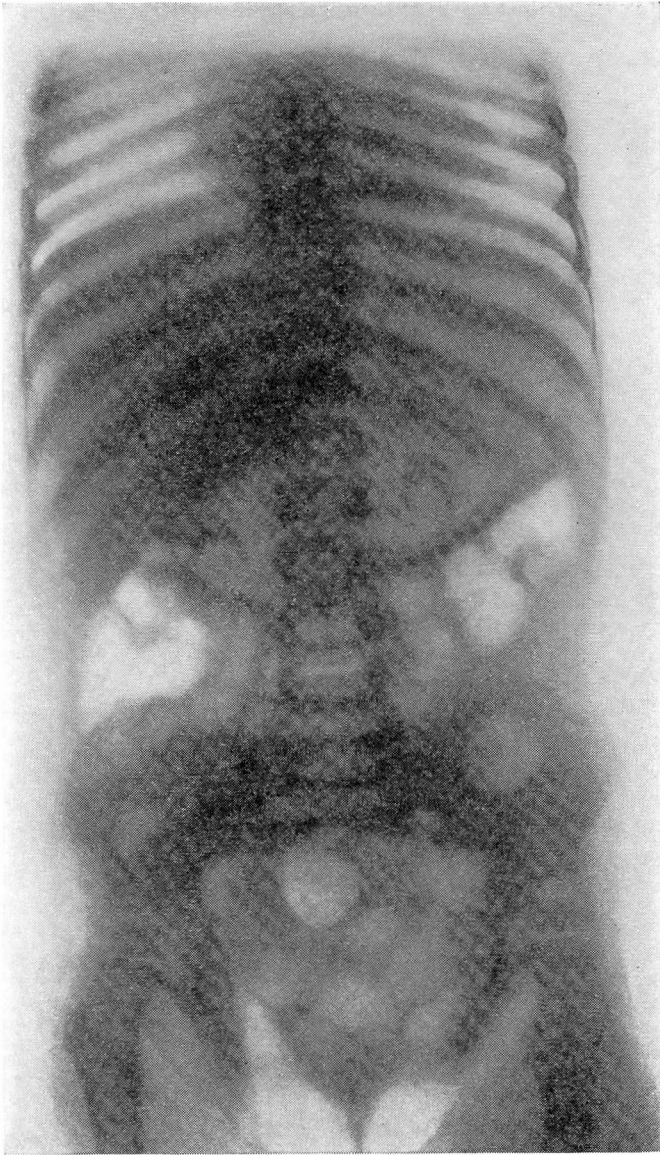

FIGURE 2.—Urogram taken by intravenous method preoperatively showing good function of both kidneys. There is no evidence of hydronephrosis or hydro-ureter.

The following is an illustrative case:

History

A boy, aged 4 years, came to the Clinic after a diagnosis of exstrophy of the bladder had been made by his physician. Since his birth the parents had noted the abnormal position of the bladder, the constant soiling of the child's

URETERAL TRANSPLANTATION

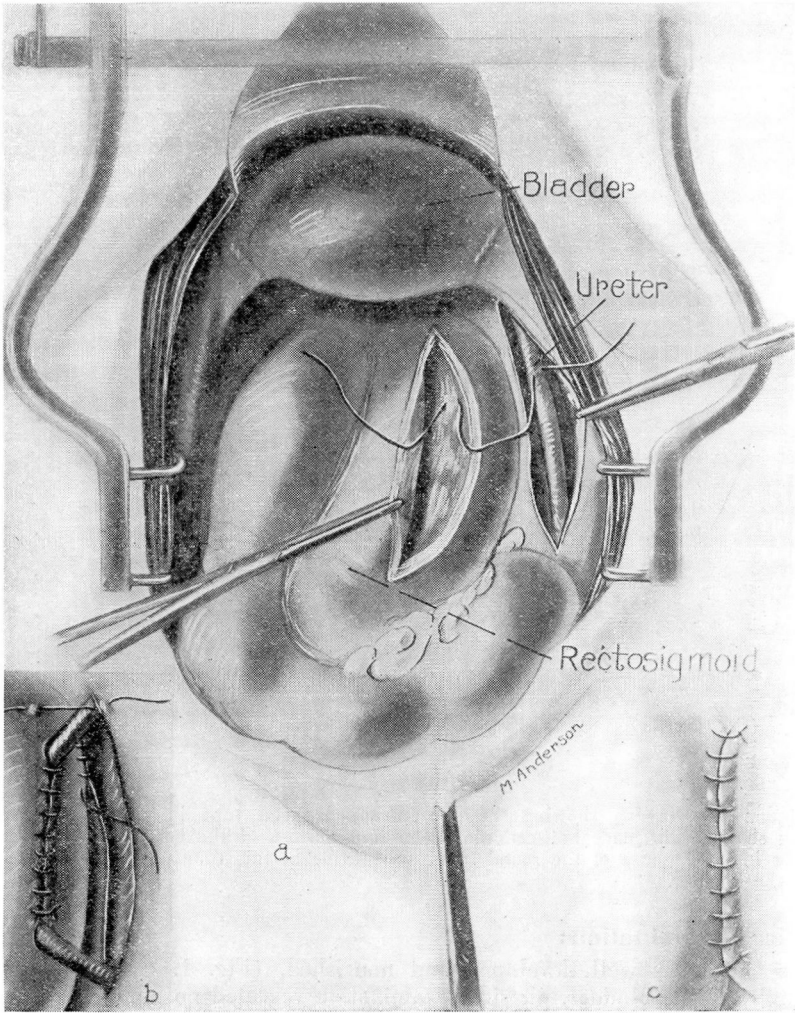


FIGURE 3.—Drawing showing (a) transfixion suture placed between the ureter and mucosa of the recto-sigmoid; (b) muscularis and serosa layers reapproximated over the ureter; (c) suture of posterior parietal peritoneum over the line of incision in the bowel.

clothing and irritation of the adjacent skin from the urine. There had been no apparent difficulty in the control of the bowels. The child began to walk at the age of twelve months and to talk when he was fifteen to eighteen months old. When he was two years old a bilateral inguinal herniorrhaphy had been performed. For a few months, bleeding from the raw surface of the bladder had occurred frequently. No other abnormalities had been observed.

The father and mother were both living and well and one brother was living and free from congenital abnormalities.

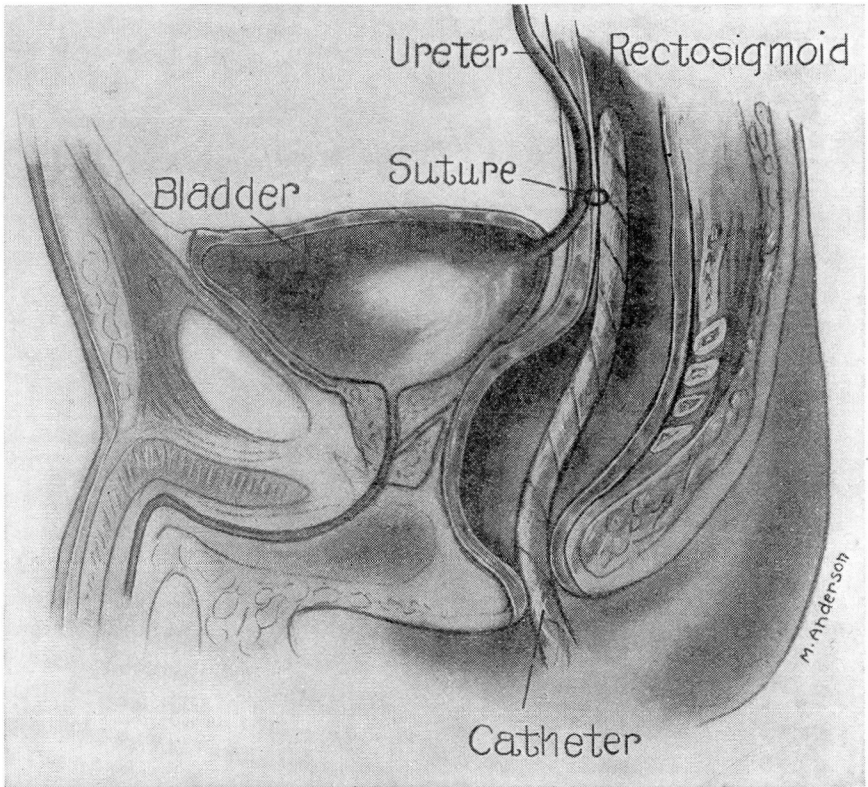


FIGURE 4.—Drawing showing the gauze-wrapped rectal tube in place. The transfixion suture is in place between the ureter and mucosa of the bowel which includes a bite into the gauze of the rectal tube. The urine at this time passes uninterrupted into the bladder.

Physical Examination:

The child was well developed and nourished. (Fig. 1.) Except for the exstrophy of the bladder, physical examination revealed no abnormalities. At the lower part of the exstrophic bladder, urine could be seen spurting from the ureteral orifices. Epispadias also was present. The incision from the previous operation was well healed, and there was no evidence of recurrence of the hernia. The testicles were normal and had been placed in the scrotum at the time the herniorrhaphy had been performed.

Laboratory studies:

A roentgenogram of the genito-urinary tract showed normal findings. An intravenous urogram made after the intravenous injection of skiodan (Fig. 2) showed good function of both kidneys with no evidence of hydro-ureter, hydronephrosis or stasis. Examination of specimens of urine secured from the kidney pelvis by catheterization gave no abnormal findings. A function test (5 cc. of indigo carmine injected intravenously) showed that the dye spurting from the right ureteral orifice in four minutes with 4 + concentration and from the left in a similar length of time. Examination of the blood

URETERAL TRANSPLANTATION

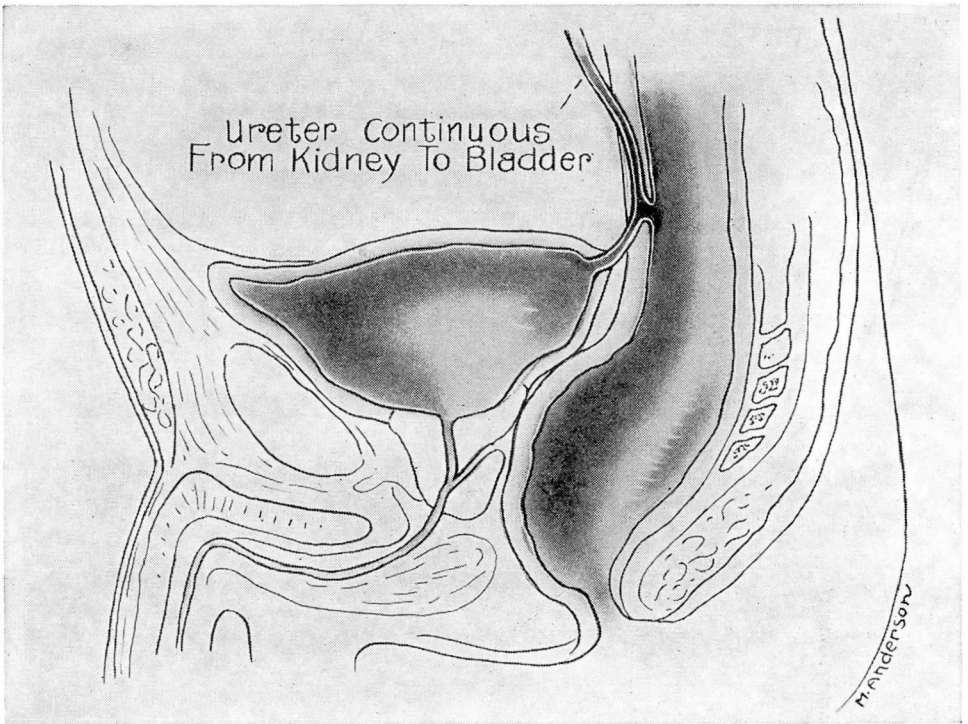


FIGURE 5.—Drawing showing new communication between the ureter and bowel established. Rectal tube and sutures have been passed.

showed 4,370,000 red blood cells, 9,800 white blood cells and 80 per cent hemoglobin. The Wassermann reaction was negative. The blood urea was 28 mg. per hundred cubic centimeters.

The child was admitted to the hospital and a bilateral transplantation of the ureters into the rectum was performed three days later.

Operative technique:

Under ether anesthesia, a number 18 French catheter, wrapped with a layer of vaseline gauze, was inserted into the rectum and one ounce of methiolate solution was introduced into the recto-sigmoid through the catheter. A small rubber apron was then secured to the lower abdominal wall in such a way as to isolate the exstrophy of the bladder from the operative field. A low mid line incision was made and carried through the peritoneum. The intestines then were displaced into the upper abdominal cavity and held in place by moist tapes. The right ureter was isolated at the usual site of transplantation. After incision of the posterior peritoneum, the ureter was delivered from its bed and mobilized for approximately two inches. A suitable site adjacent to the mobilized ureter was selected in the recto-sigmoid and a longitudinal incision one and one-half inches in length was made through the serosal and muscularis layers to the mucosa. These layers then were undermined by blunt dissection.

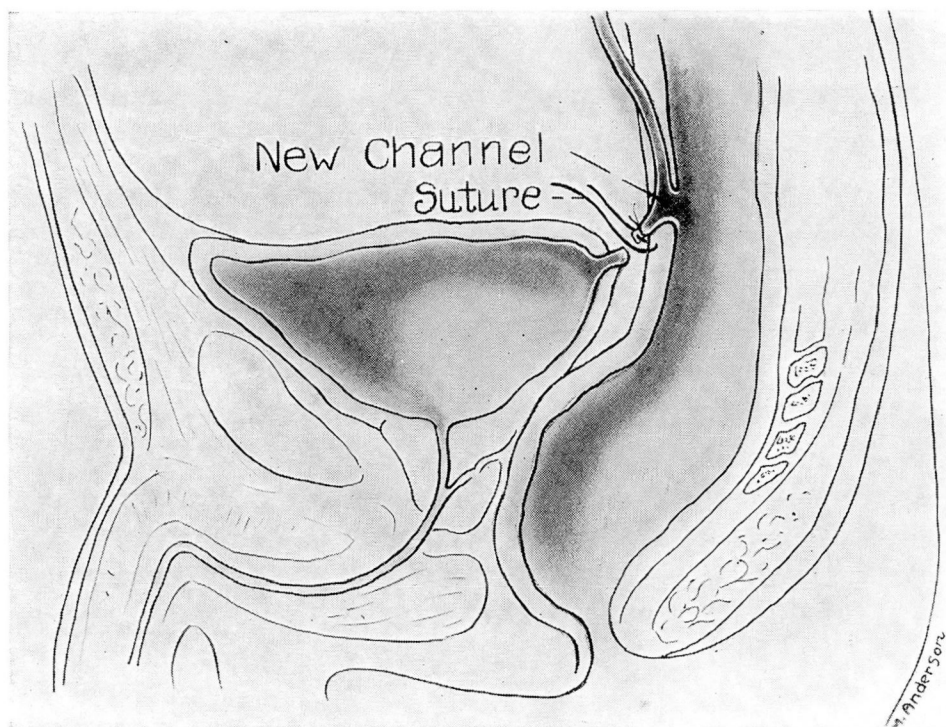


FIGURE 6.—Drawing showing the continuity of the ureter severed at the point of emergence from the trough and additional anchoring suture in place.

The ureter was placed in the trough of the bowel thus formed. A silk mattress transfixion suture was passed through the lumen of the ureter, then through the mucosa of the recto-sigmoid and included a bite into the gauze surrounding the rectal tube. The suture was tied quite tightly. The transfixion suture between the ureter and the bowel was placed at the lower end of the incision in the recto-sigmoid in order that a blind pouch of ureter would not be left when the continuity of the ureter was interrupted. The muscularis and serosal layers were reapproximated over the ureter with interrupted silk sutures. The outer edge of the posterior peritoneum was sutured over the incision in the bowel with interrupted silk sutures, thereby placing the anastomosis in the retroperitoneal position and immobilizing the recto-sigmoid. (Figs. 3-7.)

A similar procedure was performed on the left ureter and bowel. The abdomen was closed in layers without drainage.

Postoperative course:

The rectal tube with the two sutures between the ureters and the recto-sigmoid were passed in sixty-four hours. In the meantime, urine was passing unobstructed through the ureters and could be seen spurting from the ureteral orifices. An intravenous urogram showed no evidence of obstruction on either side, and the solution passed into the rectum unobstructed, after the channel had been established.

URETERAL TRANSPLANTATION

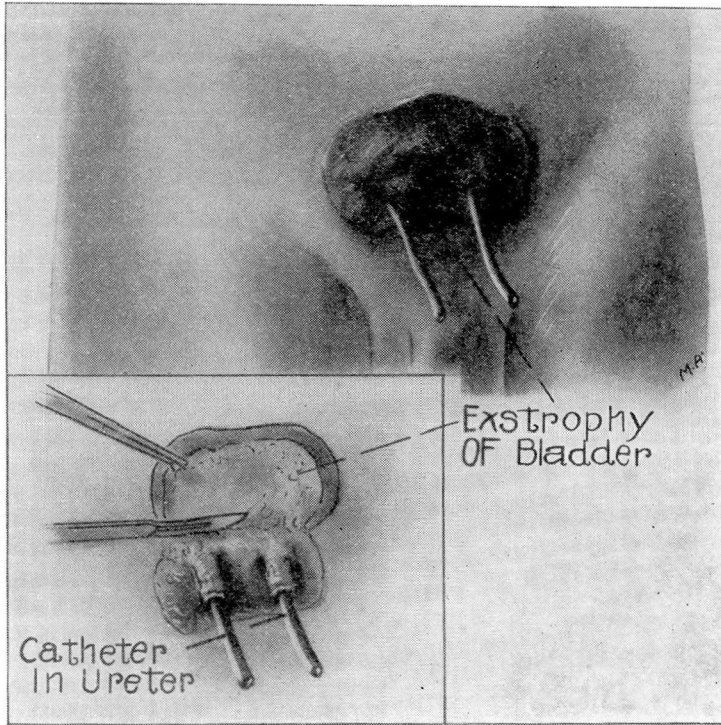


FIGURE 7.—Drawing showing (a) exstrophy of the bladder. Catheters *in situ*; (b) dissection of exstrophic bladder. The ureters are followed down and ligated as they emerge from the trough in the bowel.

Second operation:

The second operation was performed ten days later. This included cystectomy and severance of the continuity of the ureters with removal of the lower segments of the ureters (Figs. 8 and 9). The exstrophic bladder was removed by the usual technique. The two ureters were easily followed down to the point where they emerged from the trough in the bowel and there were divided and ligated. The skin about the periphery of the defect in the abdominal wall was undermined and the skin edges were reapproximated with silk sutures, and with stay sutures of silkworm gut. The child's condition was satisfactory at the completion of the operation.

Eight days after operation, the child was discharged from the hospital. At that time, the intravenous urogram showed normal findings (Fig. 10). The total period of hospitalization was twenty-one days. One year later, a letter from the patient's physician stated that the child was in excellent physical condition.

CONCLUSIONS

Transplantation of the ureters for exstrophy of the bladder should be performed as soon as there is positive evidence that the rectal sphincter is functioning adequately. The earlier the operation, the

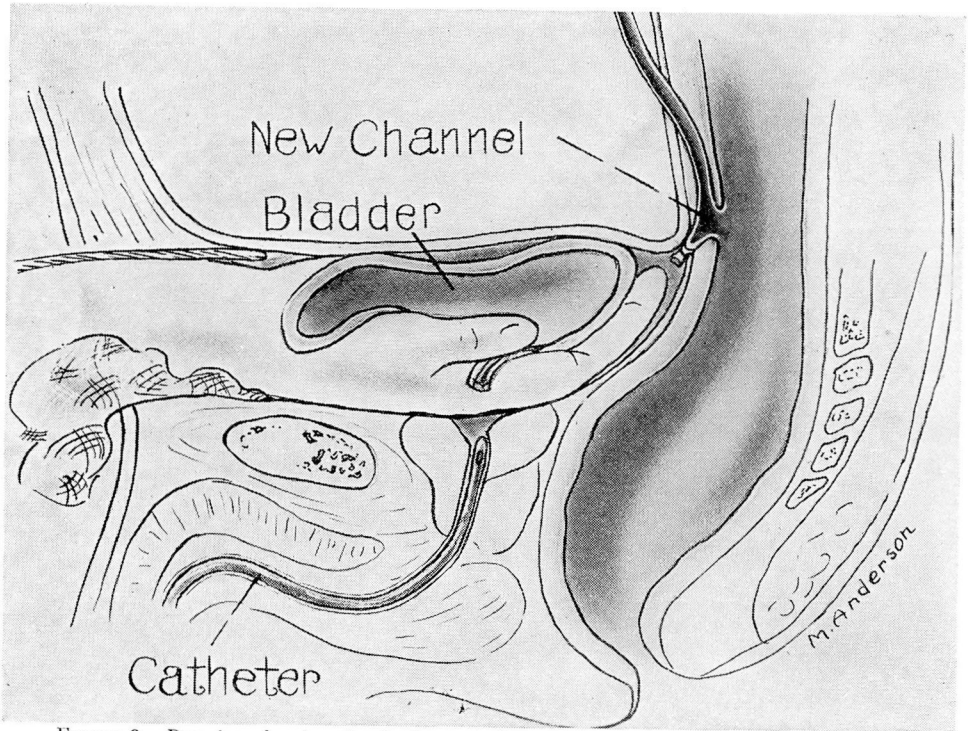


FIGURE 8.—Drawing showing the final stage of cystectomy starting at the bladder neck.

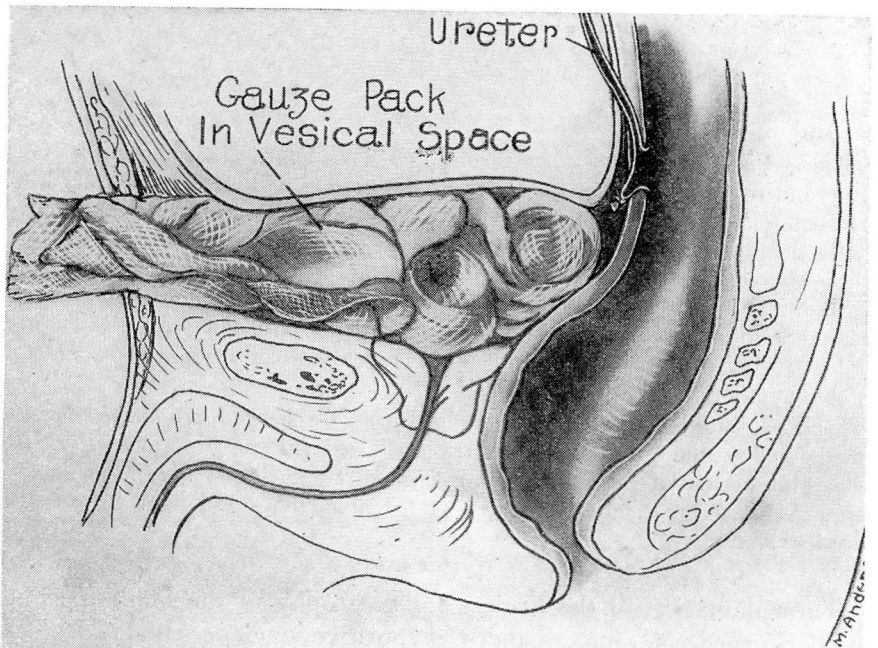


FIGURE 9.—Drawing showing the cystectomy completed. The vesical space is packed with gauze.

URETERAL TRANSPLANTATION

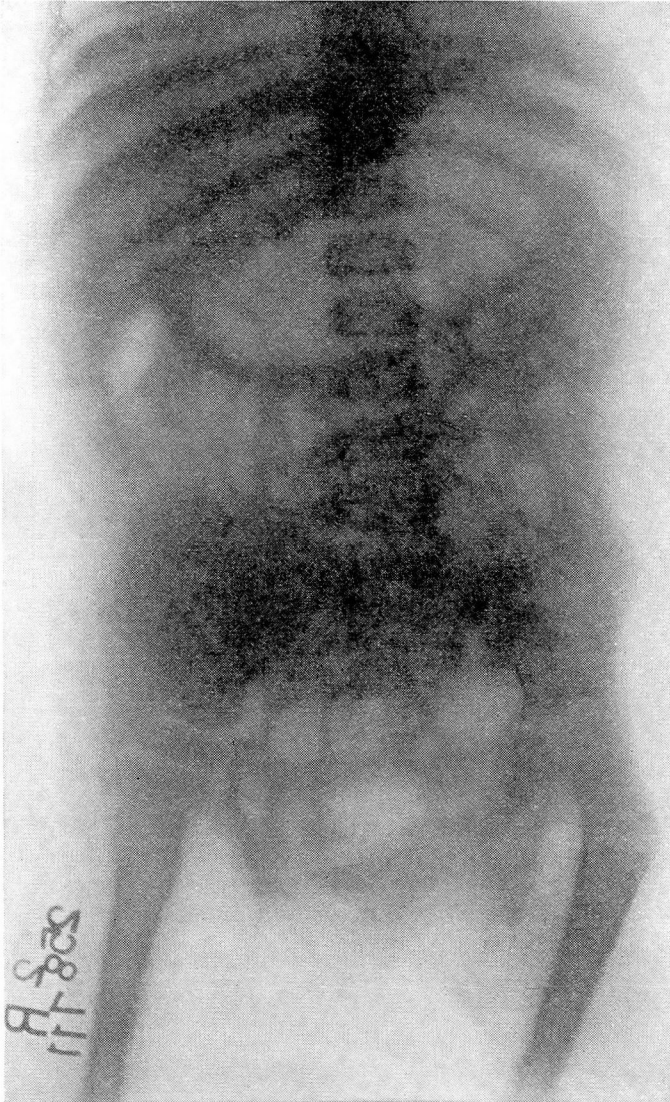


FIGURE 10.—Postoperative urogram shows no evidence of stasis. There is no evidence of the dye in the kidneys at the end of one hour.

better the chance for avoiding the development of hydronephrosis and hydro-ureter with the renal infection and functional impairment which frequently are seen in older children in whom the operation has been delayed.

A technique is described by which both ureters may be transplanted simultaneously. This procedure is accompanied by only slight post-

CHARLES C. HIGGINS

operative reaction and the time required for hospitalization is materially reduced.

REFERENCES

1. Neudörfer. J.: Die Operation der Ectopie der Blase, Fortschr. d. Med. Berl., 4:255-258, 1886.
2. Coffey, R. C.: Physiologic implantation of the severed ureter or common bile duct into the intestine, J.A.M.A., 56:397-403, 1911.
3. Higgins, C. C.: Aseptic uretero-intestinal anastomosis, Surg. Gynec. Obst., 57:359-361, 1933.