

Radiology Feature

Edward Buonocore, M.D.,
Section Editor

Unusual cause of claudication in a 48-year-old man

Edward Buonocore, M.D.¹

Robert Graor, M.D.²

Edwin G. Beven, M.D.³

A 48-year-old man was admitted to the Cleveland Clinic because of claudication of the right calf for one month. Onset of symptoms was sudden and was first noted while he was crouching. Initially, pain occurred after he had walked 400 feet. At the time of admission, however, he was able to walk three or four blocks without pain. Symptoms abated after several minutes rest. During the week before admission he had experienced numbness and coldness of the toes of the right foot. He has never smoked cigarettes but has been an avid pipe smoker.

The patient took pride in his excellent health and there was no personal or family history of arteriosclerosis. Medical and surgical consultants had noted decreased pulses at the level of the right knee and ankle and recommended arteriography and probable femoropopliteal bypass graft surgery. He steadfastly refused to accept the diagnosis of arteriosclerotic occlusive disease and sought further consultation.

The only pertinent finding on physical examination was a slight decrease in the strength of arterial pulses in the right foot (3+). The remainder of the pulses of the extremities were full and graded 4+. After exercise, a decrease was noted in the amplitude of the pulses over the right popliteal, dorsal pedal, and posterior tibial arteries. There was a marked drop in Doppler pressures recorded at the ankle level after exercise.

Abdominal aortograms with run-off studies of the legs were made one day after admission. All arteries were normal except for an unusual defect in the right superficial femoral artery (*Fig. 1*). The defect was interpreted as extrinsic compression. No evidence of arteriosclerotic disease was found. On ultrasonic studies, interruption of the arterial lumen and subtle findings suggestive of a small mass adjacent to and probably part of the vascular wall were identified (*Fig. 2*). Computed tomography (CT) of the extremities showed a small mass within the anterior wall of the right popliteal artery (*Fig. 3*). The femur was normal and no other bony or soft-tissue abnormalities were detected.

Questions

What form of arterial disease does this patient have?

What should be the next step in this patient's care?

All consultants (surgical, medical, and radiologic) agreed that the right popliteal artery should be surgically explored. Cystic adventitial degenerative disease of the popliteal arterial wall was identified and locally resected. No graft was necessary. The final pathology report was adventitial cystic myxomatous degeneration. The postoperative period was uneventful, and the patient became entirely asymptomatic. Postoperative digital subtraction angiograms (DSA) made of the leg after intravenous injection of 40 ml of contrast medium into the basilic vein of the right arm revealed the popliteal and femoral arteries to be entirely normal (*Fig. 4*).

¹ Department of Hospital Radiology.

² Department of Peripheral Vascular Surgery.

³ Department of Vascular Surgery.

Submitted for publication in November 1982; accepted in December 1982.

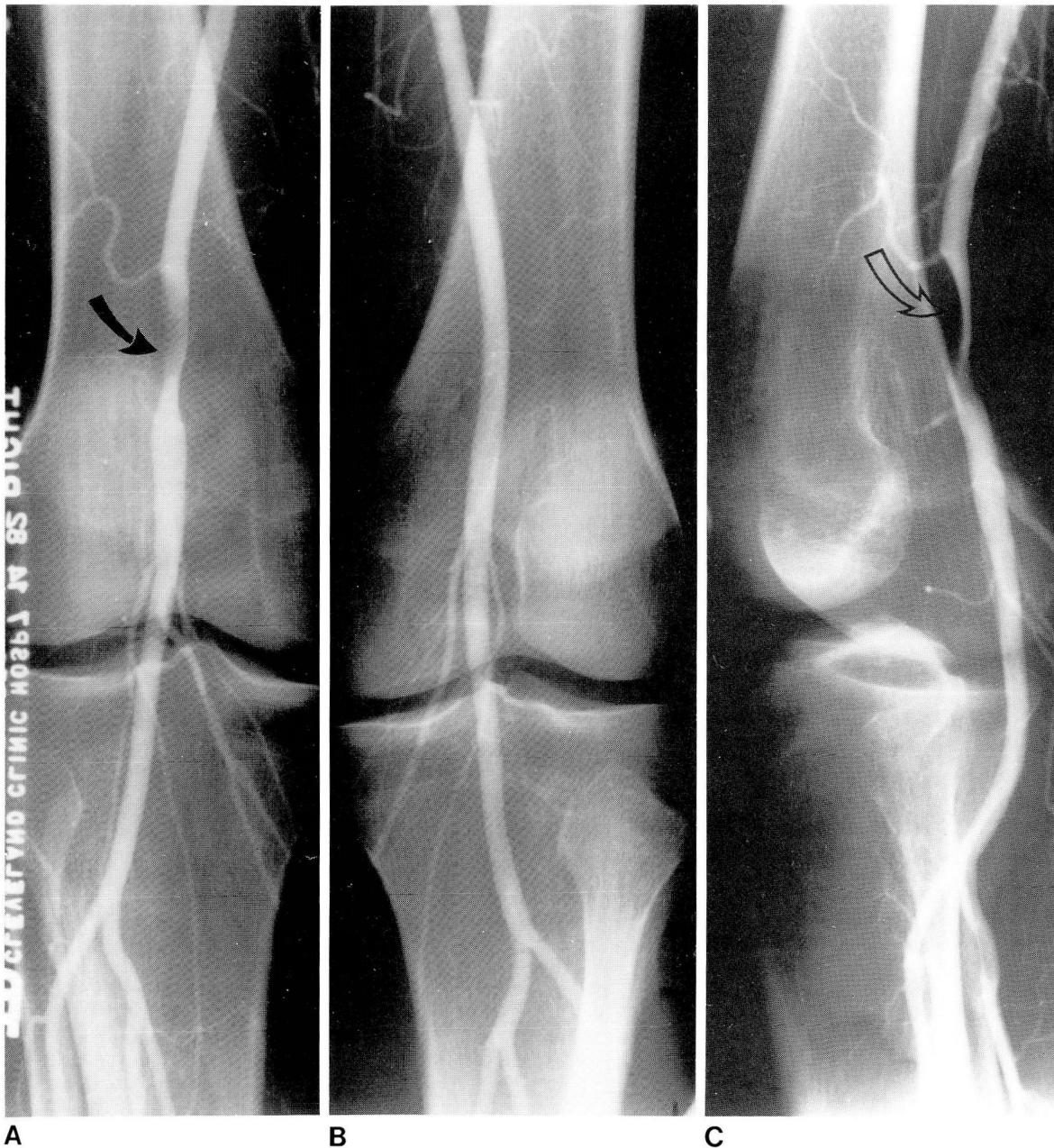

Figure 1A. Frontal projection of the distal right femoral and popliteal arteries. Note smooth defect of the lumen of the distal right femoral artery (arrow).

B. Comparison arteriogram of normal left femoral artery.

C. Lateral view of the right femoral artery. A smooth defect is identified in the anterior wall of the distal right femoral artery (arrow).

Discussion

The most common cause of claudication in a 48-year-old man is arteriosclerosis obliterans. The unusual nature of the arteriographic findings in this patient produced some initial confusion. The primary diagnosis was adventitial cystic disease of the femoral artery. The extrinsic compression deformity and the sudden onset of symptoms were interpreted

as possibly compatible with compression by a soft-tissue malignant neoplasm.

Popliteal artery entrapment syndrome was not seriously considered in the differential diagnosis. This entity always affects the midpopliteal artery and is produced by an anomalous medial head of the gastrocnemius muscle. In such cases a characteristic appearance of the involved artery is seen on arteriography. Compression of the popliteal artery

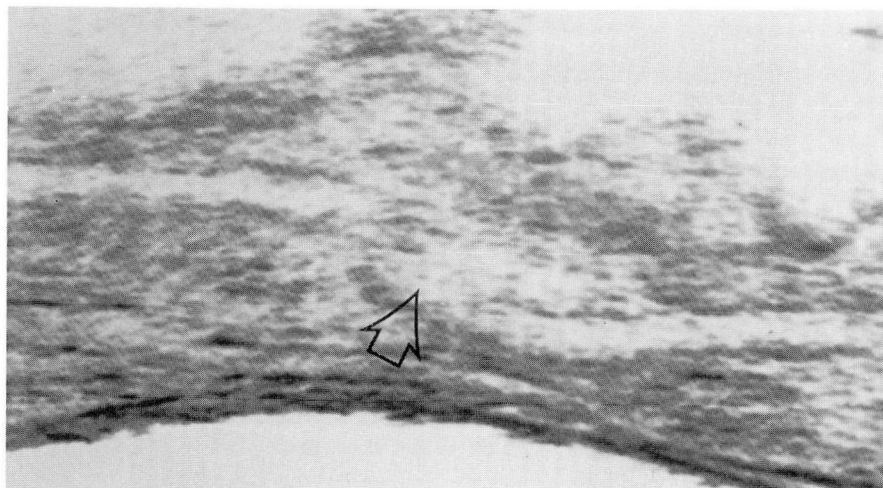


Figure 2. Sagittal ultrasonogram of the right leg. Note mass (arrow) and interruption of the arterial lumen. Patient is supine; head is to the left.

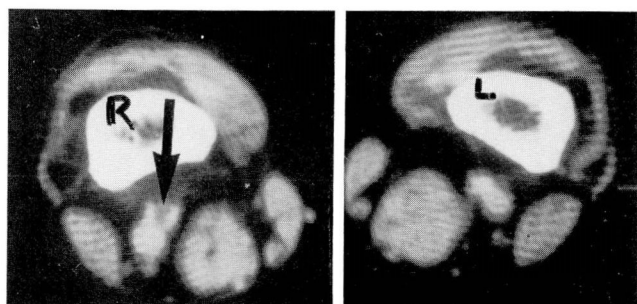


Figure 3. CT scan of the lower extremities after intravenous injection of contrast medium. A small lucent mass is seen in the anterior wall of the right femoral artery (arrow). Patient is supine (*R* = right femur, *L* = left femur).

by the medial head of the gastrocnemius muscle produces either medial deviation or compression of the midportion of the artery. The radiographic finding in this patient was in the distal femoral artery. There was no medial deviation of the artery, and the defect was along the anterior arterial wall. None of these findings has been described with popliteal vascular entrapment syndrome.

In soft-tissue tumors of the extremities, the extent and stage of the neoplasm can be successfully identified with CT.¹ Determining the size of the soft-tissue component, the arterial supply, and identification of bone or bone marrow involvement are necessary for successful surgical planning.² Recently, Paushter et al³ found the combination of CT and

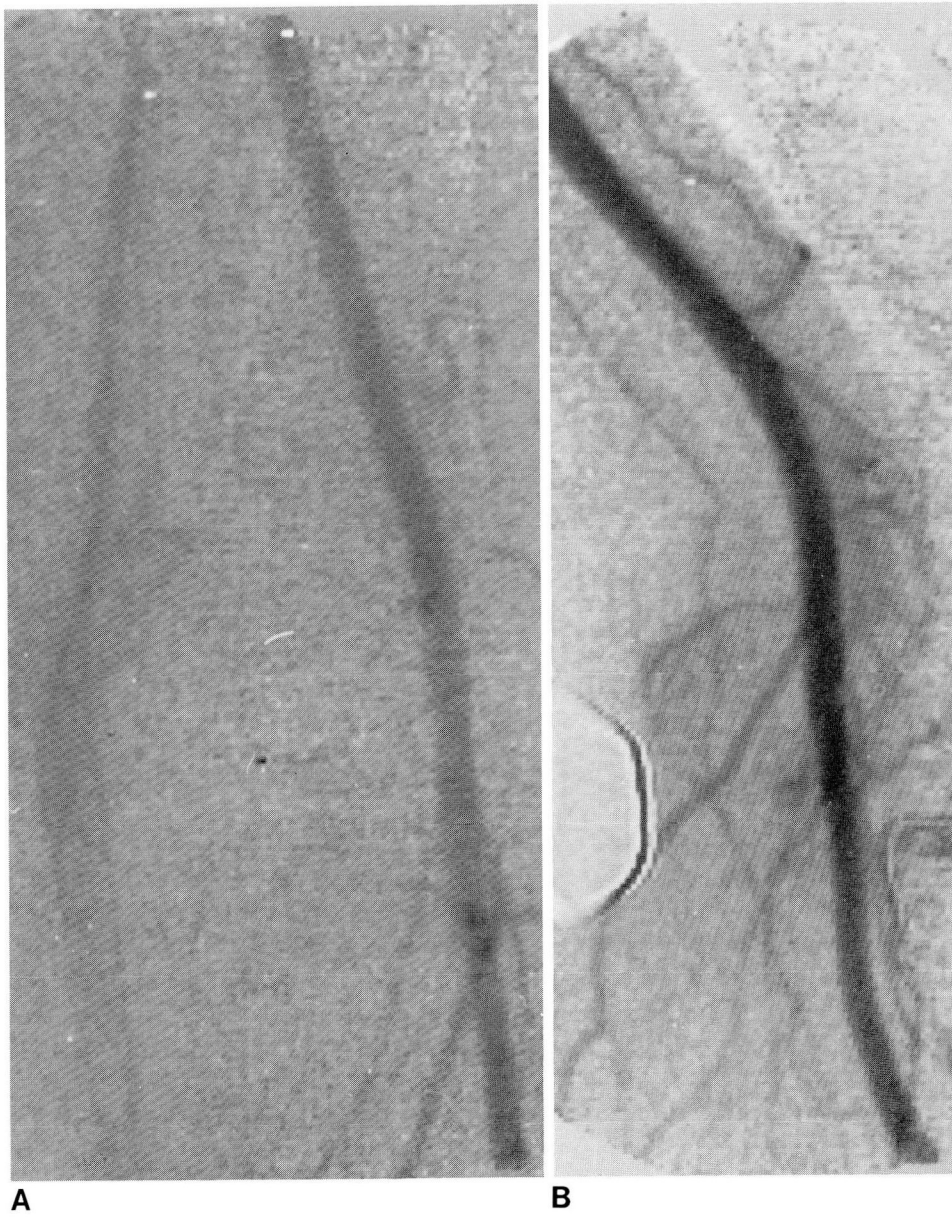
DSA with intravenous injection of contrast medium adequate for tumor staging in 11 of 13 patients with soft-tissue tumors of the extremities.

The finding of adventitial cystic disease of the popliteal artery obviated further imaging techniques. It is an unusual cause of arterial narrowing, with only a few cases reported.⁴ Of unknown etiology, it represents myxomatous degeneration of the adventitial layer of the artery. It occurs predominantly in males in the absence of arteriosclerosis and most frequently involves the midpopliteal artery.

The area of narrowing in this patient was more proximal than is usually reported; this, combined with the rapid progression of symptoms, led to the additional imaging tests for tumor. An interesting presenting feature was aggravation of symptoms during crouching. This may have been caused by further compression of an already narrowed artery.

References

1. deSantos LA, Goldstein HM, Murray JA, Wallace S. Computed tomography in the evaluation of musculoskeletal neoplasms. *Radiology* 1978; **128**:89-94.
2. Heelan RT, Watson RC, Smith J. Computed tomography of lower extremity tumors. *AJR* 1979; **132**:933-937.
3. Paushter DM, Borkowski GP, Buonocore E, Belhobek GH, Marks KE. Digital subtraction angiography (DSA) for the preoperative evaluation of tumors of the extremities. Presented at the Annual Meeting of the American Roentgen Ray Society, New Orleans, May 1982.
4. Allen EV, Barker NW, Hines EA. *Peripheral Vascular Diseases*. Philadelphia: Saunders, 5th ed, 1980.



A **B**
Figure 4. Frontal (A) and lateral (B) DSA views of the right femoropopliteal arteries are normal after resection of cystic degeneration of the adventitial wall of the distal femoral artery. (Compare with *Figure 1.*)