

MOULAY A. MEZIANE, MD, EDITOR

Bilateral renal masses in a 61-year-old man

RICHARD G. BARR, MD, PhD; CATHRYN POWERS, MD; KATHLEEN GLEASON BEAVIS, MD

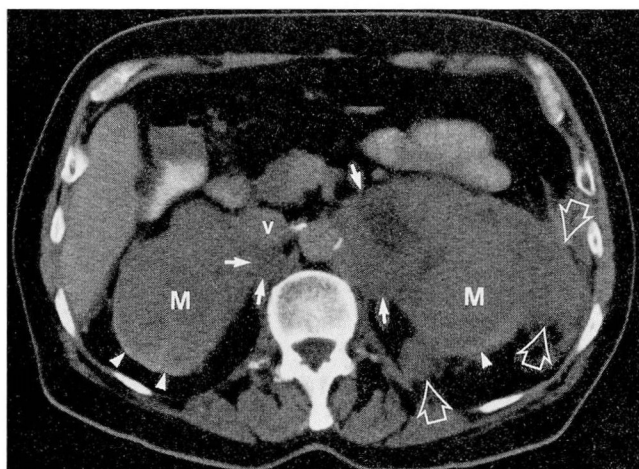


FIGURE 1. Contrast-enhanced CT scan through the upper kidneys demonstrates bilateral bulky nonenhancing masses replacing the renal parenchyma (M) and extending into the periaortic region bilaterally (solid arrows) with anterior displacement of the inferior vena cava (V). Also note involvement of the left perinephric space (open arrows). A very small rim of renal cortex can be seen posteriorly (arrow heads).

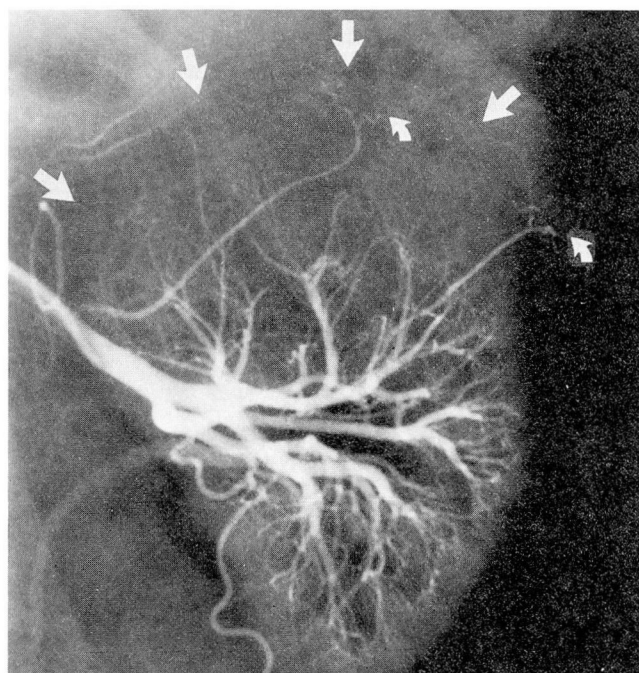


FIGURE 2. Selective arteriogram of the left kidney demonstrates a large hypovascular mass of the upper pole (solid arrows). Note stretching of the upper pole branches, with tortuosity of the peripheral capsular branches (curved arrows). Similar findings were noted for the right kidney.

A 61-year-old white man presented with the complaint of 4 months of fevers and several weeks of night sweats. He had lost 30 lb over a 6 month period. Physical examination was unremarkable. Laboratory evaluation revealed hemoglobin 11.6 g/dL (13.5–17.5), hematocrit

From the Department of Radiology, San Francisco General Hospital Medical Center/University of California, San Francisco, and the Departments of Radiology (C.P.) and Pathology (K.G.B.), The Cleveland Clinic Foundation.

Address reprint requests to Moulay A. Meziane, MD, The Cleveland Clinic Foundation, One Clinic Center, 9500 Euclid Avenue, Cleveland, OH 44195.

34.3% (40–52), white blood cell count $5.17 \times 10^3/\mu\text{L}$ (4.0–11.0), platelet count $307 \times 10^3/\mu\text{L}$ (150–400), blood urea nitrogen 25 mg/dL (10–25), serum creatinine 1.5 mg/dL (0.7–1.4), lactate dehydrogenase 407 IU/L (50–52), SGOT 24 IU/L (7–40), and alkaline phosphatase 65 IU/L (20–110). Bone marrow examination was normocellular without evidence of malignancy.

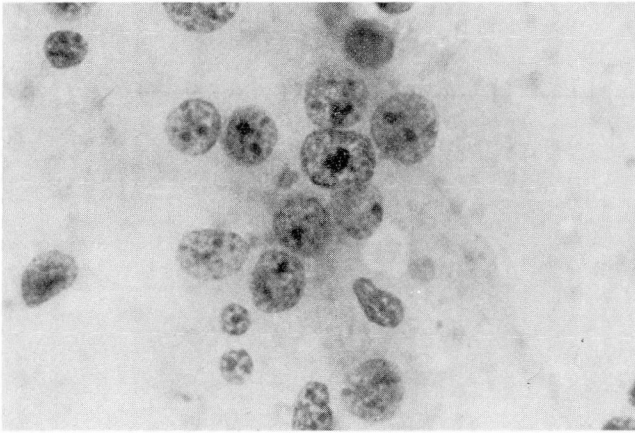


FIGURE 3. The cytology preparation contains large lymphoid cells with vesicular nuclei, dispersed fine chromatin, and nucleoli, as well as occasional small mature lymphocytes (Papanicolaou stain, oil immersion, $\times 100$).

Contrast-enhanced computed tomography (CT) of the abdomen demonstrated bilateral nonenhancing renal masses (Figure 1). Bilateral renal arteriography revealed hypovascular masses (Figure 2) and inferior venacavography demonstrated extrinsic compression by the right renal mass without tumor thrombus. A diagnostic procedure was performed.

DIAGNOSIS: BILATERAL RENAL LYMPHOMA

A CT-guided needle aspiration biopsy of the right renal mass was obtained. The specimen consisted of 5 cc of clear, colorless fluid and a tissue fragment. Malignant cells consistent with large cell lymphoma were identified in both the cytology (Figure 3) and the cell block (Figure 4) preparations. Immunohistochemical examination for cytokeratins A/E 1 and 3 were negative; these are characteristically present in renal cell carcinoma.¹ In contrast, the common leukocyte antigen was strongly positive, as would be expected in most lymphomas.

The patient began a chemotherapy regimen consisting of methotrexate, Adriamycin, Cytoxan, Oncovin, prednisone, bleomycin ("MACOP-B"), and leucovorin. Contrast-enhanced CT scan of the abdomen obtained 1 month after the initiation of treatment demonstrated a marked reduction in the size of the renal masses (Figure 5). Despite a clinical remission of his lymphoma, the patient expired 5 months after diagnosis due to complications of adrenal insufficiency and immunosuppression. An autopsy was not permitted.

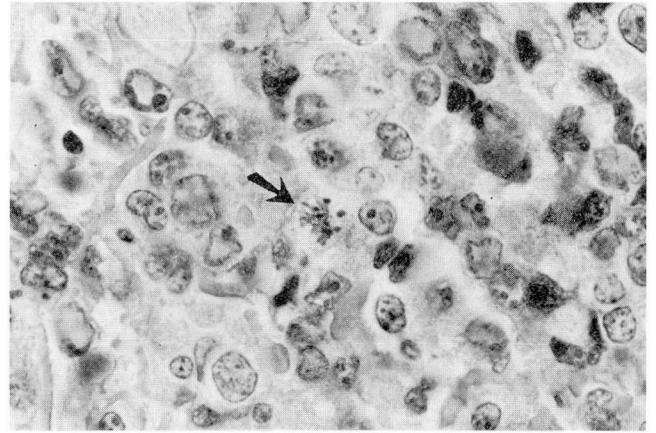


FIGURE 4. The cell block contains sheets of abnormal lymphocytes; most of the nuclei are large with smooth borders. Mitoses (arrow) are occasionally seen (hematoxylin-eosin, oil immersion, $\times 100$).

DISCUSSION

The differential diagnosis of bilateral renal masses includes both primary and metastatic tumors. Of the primary tumors, renal cell carcinoma is the most common in adults, yet only about 1% of these tumors are bilateral.² Oncocytomas and angiomyolipomas are bilateral in 3% and 15% of cases, respectively.^{3,4} An angiomyolipoma is a benign hamartomatous mass composed of blood vessels, smooth muscle, and fat. Formerly thought to be rare, its incidence is increasing due to improved detection of its fat content by CT, ultrasound, and magnetic resonance imaging (MRI).

Lymphoma in the kidneys and retroperitoneum is usually a result of generalized disease. Up to 40% of patients with lymphoma have renal involvement demonstrable at autopsy and up to 14% have documented antemortem renal involvement.⁵ The kidneys lack lymphoid tissue, and although primary renal lymphoma has been reported,⁵⁻⁷ most renal lymphomas are thought to occur either by direct extension from the retroperitoneum or by hematogenous spread.⁸ In either event, the growth is presumed to be initially interstitial, among the blood vessels and nephrons. Despite the frequency of renal involvement, lymphoma is only rarely a cause of renal failure.⁹⁻¹¹

Other tumors metastatic to the kidneys are infrequent antemortem findings, yet 50% of them are bilateral. Melanoma and tumors of the lung, colon, and contralateral kidney are those most frequently metastatic to the kidneys and their clinical presentation of

hematuria, pyrexia, and a palpable mass is similar to that of renal cell carcinoma.¹²

Bilateral renal tumors can be due to benign or malignant renal tumors, primary or secondary lymphoma, or other metastatic tumors. In this case of large cell lymphoma presenting as a bilateral renal mass, no other foci of lymphomatous involvement could be documented, even with sensitive imaging techniques. However, an autopsy was not performed, and the possibility that the renal involvement was metastatic cannot be excluded.

A variety of imaging modalities are utilized in the evaluation of suspected renal mass lesions. Intravenous pyelography (IVP), retrograde pyelography, ultrasonography, CT, and MRI may be used for the detection and localization of renal masses. IVP remains the initial screening examination. If a mass is detected, ultrasonography will enable the differentiation of a benign simple cyst from a complicated or solid lesion. If ultrasonography demonstrates a complex cyst or solid mass, CT should be performed to document the presence, nature, and anatomical extent of the lesion. MRI may compliment CT by further defining the margins of the tumor and invasion of surrounding structures. In addition, MRI is helpful in detecting and determining the extent of renal vein and inferior vena cava tumor thrombus.¹³ Selective renal arteriography and inferior venacavography are useful for presurgical planning, especially when segmental nephrectomy is considered. In this particular case, bilateral renal masses were clinically unsuspected and were discovered by the CT obtained during the diagnostic studies.

As CT has become essential in the staging of lymphoma, renal involvement at an early stage is more frequently detected. In a recently published series, 33 of 399 (8.3%) patients with malignant lymphoma had renal involvement (all non-Hodgkins lymphoma, except one case).⁸ In 29 of these patients who had undergone CT evaluation, four patterns of renal or perinephric lymphoma were identified. Multiple renal masses were demonstrated in 17 patients, with 15 of these patients having bilateral masses. Seven of the 17 patients with multiple renal masses also had retroperitoneal lymphadenopathy. Other less common patterns of renal or perinephric involvement included invasion of contiguous retroperitoneal masses,

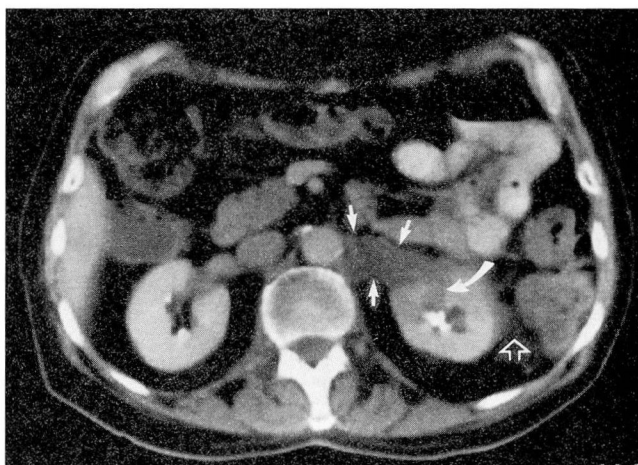


FIGURE 5. Contrast-enhanced CT scan through the upper kidneys (same level as in *Figure 1*) obtained after 1 month of treatment demonstrates small residual low attenuation masses in the left periaortic region (solid arrows) and in the anterior aspect of the left kidney (curved arrows). A residual tumor is also present in the left perinephric space immediately adjacent to the left kidney (open arrow). Note that the kidneys have returned to their normal configuration.

perinephric masses, and a single renal mass. Another study has noted renal sinus involvement with or without parenchymal invasion which may surround and compress the renal pelvis.¹⁴ On non-enhanced CT scans, lymphomatous lesions have the same attenuation as normal renal parenchyma. Following contrast administration, the lesions are lower in attenuation than the normal enhancing parenchyma. Ultrasonography demonstrates the lymphomatous mass to be generally hypoechoic or anechoic compared with the normal renal parenchyma.¹⁴ The angiographic findings of renal lymphoma include a hypovascular mass or masses with fine neovascularity, smooth and diffuse arterial encasement, and faint tumor staining.¹⁵

Although non-specific, certain radiologic characteristics of renal lymphoma should make the radiologist and clinician suspicious of this diagnosis. Needle biopsy with ultrasound or CT guidance may be useful in obtaining a tissue diagnosis before an unnecessary nephrectomy is performed, since lymphoma is often effectively treated by radiation therapy and/or chemotherapy, as dramatically demonstrated in this patient.

REFERENCES

1. Wick MR, Cherwitz DL, Manivel JC, Sibley R. Immunohistochemical findings in tumors of the kidney. In: Eble JN, ed. *Tumors and*

tumor-like conditions of the kidneys and ureters. New York: Churchill Livingstone, 1990:207-247.

2. Rosai J. *Ackerman's surgical pathology*. St. Louis: The CV Mosby Co., 1989:869.

3. Davis CJ Jr, Sesterhenn IA, Mostofi FK, Ho CK. Renal oncocytoma clinicopathological study of 166 patients. *Journal of Urogenital Pathology* 1991; **1**:41-52.
4. Farrow GM, Harrison Jr EG, Utz DC, Jones DR. Renal angiomyolipoma. A clinicopathologic study of 32 cases. *Cancer*. 1986; **22**:564-570.
5. Osborne BM, Brenner M, Weitzner S, Butler JJ. Malignant lymphoma presenting as a renal mass: four cases. *Am J Surg Pathol* 1987; **11**:375-382.
6. Kandel LB, McCullough DL, Harrison LH, Woodruff RD, Ahl ET, Munitz HA. Primary renal lymphoma. Does it exist? *Cancer* 1987; **60**:386-391.
7. Bennington JL, Beckwith JB. Tumors of the kidney, renal pelvis, and ureter. Washington, D.C.: The Armed Forces Institute of Pathology, 1975.
8. Cohan RH, Dunnick NR, Leder RA, Baker ME. Computed tomography of renal lymphoma. *J Comput Assist Tomogr* 1990; **14**:933-938.
9. Randolph VL, Hall W, Bramson W. Renal failure due to lymphomatous infiltration of the kidneys. *Cancer* 1983; **52**:1120-1121.
10. Ellman L, Davis J, Lichtenstein NS. Uremia due to occult lymphomatous infiltration of the kidneys. *Cancer* 1974; **33**:203-205.
11. Martinez-Maldonado M, DeArellano GAR. Renal involvement in malignant lymphomas: a survey of 49 cases. *J Urol* 1966; **95**:485-488.
12. Sternberg SS. *Diagnostic surgical pathology*. New York: Raven Press, 1989:1323.
13. McClennan BL, Rabin DN. Kidney. In: Lee JKT, Segal SS, Stanley RJ, eds. *Computed body tomography with MRI correlation*. New York: Raven Press, 1989.
14. Charnsangavej C. Lymphoma of the genitourinary tract. *Radiol Clin North Am* 1990; **28**:865-877.
15. Jafri SZ, Amendola MA, Brady TM, et al. Angiographic patterns of involvement in renal and perirenal lymphoma. *Urol Radiol* 1984; **6**(1):14-19.

