

**JAMAK MODARESI ESFEH, MD**  
Department of Internal Medicine,  
Cleveland Clinic

**IBRAHIM A. HANOUNEH, MD**  
Department of Gastroenterology  
and Hepatology, Cleveland Clinic

**NIZAR N. ZEIN, MD**  
Mikati Foundation Endowed Chair in Liver  
Diseases, Chief, Section of Hepatology, and  
Medical Director of Liver Transplantation  
Department of Gastroenterology and Hepatology,  
Cleveland Clinic

# A 25-year-old man with very high alkaline phosphatase

A 25-YEAR-OLD man presented to his primary care physician with generalized malaise. His symptoms started around 2 months earlier with progressive fatigue, nausea, decreased appetite, and weight loss (15 lb in 2 months). He denied having fever, chills, night sweats, abdominal pain, diarrhea, melena, or hematochezia.

His medical history was remarkable only for depression, well controlled with sertraline (Zoloft), which he started taking 3 years ago. He was not taking any other prescribed, over-the-counter, or herbal medications.

He had no family history of cancer or liver disease. He did not smoke and rarely drank alcohol. He had never used recreational drugs. He was sexually active with one female partner, used condoms for protection, and had never been diagnosed with a sexually transmitted disease. He had not traveled recently and had not been exposed to any pet.

On physical examination, the patient was alert and oriented. He was afebrile, his heart rate was 90 beats per minute and regular, his respiratory rate was 18 breaths per minute, and his blood pressure was 125/77 mm Hg. Auscultation of the chest was clear. His heart sounds were normal, and there was no murmur, gallop, or rub. His right upper quadrant was mildly tender, and his liver was palpably enlarged. He had no peripheral edema, clubbing, rash, telangiectasia, or other skin changes. Examination of the joints revealed no warmth, swelling, or erythema.

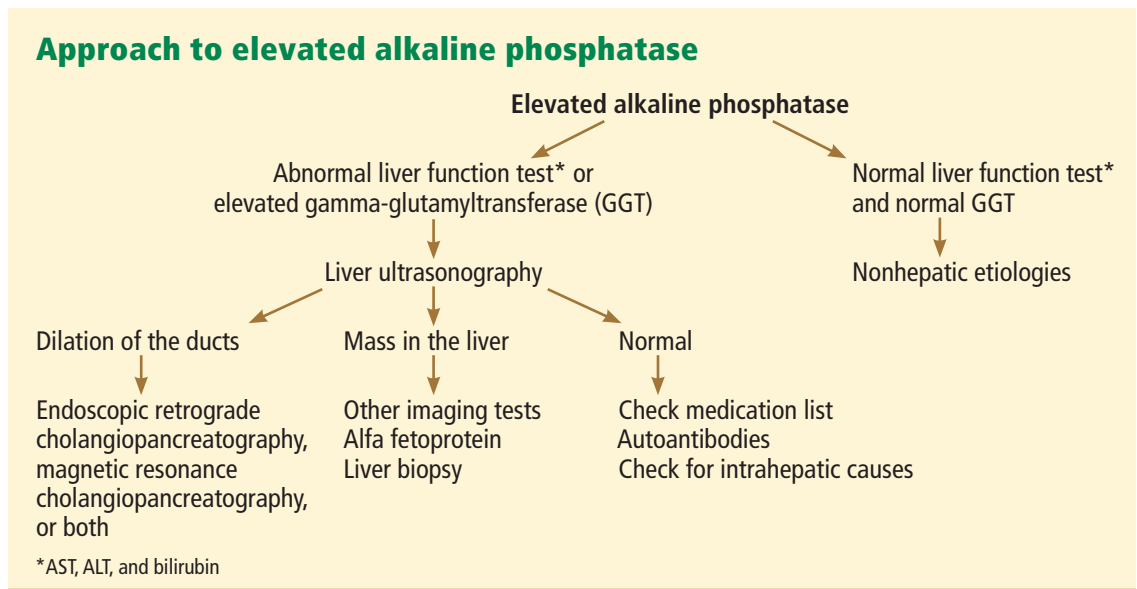
The patient's laboratory values on admission are shown in TABLE 1. Of note, his serum alkaline phosphatase level was 1,307 U/L (reference range 40–150 U/L).

TABLE 1

## The patient's laboratory values on admission

TEST	RESULTS	NORMAL RANGE
Sodium	142 mmol/L	132–148
Potassium	3.8 mmol/L	3.5–5.0
Chloride	109 mmol/L	98–111
Bicarbonate	19 mmol/L	23–32
Blood urea nitrogen	21 mg/dL	8–25
Creatinine	0.8 mg/dL	0.7–1.4
Glucose	87 mg/dL	65–100
Hemoglobin	14.1 g/dL	12–16
Hematocrit	55.5%	39–51
White blood cell count	19.5 × 10 <sup>9</sup> /L	4–11
Platelet count	316 × 10 <sup>9</sup> /L	150–400
Alanine aminotransferase	46 U/L	5–45
Aspartate aminotransferase	123 U/L	7–40
Alkaline phosphatase	1,307 U/L	40–150
Gamma-glutamyltransferase	110 U/L	0–51
Bilirubin, total	2.0 mg/dL	0–1.5
Albumin	3.3 g/dL	3.5–5
Activated partial thromboplastin time	27.1 seconds	24.6–34.0
Prothrombin time	10.1 seconds	9.9–13
International normalized ratio	0.9	0.9–1.1

doi:10.3949/ccjm.78a.10166



**FIGURE 1**

**LIVER TESTS CAN NARROW THE DIAGNOSIS**

The most commonly used laboratory tests of the liver can be classified into those that measure either:

- Liver synthetic function (eg, the serum albumin and bilirubin concentrations and the prothrombin time) or
- Liver damage, as reflected by the serum concentrations of the enzymes alanine aminotransferase (ALT), aspartate aminotransferase (AST), alkaline phosphatase, and gamma-glutamyltransferase (GGT).<sup>1,2</sup>

ALT and AST are normally concentrated in the hepatocytes and thus, when present in the serum in elevated concentrations, are markers of liver cell injury. The serum levels of these enzymes start to increase within a few hours of liver cell injury as they leak out of the cells via the damaged cell membrane. AST is less liver-specific than ALT, since AST levels can be elevated not only in liver injury but also in muscle, cardiac, and red blood cell injury.<sup>3,4</sup>

Alkaline phosphatase is actually a heterogeneous group of enzymes found mainly in liver and bone cells. Hepatic alkaline phosphatase is concentrated near the biliary canicular membrane of the hepatocyte. Accordingly, increased levels of hepatic alkaline phosphatase are mainly seen in liver diseases that predominantly affect the biliary system.<sup>3</sup>

GGT is also concentrated in hepatic biliary epithelial cells, and thus GGT elevation is another marker of hepatobiliary disease. In fact, measuring the GGT level can help to determine whether an isolated elevation of alkaline phosphatase is due to liver injury.<sup>2,3</sup>

Accordingly, liver diseases can be classified into two broad categories:

- Hepatocellular injury, in which the primary injury occurs to the hepatocytes
- Cholestatic injury, in which the primary injury is to the bile ducts.

In the former, elevated levels of ALT and AST predominate, while in the latter, elevated alkaline phosphatase is the main finding.<sup>3</sup>

**WHAT TEST NEXT FOR OUR PATIENT?**

**1** What is the next most appropriate diagnostic step for our patient?

- Liver biopsy
- Ultrasonography of the liver
- Computed tomography (CT) of the liver
- Observation

Our patient has an elevated GGT level, which suggests that his elevated alkaline phosphatase is of hepatic rather than bony origin. Moreover, a serum alkaline phosphatase level that is elevated out of proportion to the aminotransferase levels reflects cholestatic liver injury.

**AST is less liver-specific than ALT**

**TABLE 2**

**Common causes of cholestatic liver disease**

CAUSE	CLINICAL CLUES	DIAGNOSTIC TESTS
<b>Primary sclerosing cholangitis</b>	More common in males, young age, association with ulcerative colitis	Endoscopic retrograde cholangiopancreatography (ERCP) Magnetic resonance cholangiopancreatography (MRCP)
<b>Primary biliary cirrhosis</b>	More common in women, middle age, history of pruritus and fatigue	Antinuclear antibodies Antimitochondrial antibodies
<b>Biliary obstruction</b>	Jaundice, abdominal pain	Ultrasonography, ERCP, MRCP
<b>Infiltrative diseases</b> Amyloidosis, sarcoidosis, lymphoma	History of amyloidosis, sarcoidosis, malignancy	Ultrasonography, computed tomography
<b>Medication-induced</b>	Medication history and timing	Discontinuation of the medication
<b>Outflow obstruction</b> Congestive heart failure Budd-Chiari syndrome	Dyspnea, edema, jaundice, abdominal pain, ascites	Echocardiography, ultrasonography, computed tomography, magnetic resonance imaging

**ALT and AST are higher in hepatocellular injury; alkaline phosphatase is higher in cholestatic injury**

Cholestatic liver diseases can be classified into two broad categories based on whether the injury affects the microscopic intrahepatic bile ducts (intrahepatic cholestasis) or extrahepatic large bile duct (extrahepatic cholestasis). The simplest diagnostic test to differentiate between the two is ultrasonography, which can identify extrahepatic biliary obstruction fairly well. Therefore, the diagnostic workup of cholestatic liver injury should start with ultrasonography of the liver to differentiate between intrahepatic and extrahepatic processes (FIGURE 1).

**■ CASE CONTINUED:  
ULTRASONOGRAPHY IS MOSTLY NORMAL**

Ultrasonography of the right upper quadrant revealed that the liver had normal echogenicity and was mildly enlarged. There was no focal hepatic lesion. The gallbladder appeared normal, with no stones or sludge. No dilated intrahepatic or extrahepatic biliary ducts were seen. The common bile duct measured 4 mm. A small amount of ascites not amenable to paracentesis was present.

Thus, in the absence of biliary dilation on ultrasonography, we are dealing with an intrahepatic cholestatic process.

**■ CAUSES OF CHOLESTATIC LIVER DISEASE**

TABLE 2 lists the common causes of cholestatic liver disease.

**Viral hepatitis**

Viral hepatitis most often produces a hepatocellular pattern of injury (ie, AST and ALT elevations predominate). However, in rare cases it can cause a cholestatic pattern of injury.

Our patient subsequently had serologic tests for viral hepatitis, including hepatitis A, B, and C, and the results were negative.

**Autoimmune liver disease**

The three most common forms of autoimmune liver disease are autoimmune hepatitis, primary biliary cirrhosis, and primary sclerosing cholangitis.

**Autoimmune hepatitis** is characterized by high serum ALT and AST levels, whereas primary biliary cirrhosis and primary sclerosing cholangitis are associated with predominant elevations of alkaline phosphatase, since they are cholestatic disorders.

Our patient's alkaline phosphatase level was much higher than his ALT and AST levels, making the latter two diseases more likely.

**Primary biliary cirrhosis** (and autoim-

mune hepatitis) are associated with auto-antibodies in the serum, such as antinuclear antibody, smooth muscle antibody, and anti-mitochondrial antibody.

Our patient subsequently was tested for these antibodies, and the results were negative.

**Primary sclerosing cholangitis** usually affects the extrahepatic biliary system. Thus, if it is present, abnormalities should be seen on imaging.

As mentioned previously, no dilated intrahepatic or extrahepatic biliary ducts were seen on ultrasonography in our patient. Moreover, primary sclerosing cholangitis is associated with inflammatory bowel disease, particularly ulcerative colitis, which our patient did not have.

**Drug-induced liver injury**

Drug-induced liver injury is a common cause of cholestatic liver disease. However, our patient was not taking any prescribed, over-the-counter, or herbal medications. Additionally, he denied heavy alcohol use.

**Infiltrative disorders**

Infiltrative disorders such as amyloidosis, sarcoidosis, or lymphoma should be considered in the differential diagnosis of cholestatic liver disease. A clue to a possible infiltrative process is a markedly elevated level of alkaline phosphatase with a mildly increased serum bilirubin concentration, both of which our patient had.

**AFTER ULTRASONOGRAPHY, WHAT IS THE NEXT STEP?**

**2** Which of the following is the next most appropriate diagnostic test for our patient?

- Endoscopic retrograde cholangiopancreatography (ERCP)
- Magnetic resonance cholangiopancreatography (MRCP)
- Liver biopsy
- CT of the abdomen

**FIGURE 1** shows a proposed algorithm for evaluating increased alkaline phosphatase levels.

If there is no biliary duct dilation on ultrasonography, then abnormal levels of alkaline

phosphatase most likely represent an intrahepatic pattern of cholestatic liver injury. Therefore, additional imaging with CT or magnetic resonance imaging is of limited diagnostic value. ERCP is used today for therapy rather than diagnosis, so its use is limited to patients known to have dilated biliary ducts on imaging. Liver biopsy, however, can provide useful findings.

**Case continued: He undergoes biopsy**

Our patient underwent transjugular liver biopsy. During the procedure, transjugular venography showed stenosis in the right, middle, and left hepatic veins and the hepatic portion of the inferior vena cava, consistent with Budd-Chiari syndrome.

The liver biopsy specimen was positive for extensive deposition of slight eosinophilic and amorphous material in a sinusoidal pattern in the liver parenchyma, as well as in the portal tracts, with markedly atrophic hepatocytes. Congo red birefringence confirmed the diagnosis of amyloidosis. The immunohistochemical phenotype was positive for kappa light chains, which is diagnostic for primary-type amyloidosis, also called amyloidosis of light chain composition, or AL.

Bone marrow aspiration and bone marrow biopsy were performed and showed 22% plasma cells, well above the normal range (0–2%), consistent with the diagnosis of multiple myeloma.

**BUDD-CHIARI SYNDROME: A CHALLENGING DIAGNOSIS**

Budd-Chiari syndrome is a rare condition characterized by obstruction of venous outflow from the liver at a site that may vary from the small hepatic veins up to the inferior vena cava or even the right atrium.<sup>5,6</sup> Obstruction of hepatic venous outflow leads to sinusoidal congestion and hypoxic damage of the hepatocytes.<sup>7</sup> Hypoxia and necrosis of the hepatocytes result in the release of free radicals. Cirrhosis can eventually occur secondary to ischemic necrosis of hepatocytes and hepatic fibrosis.<sup>8</sup>

The estimated incidence of this syndrome is 1 in 2.5 million persons per year.<sup>7</sup> It is more prevalent in women and young adults.<sup>8</sup>

**ERCP is now used for therapy rather than diagnosis**

TABLE 3

## Some of the major causes of Budd-Chiari syndrome

CAUSE	CLINICAL CLUES
<b>Myeloproliferative disorders</b> Polycythemia vera Essential thrombocytemia Primary myelofibrosis Chronic myelogenous leukemia	Increased hematocrit and hemoglobin with normal oxygen saturation Increased number of platelets Pancytopenia, teardrop red blood cells Leukocytosis, Philadelphia chromosome
<b>Paroxysmal nocturnal hemoglobinuria</b>	Hemolysis, hematuria
<b>Hereditary coagulopathy</b> Factor V Leiden mutation Protein C or S deficiency Antithrombin III deficiency	Family history History of venous thrombosis
<b>Malignancy</b> Hepatocellular carcinoma Multiple myeloma Metastasis	
<b>Connective tissue disorders</b> Behçet disease Antiphospholipid antibody syndrome	Recurrent oral aphthous ulceration, recurrent genital ulcers History of venous or arterial thrombosis
<b>Medications</b> Oral contraceptives	
<b>Nephrotic syndrome</b>	Proteinuria, edema, hyperlipidemia

**Budd-Chiari syndrome is due to venous thrombosis obstructing hepatic outflow**

### Heterogeneous in its causes and manifestations

In about 75% of patients with Budd-Chiari syndrome, a hereditary or acquired hematologic abnormality or thrombotic diathesis can be found.<sup>8-10</sup> Some of the major causes are summarized in **TABLE 3**. The most common causes are hematologic diseases, especially myeloproliferative disorders.<sup>7,8,11</sup>

Budd-Chiari syndrome is also heterogeneous in its manifestations, which depend on the extent of the occlusion, on the acuteness of the obstruction, and on whether venous collateral circulation has developed to decompress the liver sinusoids.<sup>9,12,13</sup> Therefore, on the basis of its clinical manifestations, it can be classified as fulminant, acute, subacute, or chronic.<sup>12-16</sup>

The fulminant form presents with hepatic encephalopathy within 8 weeks after the development of jaundice. The subacute form, which is the most common, has a more insidious onset in which hepatic sinusoids are

decompressed by portal and hepatic venous collateral circulation. The patient usually presents with abdominal pain, ascites, hepatomegaly, nausea, vomiting, and mild jaundice. Finally the chronic form presents as complications of cirrhosis.<sup>12-16</sup>

### Imaging plays an important role in diagnosing Budd-Chiari syndrome

Imaging plays an important role in detecting and classifying Budd-Chiari syndrome.

Duplex ultrasonography is useful for detecting this syndrome and has a sensitivity and specificity of 85%.<sup>9</sup>

CT and magnetic resonance imaging can also help in the diagnosis by showing thrombosis, obstruction, or occlusion in the hepatic vein or the inferior vena cava.<sup>5</sup>

Venography is the gold standard for diagnosis. However, it should be performed only if noninvasive tests are negative or nondiagnostic and there is a high clinical suspicion

of this disease.<sup>17</sup> Budd-Chiari syndrome has a characteristic pattern on venography known as “spider web,” which is due to the formation of venous collaterals to bypass the occluded hepatic veins.<sup>9</sup>

Liver biopsy is not necessarily required to confirm the diagnosis of Budd-Chiari syndrome, but it can help in diagnosing the acute or subacute forms and also in ruling out other causes. Histologic findings can include centrilobular congestion, loss of hepatocytes, hemorrhage, and fibrosis.<sup>18,19</sup> Regenerative nodules are found in about 25% of patients.<sup>19</sup>

■ **TREATING BUDD-CHIARI SYNDROME**

The primary goal of treatment is to prevent further extension of the venous thrombosis in the hepatic veins, in their collaterals, and in the intrahepatic and extrahepatic portal venous system. Resolution of hepatic congestion improves liver perfusion and preserves function of the hepatocytes.

Anticoagulation is recommended in the early stages. Heparin therapy should be initiated and subsequently switched to warfarin with the goal of achieving an international normalized ratio of the prothrombin time of 2.0 to 2.5.<sup>8,9,19</sup>

Thrombolysis is effective in the acute form.<sup>20,21</sup> Recanalization, including percutaneous or transhepatic angioplasty of localized segments of the narrowed hepatic veins or inferior vena cava, has long-term patency rates of 80% to 90%.<sup>22</sup>

If thrombolytic therapy and angioplasty are unsuccessful, a transjugular intrahepatic

portosystemic shunt or a surgical procedure (side-to-side portocaval shunt, central spleno-renal shunt, or mesocaval shunt) should be considered.<sup>9</sup>

Liver transplantation is another treatment option in those with fulminant Budd-Chiari syndrome or advanced liver cirrhosis.<sup>8</sup>

■ **PROGNOSIS HAS IMPROVED**

The prognosis of Budd-Chiari syndrome has improved, thanks to both earlier diagnosis and new treatments. The 1-year survival rate, which was about 60% before 1985, has increased to more than 80% in recent cohort studies.<sup>19</sup>

Studies have shown that the Child-Pugh score, which is based on a combination of serum albumin, bilirubin, prothrombin time, encephalopathy, and ascites, can be considered as an independent prognostic factor. A lower Child-Pugh score and a younger age are associated with a good prognosis.<sup>19,23,24</sup> (The Child-Pugh score cannot be applied to our patient because he does not have cirrhosis.)

**What happened to our patient?**

Our patient was started on anticoagulation for his Budd-Chiari syndrome and on bortezomib (Velcade) and dexamethasone for his multiple myeloma. He achieved remarkable improvement in his liver function tests. Follow-up duplex ultrasonography 1 month after discharge revealed that the stenosis in the hepatic veins had resolved. He is following up with the oncology clinic for management of his multiple myeloma.

**Treatments for Budd-Chiari syndrome: anticoagulation, thrombolysis, angioplasty, shunt, liver transplantation**

■ **REFERENCES**

1. **Folwaczny C.** Efficient diagnostics for elevated transaminases. [Article in German] *MMW Fortschr Med* 2007; 149:44–48.
2. **Moussavian SN, Becker RC, Piepmeyer JL, Mezey E, Bozian RC.** Serum gamma-glutamyl transpeptidase and chronic alcoholism. Influence of alcohol ingestion and liver disease. *Dig Dis Sci* 1985; 30:211–214.
3. **Aragon G, Younossi ZM.** When and how to evaluate mildly elevated liver enzymes in apparently healthy patients. *Cleve Clin J Med* 2010; 77:195–204.
4. **Lepper PM, Dufour JF.** Elevated transaminases—what to do if everything was done?. [Article in German] *Praxis (Bern 1994)* 2009; 98:330–334.
5. **Buzas C, Sparchez Z, Cucuianu A, Manole S, Lupescu I, Acalovschi M.** Budd-Chiari syndrome secondary to polycythemia vera. A case report. *J Gastrointest Liver Dis* 2009; 18:363–366.
6. **Valla DC.** Primary Budd-Chiari syndrome. *J Hepatol* 2009; 50:195–203.
7. **Rautou PE, Moucari R, Cazals-Hatem D, et al.** Levels and initial course of serum alanine aminotransferase can predict outcome of patients with Budd-Chiari syndrome. *Clin Gastroenterol Hepatol* 2009; 7:1230–1235.
8. **Curra M, Haskal Z, Lopera J.** Diagnostic and interventional radiology for Budd-Chiari syndrome. *Radiographics* 2009; 29:669–681.
9. **Menon KV, Shah V, Kamath PS.** The Budd-Chiari syndrome. *N Engl J Med* 2004; 350:578–585.
10. **Darwish Murad S, Plessier A, Hernandez-Guerra M, et al; EN-Vie (European Network for Vascular Disorders of the Liver).** Etiology, management, and outcome of the Budd-Chiari syndrome. *Ann Intern Med* 2009; 151:167–175.
11. **Valla D, Le MG, Poynard T, Zucman N, Rueff B, Benhamou JP.** Risk of hepatic vein thrombosis in relation to



- recent use of oral contraceptives. A case-control study. *Gastroenterology* 1986; 90:807–811.
12. **Bismuth H, Sherlock DJ.** Portasystemic shunting versus liver transplantation for the Budd-Chiari syndrome. *Ann Surg* 1991; 214:581–589.
  13. **Orloff MJ, Daily PO, Orloff SL, Girard B, Orloff MS.** A 27-year experience with surgical treatment of Budd-Chiari syndrome. *Ann Surg* 2000; 232:340–352.
  14. **Dilawari JB, Bamberg P, Chawla Y, et al.** Hepatic outflow obstruction (Budd-Chiari syndrome). Experience with 177 patients and a review of the literature. *Medicine (Baltimore)* 1994; 73:21–36.
  15. **Mahmoud AE, Mendoza A, Meshikhes AN, et al.** Clinical spectrum, investigations and treatment of Budd-Chiari syndrome. *QJM* 1996; 89:37–43.
  16. **Klein AS, Cameron JL.** Diagnosis and management of the Budd-Chiari syndrome. *Am J Surg* 1990; 160:128–133.
  17. **Plessier A, Valla DC.** Budd-Chiari syndrome. *Semin Liver Dis* 2008; 28:259–269.
  18. **Cazals-Hatem D, Vilgrain V, Genin P, et al.** Arterial and portal circulation and parenchymal changes in Budd-Chiari syndrome: a study in 17 explanted livers. *Hepatology* 2003; 37:510–519.
  19. **Hoekstra J, Janssen HL.** Vascular liver disorders (I): diagnosis, treatment and prognosis of Budd-Chiari syndrome. *Neth J Med* 2008; 66:334–359.
  20. **Frank JW, Kamath PS, Stanson AW.** Budd-Chiari syndrome: early intervention with angioplasty and thrombolytic therapy. *Mayo Clin Proc* 1994; 69:877–881.
  21. **Raju GS, Felver M, Olin JW, Satti SD.** Thrombolysis for acute Budd-Chiari syndrome: case report and literature review. *Am J Gastroenterol* 1996; 91:1262–1263.
  22. **Fisher NC, McCafferty I, Dolapci M, et al.** Managing Budd-Chiari syndrome: a retrospective review of percutaneous hepatic vein angioplasty and surgical shunting. *Gut* 1999; 44:568–574.
  23. **Zeitoun G, Escolano S, Hadengue A, et al.** Outcome of Budd-Chiari syndrome: a multivariate analysis of factors related to survival including surgical portosystemic shunting. *Hepatology* 1999; 30:84–89.
  24. **Darwish Murad S, Valla DC, de Groen PC, et al.** Determinants of survival and the effect of portosystemic shunting in patients with Budd-Chiari syndrome. *Hepatology* 2004; 39:500–508.
- .....
- ADDRESS:** Nizar N. Zein, MD, Section of Hepatology, A51, Cleveland Clinic, 9500 Euclid Avenue, Cleveland, OH 44195; e-mail zeinn@ccf.org.



## 24th Annual Intensive Review of Internal Medicine

June 3 – 8, 2012

InterContinental Hotel &  
Bank of America Conference Center  
Cleveland, OH

This activity has been approved for  
AMA PRA Category 1 Credit™.

For complete program &  
registration information, go to:

[www.ccfme.org/IRIM](http://www.ccfme.org/IRIM)

### Board Oriented

- Certification
- Recertification
- Case-Driven Format
- Board-Simulation Sessions
- Interactive Audience Response System

### Offering ABIM Maintenance of Certification Learning Session

June 9, 2012  
7:00 am – 12:00 pm

- 2011 Update in Internal Medicine
- 2011 Update in Hospital Medicine  
(Preparation for Recognition of Focused Practice)

